

## Thyroid eye disease

Petros Perros,<sup>1</sup> Christopher Neoh,<sup>2</sup> Jane Dickinson<sup>2</sup>

<sup>1</sup>Department of Endocrinology, Royal Victoria Infirmary, Newcastle upon Tyne NE1 4LP

<sup>2</sup>Department of Ophthalmology, Royal Victoria Infirmary, Newcastle upon Tyne NE1 4LP

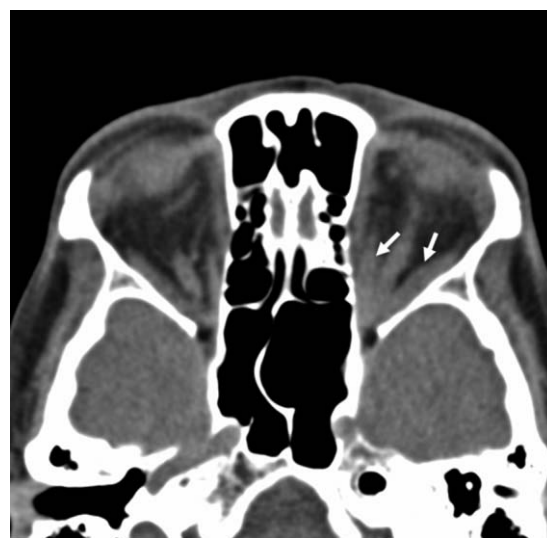Correspondence to: P Perros [petros.perros@ncl.ac.uk](mailto:petros.perros@ncl.ac.uk)

Cite this as: *BMJ* 2009;338:b560  
doi:10.1136/bmj.b560

Thyroid eye disease is a relatively rare condition, with an incidence of 2.9 to 16.0 cases per 100 000 population per year.<sup>1</sup> The disease mainly affects women. Many patients experience distressing symptoms, and a few develop sight threatening complications. Patients are often young or middle aged and at the peak of their career. Most patients are very aware of their altered appearance. Sight loss can be prevented by appropriate management, yet it still occurs even in countries with advanced healthcare systems. This problem is largely due to delays in starting treatment, because health professionals are not always aware of the remarkable difference that treatment can make in restoring visual function and appearance.<sup>2</sup> For example, treatment can reverse blindness and help a reclusive patient to become socially reintegrated. Referral to specialist centres is appropriate for all but the mildest cases.<sup>3</sup>

### What causes thyroid eye disease?

Thyroid eye disease is an autoimmune disorder, with associated thyroid autoimmunity always discernible.<sup>4</sup> The presence of one or more shared autoantigens between the thyroid and the orbit may explain why retro-orbital tissues are affected.<sup>5,6</sup> Extraocular muscles and retro-ocular connective tissue are infiltrated by lymphocytes, leading to activation of cytokine networks and inflammation and interstitial oedema of the extraocular muscles.<sup>7,8</sup> Excess secretion of glycosaminoglycans by orbital fibroblasts seems to be an important contributor. The end result is expansion of the volume of extraocular muscles, retro-orbital fat, and connective tissue. Similar changes affect the eyelids and anterior periorbital tissues. Smoking



**Fig 1** | Computed tomography/magnetic resonance imaging of the orbits showing typical features of thyroid eye disease. Medial and inferior recti are enlarged (arrows). Even patients with clinically unilateral disease are usually found to have bilateral enlargement of muscles on imaging

increases the risk of developing thyroid eye disease by seven to eight fold.<sup>9</sup>

Apart from visible swelling and redness of the eyelids and conjunctiva, the other clinical features of thyroid eye disease can also be accounted for by the expansion of inflammatory soft tissue within the constraints of the rigid bony orbit. Anterior displacement of the globe by the oedematous extraocular muscles and orbital fibrofatty tissues results in exophthalmos and lower lid retraction. These symptoms in turn may lead to impaired lid closure and corneal ulceration, especially if the levator muscle is also infiltrated and its excursion restricted. Oedematous extraocular muscles lose compliance, restrict eye movements, and can compress the optic nerve at the orbital apex (fig 1).

### How do patients with thyroid eye disease present?

Most patients present with concurrent thyrotoxicosis due to Graves' disease. The classic presentation is with thyrotoxicosis, diffuse goitre, and exophthalmos. About 10-20% of patients develop eye problems in the months before becoming thyrotoxic; about 10-15% present with current or previous hypothyroidism.<sup>10,11</sup>

#### Box 1 Atypical eye features requiring confirmation of the diagnosis of thyroid eye disease by orbital imaging (CT or MRI)

- Unilateral disease
- Unilateral or bilateral disease in patients with no previous or present evidence of thyroid dysfunction
- Absence of upper eyelid retraction
- Divergent strabismus
- Diplopia sole manifestation
- History of diplopia worsening towards the end of the day

**Sources and selection criteria**

This review is based on Medline searches, recent consensus statements by the European Group on Graves' Orbitopathy (EUGOGO, [www.eugogo.org](http://www.eugogo.org), of which the authors are members), and the authors' personal experience in the field. Randomised controlled trials are scarce, but are referred to where applicable. Most of the available evidence is observational, based on case controlled studies or expert opinion.

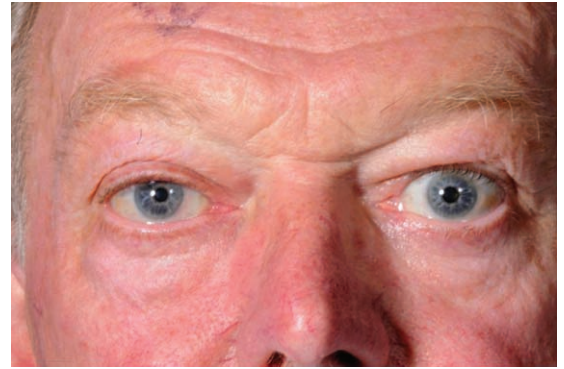Occasionally thyroid eye disease precedes thyroid dysfunction by several years.

Common early symptoms include altered periocular appearance, symptoms related to the eye surface (grittiness, photophobia, and excessive lacrimation), double vision, especially at the extremes of gaze, and retro-orbital ache. Blurred vision is common and is usually caused by refractive problems, abnormalities of the tear film, or subtle imbalances in eye movements. However, blurred vision that does not improve with blinking, refraction, or pinhole, or by occluding either eye may be due to optic nerve compression. Exophthalmos is not always present in this sight threatening situation and does not correlate well with disease severity. Indeed, some patients with minimal exophthalmos are at high risk of optic nerve compression, because they have not undergone "self decompression" by displacement of the eyes forwards as the retro-ocular tissues have expanded, so their intraorbital pressure may be very high (fig 2). In our experience thyroid eye disease is often misdiagnosed as allergic conjunctivitis when periorbital swelling and conjunctival redness are the predominant features. In such cases the presence of eyelid retraction and restricted eye movements helps to differentiate thyroid eye disease from these other causes of periorbital oedema. Thyroid eye disease should be considered in patients with a background of autoimmune thyroid disease presenting with blurred vision or conjunctivitis.

The natural course of thyroid eye disease is described by Rundle's curve (fig 3).<sup>11</sup> The initial phase lasts a few months, during which the eye disease becomes progressively worse. The disease then reaches a peak before it begins to improve spontaneously. These changeable phases can last 1-2 years until the chronic or "burnt-out" stage, when further change is highly unlikely.

**Box 2 Other ophthalmological conditions that can be misdiagnosed as thyroid eye disease**

Allergic conjunctivitis  
Myasthenia gravis  
Orbital myositis  
Chronic progressive external ophthalmoplegia  
Orbital tumours (primary or secondary)  
Carotid-cavernous fistula  
Any inflammatory orbitopathy (such as Wegener's granulomatosis)



**Fig 2** Patient with severe thyroid eye disease without substantial exophthalmos

Rundle's curve is a fundamental concept in understanding and managing thyroid eye disease, and it determines choice of treatment. Over the past decade, the concepts of disease severity and activity pertaining to thyroid eye disease have been defined more explicitly, although difficulties in definition and assessment remain. "Active" disease implies the presence of acute inflammatory features, relates to the early phases in Rundle's curve, and implies the potential for response to medical treatments. "Inactive" defines the phase when only surgical treatment can alter outcome.

**How is an accurate diagnosis made?**

In most cases the diagnosis of thyroid eye disease is not challenging. The presence of bilateral clinical features such as lid retraction or swelling and exophthalmos in combination with hyperthyroidism and diffuse goitre leaves little doubt. Further tests may be needed when atypical features, such as unilateral disease (fig 4), are present (box 1). The presence of thyroid autoantibodies in serum increases the probability of a diagnosis of thyroid eye disease, but does not exclude other conditions. Imaging of the orbits by computed tomography or magnetic resonance imaging is the most valuable diagnostic test (fig 1). Typically multiple muscles are enlarged in both orbits. Other conditions that can be confused with thyroid eye disease are shown in box 2.

**How is the disease managed?**

Once the diagnosis of thyroid eye disease is made, initial management consists of three steps, in this order of priority:

- Ensuring that the patient has neither of the sight threatening eye complications: corneal ulceration or optic neuropathy (box 3).
- Avoiding factors that exacerbate thyroid eye disease by introducing smoking cessation strategies (if the patient is a smoker), correcting thyroid dysfunction, and protecting the corneas with lubricants.
- Referring suitable patients to specialist centres.

### Which patients should be referred to specialists?

Clinicians should do a basic assessment of disease severity and activity, which will guide further management. Box 3 summarises the European Group on Graves' Orbitopathy (EUGOGO) tool for referral criteria by generalists to specialist centres.<sup>12</sup>

### What can the primary care physician do before referral?

Thyroid function tests should be ordered. Treatment should be started as soon as possible in patients with thyrotoxicosis, in accordance with local protocols (usually anti-thyroid drugs). Hypothyroidism should be corrected with levothyroxine with the aim of

#### Box 3 Summary of EUGOGO recommendations for assessment of thyroid eye disease by non-specialists and referral criteria<sup>2</sup>

Patients with a history of Graves' disease, who have neither symptoms nor signs of thyroid eye disease, require no further ophthalmological assessments and need not be referred to a specialist. Patients with unusual presentations (such as unilateral or euthyroid thyroid eye disease) should be referred, however mild their symptoms or signs, so that an accurate diagnosis can be made. All other patients should be screened according to the protocol below.

Refer urgently if any of the following are present:

#### Symptoms

- Unexplained deterioration in vision\*
- Awareness of change in intensity or quality of colour vision in one or both eyes\*
- History of eye(s) suddenly 'popping out' (globe subluxation)

#### Signs

- Obvious corneal opacity
- Inability to close eyelids sufficiently to cover cornea
- Swollen optic disc\*

Refer non-urgently if any of the following are present:

#### Symptoms

- Abnormal light sensitivity: troublesome or deteriorating over 1-2 months
- Excessively gritty eyes, not improving after 1 week of topical lubricants
- Orbital ache or pain: troublesome or deteriorating over 1-2 months
- Altered appearance of eyes or eyelids over 1-2 months
- Patient concerned by appearance of eyes
- Double vision troublesome or deteriorating

#### Signs

- Troublesome eyelid retraction
- Abnormal swelling or redness of eyelids or conjunctivas
- Restricted eye movements
- Tilting of head (especially chin elevation) to avoid double vision

\*Signifies possible optic nerve compression.

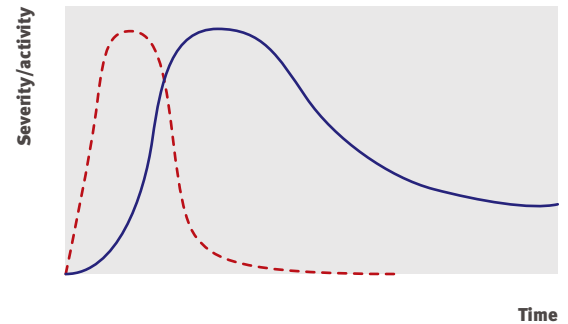


Fig 3 | Rundle's curve depicts schematically the typical course of disease severity with time (solid line). Disease activity represented by dotted line

restoring serum thyrotropin to normal. Artificial tears should be prescribed if the patient has symptoms suggesting corneal exposure, such as grittiness and light sensitivity. Smokers should be offered advice on cessation. Patients should be made aware of self help groups offering information and support.

### How should thyrotoxicosis be treated?

Uncontrolled hyperthyroidism or hypothyroidism are associated with adverse outcomes in patients with thyroid disease.<sup>11</sup> Control of thyroid dysfunction is usually followed by improvement of eye symptoms over several months. A small risk of exacerbation of eye disease has been reported in patients given radioiodine, especially in smokers and in patients who develop iatrogenic hypothyroidism after radioiodine.<sup>13</sup> Anti-thyroid drugs and thyroidectomy seem to be neutral in their effect on thyroid eye disease. Initial control with anti-thyroid drugs is the most popular means of controlling hyperthyroidism in patients with thyroid eye disease. Radioiodine can be safely administered once the eye disease is inactive,<sup>14</sup> or earlier with a short course of steroids.

### Which specific medical treatments should be considered in patients with thyroid eye disease?

The main medical treatment is steroids. Pulse therapy with intravenous methylprednisolone (initially 500-1000 mg weekly, for 10-12 weeks) is more efficacious than oral steroids and is associated with fewer side

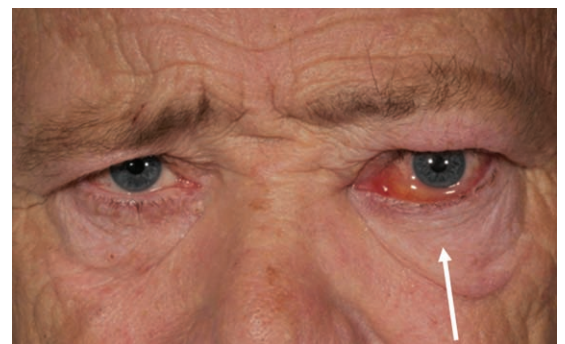


Fig 4 | Patient with unilateral thyroid eye disease (arrow)

effects.<sup>15</sup> A response to intravenous steroids is usually seen within 1-2 weeks of starting such treatment; hence, early assessment can identify non-responders, allowing rapid withdrawal of medication and thereby avoiding longer term side effects.<sup>16</sup> In our experience steroids, particularly prolonged treatment with moderate doses, are sometimes used inappropriately in this disease.

Orbital irradiation may consolidate the effects of steroids or can be used alone in patients with restricted eye movements.<sup>17</sup> Steroids and orbital irradiation are effective only in patients with active disease.

**Other non-surgical treatments**

Lubricants (artificial teardrops, especially gels and ointments such as hypromellose eye drops, vicotears gel, and lacrilube ointment) protect the corneas and offer relief for the distressing symptoms of corneal exposure. Prisms (special lenses that can be fitted on spectacles to refract light and thus achieve binocular vision when the eyes are misaligned) can be enormously helpful for patients with double vision, and may enable them to drive, work, and generally function better until the symptoms improve spontaneously or eye movements stabilise enough to allow eye muscle surgery. Some patients report that use of multiple

pillows at night or diuretics improves lid swelling, although we have never found these interventions to be useful.

**What has surgery to offer for patients with thyroid eye disease?**

Surgery has a potentially important role in all phases of the disease. In the active phase, patients with optic neuropathy who do not respond to or who cannot tolerate steroids must be considered for urgent orbital decompression. Urgent decompression may also be necessary if there is corneal ulceration associated with substantial exophthalmos.

Rehabilitative reconstructive surgery is immensely valuable for patients who feel disfigured by their disease, but is appropriate only once it has become inactive. Surgical bony decompression is highly effective in reducing exophthalmos and may be combined with fat removal. The main complication is new onset or worsened diplopia. Eye muscle surgery can usefully improve or restore binocular vision in almost 90% of patients. Eyelid surgery is undertaken to improve the position, closure, or appearance of the eyelids.<sup>18</sup> A minority of patients will need all three types of surgery, although most patients will have a good outcome from

**A PATIENT'S PERSPECTIVE**

In 1984 I got thyroid eye disease (fig 5). My general practitioner had no specialist knowledge but was understanding and keen to help; patient literature and support groups were non-existent. I didn't know what to expect or what treatment was available. Several years passed, then I was referred to an endocrinologist, and, eventually, an ophthalmologist.

I had learnt to tilt my head to cope with the double vision, wore tinted glasses, avoided eye contact and photographs, and ignored (but felt) every hurtful comment. I never had sight threatening thyroid eye disease. I just wanted to look normal again. But the chief concern of experts was how my eyes functioned, not my appearance. Only minor cosmetic operations were offered, and they had disappointing results. Living with the abnormality was distressing; there seemed to be no solution.

Orbital decompression was not a consideration until I met an ophthalmologist who listened to my concerns and did not think it strange that I was eager to pursue rehabilitative surgery. I had orbital decompression in 1998, and this was the start of feeling okay about myself. It was not easy—several operations were needed—but I got there in the end. I can't help thinking, though, that getting there should not have been such a struggle.

Janis Hickey  
 Director, British Thyroid Foundation

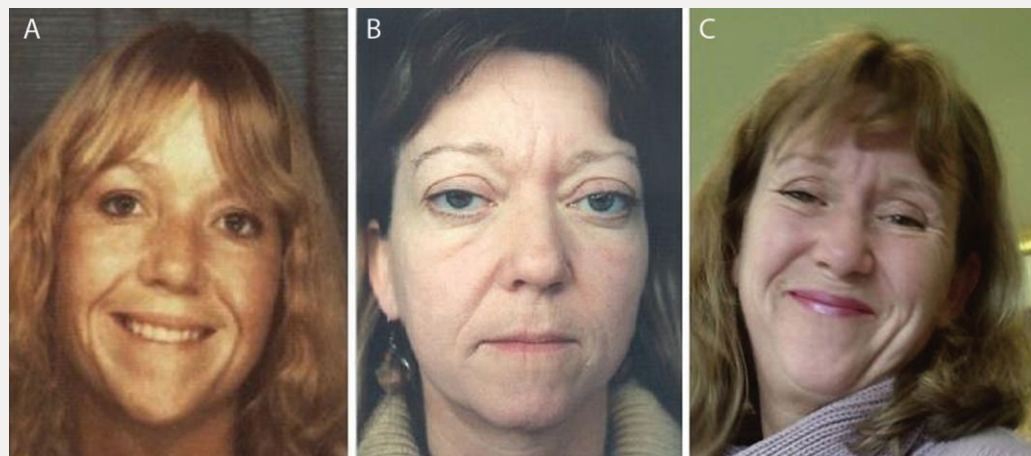

Fig 5 | (A) Before onset of thyroid eye disease. (B) After onset of thyroid eye disease and minor surgery. (C) After orbital decompression and corrective surgery for thyroid eye disease

**Box 4 Useful mnemonics****NOSPECS classification for remembering clinical features**

- N—No signs or symptoms
- O—Only signs (such as lid retraction), no symptoms
- S—Soft tissue involvement
- P—Proptosis
- E—Extraocular muscle involvement
- C—Corneal involvement
- S—Sight loss

**TEARS mnemonic for remembering initial management**

- T—Tobacco abstinence is immensely important
- E—Euthyroidism must be achieved and maintained
- A—Artificial tears are helpful for the majority of patients and can afford rapid relief from the symptoms of corneal exposure
- R—Referral to a specialist centre with experience and expertise in treating thyroid eye disease is indicated in all but the mildest of cases
- S—Self-help groups can provide valuable additional support

only one or two surgical procedures. The best results are achieved by following the sequence of decompression first, muscle surgery second, and eyelid surgery third.<sup>19</sup>

Despite an impression that surgical rehabilitation should be offered only to patients with severe disease, specialist centres can offer surgical treatment to patients with lesser degrees of severity of eye disease with excellent results and little risk of substantial morbidity.

**Mnemonics and thyroid eye disease**

Box 4 shows the NOSPECS classification, which is now outdated as a means of assessing patients with thyroid eye disease for clinical studies, but is still a useful reminder of the clinical features of the disease.<sup>20</sup> We propose the mnemonic TEARS to highlight the important aspects of initial management by non-

specialists (box 4) and draw attention to the psychological impact of the condition, which may not always be appreciated by clinicians.<sup>21</sup>

**Prevention**

Smoking, uncontrolled thyroid dysfunction, and radioiodine therapy are risk factors for development or exacerbation of thyroid eye disease.<sup>22</sup> In the absence of clinical evidence of thyroid eye disease, radioiodine can be used safely in patients with Graves' disease. Expert advice should be sought before use of radioiodine in patients with established thyroid eye disease. Passive smoking may be a risk factor for development of thyroid eye disease in childhood.

**Contributors:** All authors contributed to the literature search, planning, and writing of this review. PP is guarantor.

**Competing interests:** None declared.

**Provenance and peer review:** Commissioned; externally peer reviewed.

**ADDITIONAL EDUCATION RESOURCES**

Cawood T, Moriarty P, O'Shea D. Recent developments in thyroid eye disease. *BMJ* 2004;329:385-90.

Wiersinga WM. Management of Graves' ophthalmopathy. *Nat Clin Pract Endocrinol Metab* 2007;3:396-404.

Bartalena L, Baldeschi L, Dickinson A, Eckstein A, Kendall-Taylor P, Marcocci C, et al; European Group on Graves' Orbitopathy (EUGOGO). Consensus statement of the European Group on Graves' orbitopathy (EUGOGO) on management of GO. *Eur J Endocrinol* 2008;158:273-85.

European Group on Graves' Orbitopathy ([www.eugogo.org](http://www.eugogo.org))—Official site of EUGOGO. Contains a detailed protocol and colour atlas for assessing patients with thyroid eye disease.

Thyroid disease manager ([www.thyroidmanager.org](http://www.thyroidmanager.org))—Comprehensive online resource on thyroid disease for clinicians and patients.

BMJ Learning. Recent advances in thyroid eye disease: an up to date guide (<http://learning.bmj.com/learning/search-result.html?moduleId=5003231>; access requires registration)—Interactive module for clinicians.

**INFORMATION RESOURCES FOR PATIENTS**

British Thyroid Foundation ([www.btf-thyroid.org](http://www.btf-thyroid.org)). United Kingdom patient-led charitable organisation dedicated to helping those with thyroid disorders.

Thyroid Eye Disease Charitable Trust ([www.tedct.co.uk](http://www.tedct.co.uk))—Comprehensive online textbook of thyroidology for clinicians.

British Thyroid Association ([www.british-thyroid-association.org/info-for-patients](http://www.british-thyroid-association.org/info-for-patients))—Non-profit making learned society of professional clinical specialist doctors and scientists in the United Kingdom who manage patients with thyroid disease or are researching the thyroid and its diseases in humans.

NHS Direct Health Encyclopedia ([www.nhsdirect.nhs.uk/articles/article.aspx?articleId=204](http://www.nhsdirect.nhs.uk/articles/article.aspx?articleId=204))—Comprehensive information service for patients.

American Thyroid Association ([www.thyroid.org/patients/brochures.html](http://www.thyroid.org/patients/brochures.html))—Official site of American professionals. Includes resources for patients with thyroid diseases.

**ONGOING RESEARCH**

Rituximab (a humanised mouse monoclonal antibody to CD20, used extensively for B cell leukaemias, lymphomas, rheumatoid arthritis, and other autoimmune diseases) has been shown in a small case controlled study to have a beneficial effect in patients with thyroid eye disease. Larger randomised controlled studies are awaited to ascertain the role of this drug in thyroid eye disease.

EUGOGO is conducting a large randomised controlled study on the use of antioxidants in mild to moderately severe thyroid eye disease. The group is also doing a randomised controlled trial to define the optimum dose of intravenous methylprednisolone in moderately severe thyroid eye disease. A British consortium is doing a randomised controlled trial to assess the efficacy of oral steroid with or without azathioprine and orbital irradiation (CIRTED study).

The insulin like growth factor 1 receptor and thyroid stimulating hormone receptor have been identified as potentially important autoantigens in the pathogenesis of the disease and are being studied.

**SUMMARY POINTS**

Thyroid eye disease can masquerade as allergic conjunctivitis  
 Assess and refer early to specialist centres  
 Restore and maintain euthyroidism  
 Manage smoking habit aggressively  
 If steroid treatment is indicated, pulses of intravenous methylprednisolone are preferable to oral steroids

- 1 Bartley GB, Fatourechi V, Kadmas EF, Jacobsen SJ, Ilstrup DM, Garrity JA, et al. The incidence of Graves' ophthalmopathy in Olmsted County, Minnesota. *Am J Ophthalmol* 1995;120:511-7.
- 2 Perros P, Baldeschi L, Boboridis K, Dickinson AJ, Hullo A, Kahaly GJ, et al. Questionnaire survey on the management of Graves' orbitopathy in Europe. *Eur J Endocrinol* 2006;155:207-11.
- 3 Bartalena L, Baldeschi L, Dickinson A, Eckstein A, Kendall-Taylor P, Marcocci C, et al. Consensus statement of the European Group on Graves' orbitopathy (EUGOGO) on management of GO. *Eur J Endocrinol* 2008;158:273-85.
- 4 Salvi M, Zhang ZG, Haegert D, Woo M, Liberman A, Cadarso L, et al. Patients with endocrine ophthalmopathy not associated with overt thyroid disease have multiple thyroid immunological abnormalities. *J Clin Endocrinol Metab* 1990;70:89-94.
- 5 Khoo TK, Bahn RS. Pathogenesis of Graves' ophthalmopathy: the role of autoantibodies. *Thyroid* 2007;17:1013-8.
- 6 Orgiazzi J. Pathogenesis. In: Wiersinga WM, Kahaly GJ, eds. Graves' orbitopathy. A multidisciplinary approach. Basel: Karger, 2008:41-56.
- 7 Prabhakar BS, Bahn RS, Smith TJ. Current perspective on the pathogenesis of Graves' disease and ophthalmopathy. *Endocr Rev* 2003;24:802-35.
- 8 Gianoukakis AG, Khadavi N, Smith TJ. Cytokines, Graves' disease, and thyroid-associated ophthalmopathy. *Thyroid* 2008;18:953-8.
- 9 Boboridis K, Perros P. General management plan. In: Wiersinga WM, Kahaly GJ, eds. Graves' orbitopathy. A multidisciplinary approach. Basel: Karger, 2008:88-95.
- 10 Wiersinga WM. Management of Graves' ophthalmopathy. *Nat Clin Pract Endocrinol Metab* 2007;3:396-404.
- 11 Kendall-Taylor P. Natural history. In: Wiersinga WM, Kahaly GJ, eds. Graves' orbitopathy. A multidisciplinary approach. Basel: Karger, 2008:78-87.
- 12 Wiersinga WM, Perros P, Kahaly GJ, Mourits MP, Baldeschi L, Boboridis K, et al. Clinical assessment of patients with Graves' orbitopathy: the European Group on Graves' Orbitopathy recommendations to generalists, specialists and clinical researchers. *Eur J Endocrinol* 2006;155:387-9.
- 13 Bartalena L, Tanda ML, Piantanida E, Lai A. Glucocorticoids and outcome of radioactive iodine therapy for Graves' hyperthyroidism. *Eur J Endocrinol* 2005;153:13-4.
- 14 Perros P, Kendall-Taylor P, Neoh C, Frewin S, Dickinson J. A prospective study of the effects of radioiodine therapy for hyperthyroidism in patients with minimally active Graves' ophthalmopathy. *J Clin Endocrinol Metab* 2005;90:5321-3.
- 15 Hart RH, Perros P. Glucocorticoids in the medical management of Graves' ophthalmopathy. *Minerva Endocrinol* 2003;28:223-31.
- 16 Hart RH, Kendall-Taylor P, Crombie A, Perros P. Early response to intravenous glucocorticoids for severe thyroid-associated ophthalmopathy predicts treatment outcome. *J Ocul Pharmacol Ther* 2005;21:328-36.
- 17 Mourits MP. Does radiotherapy have a role in the management of thyroid orbitopathy? View 2. *Br J Ophthalmol* 2002;86:104-6.
- 18 Neoh C, Eckstein A. Eyelid surgery. In: Wiersinga WM, Kahaly GJ, eds. Graves' orbitopathy. A multidisciplinary approach. Basel: Karger, 2008:188-200.
- 19 Baldeschi L. Rehabilitative surgery. In: Wiersinga WM, Kahaly GJ, eds. Graves' orbitopathy. A multidisciplinary approach. Basel: Karger, 2008:160-175.
- 20 Dickinson AJ, Perros P. Controversies in the clinical evaluation of active thyroid-associated orbitopathy: use of a detailed protocol with comparative photographs for objective assessment. *Clin Endocrinol (Oxf)* 2001;55:283-303.
- 21 Coulter I, Frewin S, Krassas GE, Perros P. Psychological implications of Graves' orbitopathy. *Eur J Endocrinol* 2007;157:127-31.
- 22 Krassas GE, Perros P. Prevention of thyroid associated-ophthalmopathy in children and adults: current views and management of preventable risk factors. *Pediatr Endocrinol Rev* 2007;4:218-24.

**A fine thread**

Morocco, Kashmir, Pakistan—the stamps of these countries in my passport, in succession, could be considered a cause for concern. However, my visits to these places last year were for celebrations of an extraordinary kind; in each place I was attending a wedding that witnessed not just the bonding of two people but of two rich cultures and heritages from across the globe.

In Morocco the wedding was of a south Indian boy to a Moroccan girl; in Pakistan I saw the marriage of an Indian boy to a Pakistani girl; and in Kashmir a Japanese boy married a Kashmiri girl. These young people were crossing boundaries not only on a personal level but also on a national and cultural level, and hopefully bringing in a new era for the 21st century. What an extraordinary heritage would belong to their children. They would truly be citizens of the world.

In each celebration there was external diversity, with local custom and tradition in force, each side taking pride in and showing and sharing his or her heritage. However, there was a core of commonality that ran through each event—the anxious expression on the fathers' faces, the tears in the mothers' eyes, the enjoyment of the guests, and the shy happiness of the bride and groom. There was no differentiation of the expression of these feelings by country of origin.

As you were reading, how much time did you focus on the differences?

On a hospital ward, I have seen a sick elderly Gujarthi woman who can speak no English visited by her son every day; in the next bed is an elderly mother from Essex

who is visited by her “skinhead” son every day. The concern of the sons for their mothers, the care of the mothers for their sons, the joy of seeing a grandchild coming to visit—these are moments that shape our lives, and they are the same across all countries and know no boundaries.

So why do we focus so much of our time on the differences?

The pictures of loss and grief in one part of the world are the same as in any other—women losing their husbands, children losing their parents, the bravery of the ordinary man working in the Marriott in Islamabad is no different from that seen in the Taj in Mumbai, or that in New York.

So why do we focus so much of our time on the differences?

We, as professionals delivering health care, are in an extraordinary position to understand this commonality. Every day we see this fine thread that binds all of us; in sickness we all wish for health; in illness we all wish not to be a burden to others; in our old age we all wish to be able to maintain our dignity until our last days.

So why do WE also focus so much of our time on the differences?

**Yasmin Drabu** medical director, Barking, Havering  
 yasmin.drabu@bhrhospitals.nhs.uk  
 Cite this as: *BMJ* 2009;338:b341