

## Acne associated with inhaled glucocorticosteroids

Drs J R HUGHES, E M HIGGINS, and A W P DU VIVIER (Department of Dermatology, King's College Hospital, London SE5 9RS) write: High dose inhaled glucocorticosteroids are known to have systemic effects on the skin. We describe a patient who developed acne while using an inhaled glucocorticosteroid, an association not previously reported.

A 75 year old man was referred to our department with a four year history of a papulopustular eruption on his back. This had been diagnosed as acne but had not responded to conventional treatment with topical antibiotics or long term oral minocycline or erythromycin. He had no history of acne or other skin disease.

He had a 13 year history of late onset asthma. Initial treatment with inhaled salbutamol did not control his symptoms and he had needed intermittent courses of oral steroids for the first eight years after diagnosis. These were then stopped and replaced by oral aminophylline 450 mg twice daily, beclomethasone dipropionate 500 mg twice daily, and salbutamol 200 µg four times daily by aerosol inhalation. His asthma was well controlled and he had not taken oral steroids for the past five years.

Widespread papules and pustules, largely surrounding hair follicles and without comedones, were present on his back. Clinically this represented acne. A skin biopsy was performed which showed a mixed inflammatory infiltrate but no keratin plugging, a histological picture consistent with drug induced acne. It was not possible to reduce his inhaled glucocorticosteroids without exacerbating his asthma and his acne persisted.

Oral and topical steroids are well known to produce acne,<sup>1,2</sup> and inappropriate use of topical steroids on the face can result in a condition which simulates acne, perioral dermatitis.<sup>3</sup> Inhaled high-dose glucocorticosteroids have recently been shown to have both local (increased friability of the oral mucosa with haemorrhagic blistering<sup>4</sup>) and systemic (significant thinning of the skin and increased purpura<sup>5</sup>) effects on the skin. Other systemic effects of high dose inhaled glucocorticosteroids are well recognised.<sup>6</sup> Our case provides evidence of yet another systemic effect of inhaled glucocorticosteroids.

The manufacturers have unpublished evidence of acne being associated with inhaled beclomethasone dipropionate (Allen and Hanburys, personal communication). In these cases the acne tended

to improve or resolve when the inhaled glucocorticosteroid was withdrawn or the dose reduced.

Acne in a 75 year old is unusual and requires investigation. In the elderly acne may be drug induced. This case also has implications for teenagers using glucocorticosteroid inhalers. If glucocorticosteroids precipitate or exacerbate acne treatment may be difficult.

- 1 Plewig G, Kligman AM. Induction of acne by topical steroids. *Arch Dermatol Forsch* 1973;247:29-52.
- 2 Kaidbey KH, Kligman AM. The pathogenesis of topical steroid acne. *J Invest Dermatol* 1974;62:31-6.
- 3 Sneddon I. Iatrogenic dermatitis. *BMJ* 1969;4:49.
- 4 Higgins EM, du Vivier AWP. Angina bullosa haemorrhagica—a possible relation to steroid inhalers. *Clin Exp Dermatol* 1991;16:244-6.
- 5 Capewell S, Reynolds S, Shuttleworth D, Edwards C, Finlay AY. Purpura and dermal thinning associated with high-dose inhaled corticosteroid. *BMJ* 1990;300:1548-51.
- 6 Stead RJ, Cohen NJ. Adverse effects of inhaled corticosteroids. *BMJ* 1989;298:403-4.

## Iron dextran and systemic lupus erythematosus

Professor V M S OH (National University Hospital, Singapore 0511) writes: Iron dextran is a complex of ferric hydroxide and dextran which may produce both acute and delayed reactions. I report the induction of systemic lupus erythematosus by total dose iron dextran.

A 36 year old Chinese woman had iron deficiency anaemia from menorrhagia. She had had episodes of febrile polyarthritis since 1985 in Indonesia, but no serological evidence of systemic lupus erythematosus. In April 1990 a gynaecologist infused iron dextran, 10 ml of 200 g/l solution (2 g), intravenously under promethazine cover. The patient experienced fever, lassitude, and aching joints 64 hours later. Concurrent drugs were norethisterone 20 mg, ferrous fumarate 600 mg, and vitamin C 300 mg daily. Examination showed a malar rash, periungual vasculitis, and polyarthritis. The blood count was normal except for a haemoglobin of 85 g/l; erythrocyte sedimentation rate was 122 mm in the first hour. Serological tests showed: antinuclear antibody at 1/320 dilution; diffuse nuclear immunofluorescence; anti-double stranded DNA antibody 25.3 mg/l by radioimmunoassay (Immunodiagnostic Systems, UK); rheumatoid factor <30 IU/ml; C3 and C4 316 and 82 mg/l respectively; C reactive protein 2.2 mg/l. The illness resolved in five days with oral prednisolone. The patient remained well save for intermittent arthritis; uterine myomectomy was done in June 1990. In January 1991

antinuclear antibody titre was 1/80 and anti-DNA antibody was not detected. In February 1992 the patient agreed to receive iron dextran 10 µl (20 mg) intravenously. Forty two hours later she had fever, polyarthritis, and leucopenia and lymphopenia. The serum anti-DNA antibody level was 20.9 mg/l; antinuclear antibody titre 1/160; and C3, C4, and C reactive protein levels were low. In April 1992 she was clinically normal with an antinuclear antibody titre of 1/40.

Iron dextran infusion may cause reactions two to three days later, including fever,<sup>1,2</sup> myalgia,<sup>1,2</sup> and exacerbation of rheumatoid arthritis.<sup>1,4</sup> The association with a lupus like disorder and its recurrence after rechallenge suggest that the drug may induce systemic lupus erythematosus, though the Committee on Safety of Medicines and the manufacturer have received no such reports. The timing of the reaction suggests delayed hypersensitivity or immune complex disease as the mechanism. Clinicians should recognise that iron dextran may both induce systemic lupus erythematosus and exacerbate the pre-existing disorder.<sup>1</sup>

- 1 Hamstra RD, Block MH, Schocket AL. Intravenous iron dextran in clinical medicine. *JAMA* 1980;243:1726-31.
- 2 Anonymous. Iron dextran. In: Reynolds JEF, ed. *Martindale: the extra pharmacopoeia*. Part 1. 29th ed. London: The Pharmaceutical Press, 1989:1193-5.
- 3 Reddy PS, Lewis M. The adverse effect of intravenous iron dextran in rheumatoid arthritis. *Arthritis Rheum* 1969;12:454-7.
- 4 Blake DR, Lunec J, Ahern M, Ring EFJ, Bradfield J, Gutteridge JMC. Effect of intravenous iron dextran on rheumatoid synovitis. *Ann Rheum Dis* 1985;44:183-8.

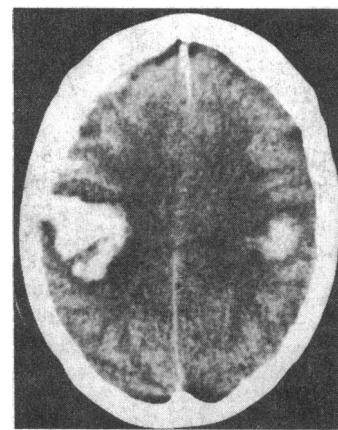
## Intracerebral haemorrhage after dermal nitrate application

Dr M BOGGILD (North Staffs Hospital Centre, Stoke on Trent ST4 7QB) writes: A 65 year old patient presented to her general practitioner with symptoms suggestive of paroxysmal nocturnal dyspnoea. She had a history of atrial fibrillation and transient ischaemic attacks. She had been well on treatment with digoxin and warfarin for three years. Examination was unremarkable and the patient was prescribed glyceryl trinitrate patches.

Two hours after applying the first patch the patient developed a severe frontal headache. The patch was removed soon afterwards, but the next morning the headache persisted, the patient was unwell, and she was referred to hospital.

Examination showed a moderately depressed conscious level. There was no neck stiffness, and reflexes were generally depressed, though plantars

were bilaterally extensor. An electrocardiogram showed no acute changes, international normalised ratio (INR) was 2.1, platelet count was 209×10<sup>9</sup>/ml. Urgent computed tomography showed bilateral parietal intracerebral haemorrhages and a small frontal subdural haemorrhage (figure). There was no history of trauma. Over the next day her condition deteriorated, and she died 48 hours after applying the patch.



Bilateral parietal intracerebral haemorrhages and frontal subdural haemorrhage

Nitrate preparations act on cerebral circulation in several ways. Cerebral vasodilatation is well recognised<sup>1</sup> and is the likely cause of the common nitrate headache. Nitrates may precipitate postural hypotension. A report of transient ischaemic attacks precipitated by nitrates suggested that vasodilatation may fail to occur in diseased vessels, thereby shunting blood preferentially to normal vasculature and resulting in local ischaemia.<sup>2</sup> Haemorrhage into a pituitary tumour has also been reported, but again this was thought to be secondary to abnormalities of local vasculature.<sup>3</sup>

In this case a dermal nitrate preparation seems to have precipitated intracerebral haemorrhage in a patient with cerebrovascular disease. Both the timing of the onset of symptoms and the presence of multiple haemorrhages make a causal relation likely. The patient was receiving anticoagulants, thus slightly increasing the risk of haemorrhage. Nevertheless, it seems reasonable to recommend that this class of drugs should be used with caution in patients with cerebrovascular disease.

- 1 Kistler JP, Lees RS, Candia G, Zervas NT, Crowell RM, Ojemann RG, et al. Intravenous nitroglycerin in experimental cerebral vasospasm. *Stroke* 1979;10:26-9.
- 2 Purvin VA, Dunn DW. Nitrate induced transient ischaemic attacks. *Southern Med J* 1981;74:1130-1.
- 3 Bevan JS, Oza AM, Burke CW, Adams CB. Pituitary apoplexy following isosorbide administration. *J Neurol Neurosurg Psychiatry* 1987;50:636-7.