

## Congenital hypertrophy of retinal pigment epithelium: a sign of familial adenomatous polyposis

Pamela D Chapman, William Church, John Burn, Alastair Gunn

### Abstract

Families of people known to have familial adenomatous polyposis are screened for signs of the disease by yearly examination of the bowel. Multiple areas of congenital hypertrophy of the retinal pigment epithelium have been described in patients with familial adenomatous polyposis. To assess the reliability of this marker 40 patients with familial adenomatous polyposis, representing all 25 pedigrees with living affected members in the Northern region's polyposis registry, were examined for hypertrophy of the retinal pigment epithelium. All had multiple lesions, ranging in number from two to over 40. None of the 35 controls had more than two lesions.

Ocular examination is valuable for detecting carriers of the gene for familial adenomatous polyposis before their symptoms develop.

### Introduction

Familial adenomatous polyposis is an autosomal dominant disorder characterised by multiple adenomas of the large bowel, which have a propensity for early malignant change. Screening of families with familial adenomatous polyposis entails yearly bowel examinations by sigmoidoscopy or colonoscopy from puberty to the age of 50. Gardner's syndrome is characterised by polyposis with extracolonic features. Multiple areas of congenital hypertrophy of the retinal pigment epithelium (figure) are a consistent feature of Gardner's syndrome<sup>1,2</sup> and more recently have been described in patients with familial adenomatous polyposis.<sup>3</sup>

Because we have established a register of patients with polyposis in the Northern region, which has a population of 3 million, we were able to identify known carriers of the disease. We examined them for hypertrophy of the retinal pigment epithelium and assessed the reliability of this marker in the defined population.

### Subjects and methods

We identified 50 subjects with polyposis, regardless of extracolonic features, from surgical records and offered them examination by indirect binocular funduscopy. Forty patients attended, representing all of the 25 pedigrees with living affected members. Controls were members of university and hospital staff.

### Results

All carriers of the gene for familial adenomatous polyposis had multiple areas of hypertrophy of the retinal pigment epithelium ranging in number from two to over 40. No control had more than two (table). The separation of carriers and controls was thus highly

significant ( $\chi^2=62.3$ ,  $df=2$ ,  $p<0.0001$ ). A cut off of two areas of hypertrophy as the upper limit of normal gave a false positive rate of 0% and a false negative rate of 7.5%.

*Number of areas of congenital hypertrophy of retinal pigment epithelium in patients with familial adenomatous polyposis and adult controls*

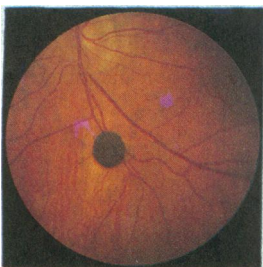
No of lesions	Carriers of familial adenomatous polyposis gene			
	Controls	Age at onset of symptoms late or uncertain	Polyps at <21 years	Polyps in childhood or malignancy at <21 years
0	20			
1	11			
2	4	3		
3		3		
4				
5		1	2	
6		1	1	
7		1		
8		1		
9			1	1
10-19		9	6	1
20-29		2		1
30-39		2	2	
40-49		1		
50-79				
≥80				1

Patients and controls were of the same ethnic origin and of comparable age (mean (range) age of controls 30 (17-59) and of patients 38 (15-67)). Patients known to have had early onset of bowel disease had many retinal lesions. Conversely, one of the patients with only two lesions had developed bowel disease at the age of 48, and his father, who had three lesions, had developed the disease at 75.

### Discussion

Hypertrophy of the retinal pigment epithelium is a consistent extracolonic abnormality in familial adenomatous polyposis. This further undermines any distinction between this condition and Gardner's syndrome and suggests that they both result from the same gene defect. The small number of reported pedigrees with polyposis without eye signs may represent a distinct genetic entity.<sup>4</sup> Hypertrophy of the retinal pigment epithelium may develop at any time in life in response to trauma, but pigmented lesions are considered to be congenital.<sup>2</sup> Identification of young carriers of the disease by funduscopy will facilitate the identification of the precise site of the polyposis gene on the long arm of chromosome 5.<sup>5</sup>

The problems of tracing people with familial adenomatous polyposis are compounded by the need for a yearly bowel examination. Funduscopy combined with analysis of pedigrees and a search for linked DNA markers may identify non-carriers with sufficient confidence to obviate the need for three decades of



*Typical area of congenital hypertrophy of retinal pigment epithelium*

Division of Human Genetics, University of Newcastle upon Tyne, Newcastle upon Tyne NE2 4AA

Pamela D Chapman, SRN, genetic nursing sister  
John Burn, MRCP, consultant clinical geneticist

Department of Ophthalmology, Royal Victoria Infirmary, Newcastle upon Tyne NE1 4LP  
William Church, FRCS, senior registrar

Department of Surgery, Ashington Hospital, Northumberland  
Alastair Gunn, FRCS, consultant surgeon

Correspondence to: Dr Burn.

*Br Med J* 1989;298:353-4

endoscopy. The presence of eye signs should improve compliance with bowel examination.

This study shows that hypertrophy of the retinal pigment epithelium is a valuable clinical sign of familial adenomatous polyposis, although confirmatory studies are required to establish the sensitivity and specificity of this finding. If cases of familial adenomatous polyposis of early onset can reliably be identified by examination of the eye paediatric management may be amended; invasive bowel examination could be delayed until after adolescence in children who do not have congenital hypertrophy of the retinal pigment epithelium.

PDC is supported by the Northern Regional Research

Committee and the Imperial Cancer Research Fund. We thank the surgeons in the Northern region for their cooperation.

- 1 Blair NP, Trempe CL. Hypertrophy of the retinal pigment epithelium associated with Gardner's syndrome. *Am J Ophthalmol* 1980;90:661-7.
- 2 Traboulsi EI, Krush AJ, Gardner EJ, et al. Prevalence and importance of pigmented ocular fundus lesions in Gardner's syndrome. *N Engl J Med* 1987;316:661-7.
- 3 Diaz-Lopez M, Menezo JL. Congenital hypertrophy of the retinal pigment epithelium in familial adenomatous polyposis. *Arch Ophthalmol* 1988;106:412-3.
- 4 Traboulsi EI, Maumenee IH, Krush AJ, et al. Pigmented ocular fundus lesions in the inherited gastrointestinal polyposis syndromes and in hereditary nonpolyposis colorectal cancer. *Ophthalmology* 1988;95:964-9.
- 5 Bodmer WF, Bailey CJ, Bodmer J, et al. Localisation of the gene for familial adenomatous polyposis on chromosome 5. *Nature* 1987;328:614-6.

(Accepted 22 November 1988)

## Assessment of DNA fingerprinting for rapid identification of outbreaks of systemic candidiasis

Ruth Matthews, James Burnie

### Abstract

DNA fingerprinting was assessed as an improved typing system for *Candida albicans* aimed at speeding the implementation of cross infection control measures in outbreaks of systemic candidiasis. The study was carried out with 45 previously characterised isolates from five different outbreaks and with 96 unrelated isolates from a mixed control population. Sixteen different genotypes were produced. Results were obtainable within days, reproducibility was high, and there was good discrimination among different outbreaks.

Compared with existing typing systems DNA fingerprinting provides a robust system that may be used rapidly to identify outbreaks of nosocomial candidiasis in laboratories with no specialist skill in typing *C albicans*.

### Introduction

Mortality from systemic candidiasis is over 70%,<sup>1</sup> so early identification of outbreaks is particularly important. Prompt implementation of barrier nursing and handwashing with fungicides prevents deaths.<sup>2</sup> Such cross infection control measures are expensive and time consuming, so that it is important to be able to distinguish an outbreak from a cluster of unrelated cases due to endogenous infections. In an outbreak a single epidemic strain causes cross infection among patients. This requires a fast, reliable typing system. Existing typing systems are slow and need to be used in combination.<sup>3,5</sup> The setting up of a DNA diagnostic service for inherited disorders has recently been described,<sup>6</sup> and we decided to investigate the potential of DNA fingerprinting in the early identification of outbreaks of nosocomial candidiasis. Isolates were examined from five outbreaks affecting 37 patients, 27 of whom died.

### Materials and methods

**Isolates**—We examined 45 isolates from five outbreaks of systemic candidiasis and 94 control isolates from 51 patients with oral thrush, 33 patients with vaginal candidiasis, and 10 patients with candidal septicaemia. Two *Candida albicans* type strains—namely, National Collection of Type Cultures (NCTC) 3153 (serotype A) and NCTC 3156 (serotype B)—were also typed. Identification as *C albicans* was based on a

positive germ tube test result and the pattern of sugar reactions on the yeast API 20C system (API Laboratories, Basingstoke).

**DNA fingerprinting**—After overnight growth in 2% glucose broth yeasts were harvested, washed in 1M sorbitol, and incubated for 30 minutes at 30°C in 1 ml 1.2M sorbitol and 0.1M edetic acid pH 7.5 containing 1 µl 2-mercaptoethanol and 0.1 mg zymolase. The resultant spheroplasts, after resuspension in 0.5 ml 50mM edetic acid pH 8.5, were lysed by adding sodium dodecyl sulphate (2 g/l). Diethyl pyrocarbonate (30 µl) was added and the whole incubated at 70°C for 30 minutes, followed by 50 µl 5M potassium acetate and incubation at 0°C for 30 minutes. After centrifugation the supernatant was decanted into 1 ml cold ethanol to precipitate nucleic acid. This was washed, dried, and suspended in 100 µl TE (10mM trometamol (TRIS) hydrochloride, 1mM edetic acid pH 7.5) containing 10 µg deoxyribonuclease free ribonuclease at 37°C for one hour to remove RNA. DNA was precipitated with ethanol, suspended in 85 µl TE, and digested to completion with an excess (200 U) of EcoRI restriction endonuclease. Digests were run on a horizontal 0.8% agarose gel together with Hind III digested λ and Hind III/EcoRI digested λ as size markers.<sup>7</sup>

**Typing outbreak isolates**—Isolates had been characterised by pre-existing typing systems. Isolates from the first outbreak<sup>3</sup> (at The London Hospital) were serotyped,<sup>8</sup> biotyped,<sup>9</sup> morphotyped,<sup>10</sup> and antigenically fingerprinted by probing immunoblots of each isolate with rabbit candidal antiserum.<sup>5</sup> A combination of morphotyping and immunoblot fingerprinting was used to identify outbreaks in the intensive care unit at Queen Elizabeth Hospital, Birmingham; the dialysis unit at St Helier Hospital, Carshalton; King's College Hospital neonatal unit; and a second outbreak in the intensive care unit at The London Hospital.<sup>4</sup>

### Results

Reproducibility was high, and all isolates were typable within 48 hours. Sixteen different types were recognised on the basis of variations in six intensive bands at 6 kb, 5.1 kb, 4.2 kb, 3.7 kb, 2.5 kb, and 1.9 kb (table I; figs 1 and 2). Multiple bands sometimes occurred at 6-7 kb or 2.3-2.7 kb. DNA type 2 predominated among control isolates, accounting

Department of Medical Microbiology, St Bartholomew's Hospital, London EC1A 7BE  
Ruth Matthews, MD, Wellcome senior research fellow  
James Burnie, MD, consultant bacteriologist

Correspondence to: Dr Matthews.

*Br Med J* 1989;298:354-7