

by the χ^2 test. *p* Values were corrected for the number of tests performed by multiplying by the number of phenotypes compared.

Seven years after diagnosis of diabetes 43 of the 110 patients had retinopathy and by 10 years this had risen to 88. The table shows the relation between retinopathy and the Gm phenotypes. The frequency of the phenotype Gm (zafx;n;bg) was significantly higher in the group with retinopathy than that without (37% (16/43) *v* 6% (4/67), *p*<0.001, corrected *p*<0.01) at the seven year review; there was no other significant association. At the 10 year review no significant differences were detected. By this time, however, only 22 of the original cohort remained free of retinopathy. All of the 20 patients with the phenotype Gm (zafx;n;bg) had retinopathy.

Discussion

The phenotype Gm (zaf;n;bg) associated with retinopathy in insulin dependent diabetics² was not associated with non-insulin dependent diabetics, but the photographs taken at the seven year review showed that retinopathy was associated with phenotype Gm (zafx;n;bg). Furthermore, by the 10 year review all 20 of the patients with this phenotype had retinopathy. These two heterozygous phenotypes differ only in the x allotype, which is characterised by the substitution of glycine for alanine at position 431 of the constant region of the heavy chain.⁴

Both phenotypes identified in the previous² and the present study were heterozygous. Heterozygosity may

confer an enhanced immune response, but this could be confirmed only by family studies. Evidence suggests that an amplified immune response to bacterial antigen is conferred by heterozygosity for the Gm allotype.⁵ This may lead to increased concentrations of circulating immune complexes, which have been reported in patients with microangiopathy.¹

Our findings support a possible association of heavy chain immunoglobulin phenotypes with early development of retinopathy in non-insulin dependent diabetics. The findings in both insulin dependent and non-insulin dependent diabetics suggest that this complication may have an immunogenetic component, which may help to identify diabetics predisposed to microangiopathy.

CM was supported by the British Diabetic Association and by Ames Laboratories.

- 1 Mijovic C, Barnett AH. Immunogenetics of diabetic microangiopathy. In: Barnett AH, ed. *Immunogenetics of insulin dependent diabetes*. Lancaster: MTP Press, 1987:111-20.
- 2 Mijovic C, Fletcher JA, Bradwell AR, Barnett AH. Phenotypes of the heavy chains of immunoglobulins in patients with diabetic microangiopathy: evidence for an immunogenetic predisposition. *Br Med J* 1986;292:433-5.
- 3 Hockaday TDR, Hockaday JM, Mann JL, Turner RC. Prospective comparison of modified fat and low carbohydrate dietary advice in the treatment of diabetes. *Br J Nutr* 1978;39:357-62.
- 4 Schanfield MS, Van Loghem E. Human immunoglobulin allotypes. In: Weir DM, ed. *Handbook of experimental immunology*. Vol 3. *Genetics and molecular immunology*. 4th ed. Oxford: Blackwell Scientific Publications, 1986:94.1-94.18.
- 5 Whittingham S, Mathews JD, Schanfield MS, et al. Interactive effect of Gm allotypes and HLA-locus antigens on the human antibody response to a bacterial antigen. *Clin Exp Immunol* 1980;40:8-15.

(Accepted 14 July 1988)

Antibody to *Saccharomyces cerevisiae* (bakers' yeast) in Crohn's disease

Janice Main, Hamish McKenzie,
Grant R Yeaman, Michael A Kerr,
Deborah Robson, Christopher R Pennington,
David Parratt

The possible role of diet in the pathogenesis of inflammatory bowel disease has prompted several studies of the immune response to food antigens, but no specific abnormality has so far been shown in either Crohn's disease or ulcerative colitis.^{1,2} We report a study of antibody to *Saccharomyces cerevisiae* (bakers' yeast), a common dietary antigen, in patients with inflammatory bowel disease and in controls.

Subjects, methods, and results

We obtained blood samples from 55 patients with Crohn's disease and 40 with ulcerative colitis; the diagnosis was by standard criteria.³ Ethical approval was obtained. Control samples were obtained from 30 blood donors.

To prepare the antigen *S cerevisiae* (dried yeast, Be-Ro) was cultured on Sabouraud agar (Oxoid) for 48 hours at 37°C. The growth was harvested, washed, and resuspended in 0.15M sterile saline. The suspension was heated at 100°C for one hour and diluted in 0.05M carbonate-bicarbonate buffer (pH 9.6) for coating plates.

Nunclon plates (Gibco) were coated with the antigen by incubation for one hour at 37°C and 16 hours at 4°C. Assays were washed three times with 0.05M phosphate buffered saline (pH 7.4) containing 0.01% (vol/vol) Triton X-100. All serum samples were assayed in

duplicate at a dilution of 1:100 in wash buffer. Antibody was detected with anti-IgA or anti-IgG (affinity purified) linked to alkaline phosphatase (Sigma) with *p*-nitrophenyl phosphate (Sigma) as the substrate. The plates were incubated for one hour at 37°C. Optical densities were measured at 410 nm and standardised against a positive reference sample. The significance of differences in antibody titres between groups was tested by the Mann-Whitney test.⁴

Titres of both IgG and IgA to *S cerevisiae* in the patients with Crohn's disease were significantly higher (*p*<0.001) than those in the controls (figure). In contrast, antibody titres in the patients with ulcerative colitis were not significantly different from those in the controls. Among the patients with Crohn's disease there was no significant difference in antibody titres between patients with disease of the small or large bowel (data not shown).

Comment

The considerable difference in titres of antibody to *S cerevisiae* between the patients with Crohn's disease and those with ulcerative colitis contrasts with previous reports of a generalised increase in antibody to food antigens in people with inflammatory bowel disease.^{1,2} A generalised increase may reflect increased exposure to antigens owing to an inflamed or damaged bowel wall and is probably secondary to the primary disease process. In contrast, the response to *S cerevisiae* seemed to be quite specific to Crohn's disease and cannot be easily explained as a secondary phenomenon. Furthermore, the difference between the diseases cannot be accounted for on an anatomical basis, as increased titres of antibody to *S cerevisiae* were not confined to patients with Crohn's disease of the small bowel.

S cerevisiae is unlikely to be a cause of Crohn's disease as it is not a common pathogen, though infections have been reported in immunosuppressed

Department of Medicine,
King's Cross Hospital,
Dundee

Janice Main, MRCP, research registrar
Christopher R Pennington, FRCP, consultant

Department of Medical Microbiology, Ninewells Hospital and Medical School, Dundee

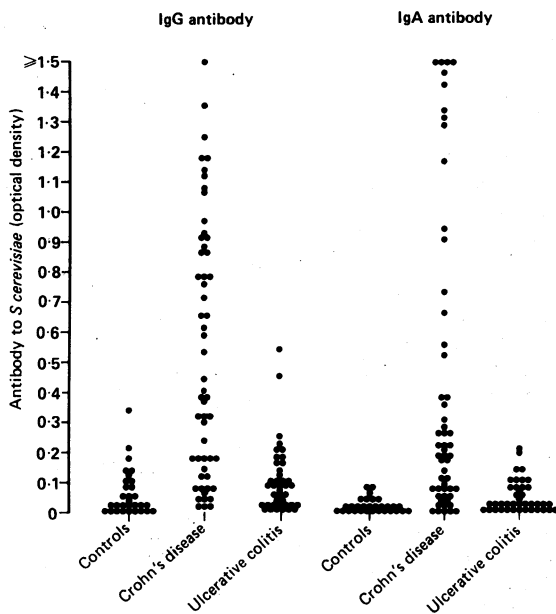
Hamish McKenzie, MB, lecturer
Deborah Robson, BSC, research assistant
David Parratt, MD, senior lecturer

Department of Pathology, Ninewells Hospital and Medical School, Dundee

Grant R Yeaman, BSC, research assistant
Michael A Kerr, PHD, lecturer

Correspondence to: Dr J Main, Department of Medicine, St Mary's Hospital, London W2 1NY.

IgG and IgA antibody to *Saccharomyces cerevisiae* (measured as optical density at 410 nm) in patients with Crohn's disease (n=55) or ulcerative colitis (n=40) and in controls (n=30)



patients.⁵ More probably, Crohn's disease results from hypersensitivity to *S. cerevisiae* antigens, and this would be consistent with the responsiveness of Crohn's disease to steroid treatment and bowel rest. Another possibility is infection by an unknown agent that

cross reacts antigenically with *S. cerevisiae*. Further investigation of the yeast antigens and their potential cross reaction is required.

Strains of *S. cerevisiae* are used in baking and brewing and are found in a wide variety of foodstuffs. A controlled trial of a yeast free diet for patients with Crohn's disease may therefore be worth while. We intend to investigate patients with other diarrhoeal diseases, including coeliac disease, to establish the specificity of antibody to *S. cerevisiae* as a marker for Crohn's disease; our results indicate that it may be valuable in distinguishing Crohn's disease from ulcerative colitis.

This work was supported by research grants from the Scottish Home and Health Department. We are grateful to the blood transfusion service for supplying blood donor serum.

- Paganelli R, Pallone F, Montano S, et al. Isotypic analysis of antibody response to a food antigen in inflammatory bowel disease. *Int Arch Allergy Appl Immunol* 1985;78:81-5.
- Knoflach P, Park BH, Cunningham R, Weiser MM, Albin B. Serum antibodies to cow's milk proteins in ulcerative colitis and Crohn's disease. *Gastroenterology* 1987;92:479-85.
- Clamp SE, Myren J, Bouchier IAD, Watkinson G, de Dombal FT. Diagnosis of inflammatory bowel disease: an international multicentre scoring system. *Br Med J* 1982;284:91-5.
- Snedecor GW, Cochran WG. *Statistical methods*. 6th ed. Iowa: Iowa State University Press, 1967:131.
- Eng RHK, Drehmel R, Smith SM, Goldstein EJC. *Saccharomyces cerevisiae* infections in man. *Sabouraudia* 1984;22:403-7.

(Accepted 28 June 1988)

Rupture of tendon after cryotherapy for hand wart

Victoria M Yates, M M Scott, Elizabeth D Carter

Blackburn Royal Infirmary, Blackburn BB2 8LR

Victoria M Yates, MRCP, consultant dermatologist
M M Scott, FRCS, consultant orthopaedic surgeon
Elizabeth D Carter, MB, clinical assistant

Correspondence to: Dr Yates.

We describe a patient who developed necrosis of the central slip of the extensor tendon of her right little finger after cryotherapy for a viral wart overlying the proximal interphalangeal joint.

Case report

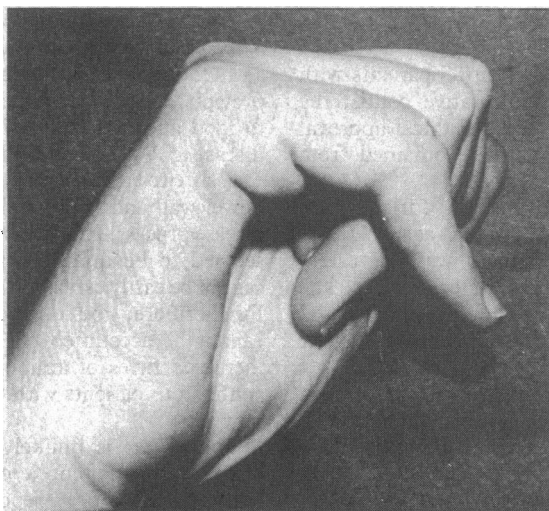
A 25 year old woman was referred for cryotherapy for a large wart over the proximal interphalangeal joint of her right little finger after treatment with topical salicylic acid had failed. Liquid nitrogen was applied to the wart on three occasions at intervals of six weeks with a liquid nitrogen spray with a C nozzle held 2 cm above the surface of the skin. The duration of freezing

on each occasion was 10 seconds from the formation of ice. Twenty four hours after the third application of liquid nitrogen she noticed blistering of the skin over the treated area, and subsequently swelling and flexion occurred at the proximal interphalangeal joint. An x ray film of the joint did not show infection, and the finger was treated with a dynamic splint. As the swelling subsided a boutonniere deformity of the finger was seen with hyperextension of the distal phalanx (figure), and it was obvious that the central slip of the extensor tendon had ruptured.

Surgical exploration showed a defect in the extensor expansion with sloughing of the central slip of the extensor tendon. The defect was corrected by a modified Littler procedure. The patient gradually regained partial function of the finger.

Comment

Blistering of the skin after cryotherapy is a common side effect,¹ but to our knowledge tendon necrosis has not been reported before. Shepherd has shown that connective tissue is not affected by standard freeze times.² Studies on the effects of cryosurgery on peripheral nerves have shown that even the delicate perineurium, which is largely made up of collagen, is unaffected by freezing.³ On the basis of this and other scientific evidence⁴ we did not expect tendon necrosis to occur. In view of this side effect and in the light of a recent report by Keefe and Dick,⁵ who suggested that cryotherapy should be delegated to nurses, we think that anyone treating lesions overlying tendons should exercise caution.



Boutonniere deformity with hyperextension of distal phalanx resulting from cryotherapy for wart on proximal interphalangeal joint

- Zacarian SA, ed. *Cryosurgery for skin cancer and cutaneous disorders*. St Louis: Mosby, 1985:286.
- Shepherd J. The effects of low temperature on dermal connective tissue components. Oxford: Oxford University, 1979. (MSc Dissertation.)
- Barnard D. The effects of extreme cold on sensory nerves. *Ann R Coll Surg Engl* 1980;62:180-7.
- Dawber R. Cold kills! *Clin Exp Dermatol* 1988;13:137-50.
- Keefe M, Dick DC. Dermatologists should not be concerned in routine treatment of warts. *Br Med J* 1988;296:177-9.

(Accepted 20 July 1988)