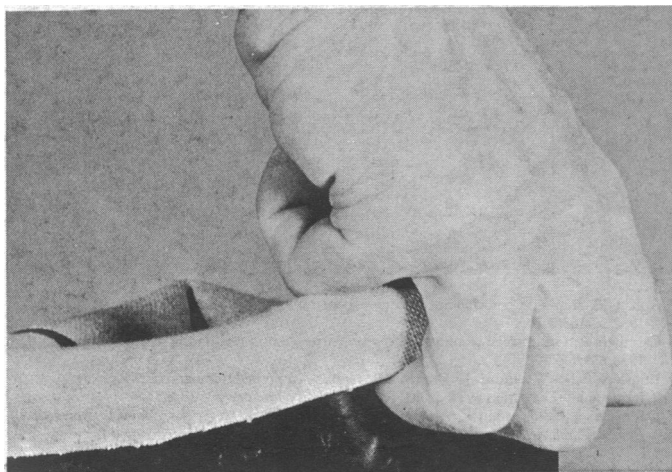


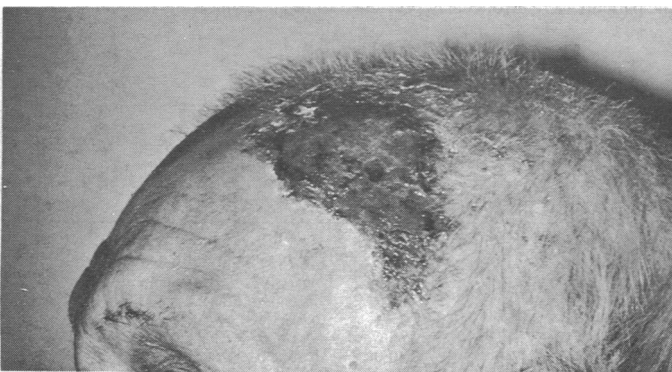## Wellie thrower's finger

With increased participation in sporting activities, new specific sports related injuries are being reported. A 27 year old right handed computer programmer suffered a hyperextension injury to the proximal interphalangeal joint of his right ring finger while competing in a wellie throwing contest. To reduce air resistance and to enable a sound grip to be taken the top of the wellie is rolled down and grasped by the hand, as shown in the photograph below. At the moment of release the wellie will twist. This may result in a finger being caught and hyperextended, resulting in a rupture of the volar plate of the proximal interphalangeal joint. This injury recovered after initial splintage in a plastic volar gutter splint and supervised active mobilisation exercises. This incident emphasises the need for training in the correct techniques—shown in the photograph on the right—for participants in sports.—C B D'A FEARN, Department of Orthopaedics, Cuckfield Hospital, Cuckfield, West Sussex.

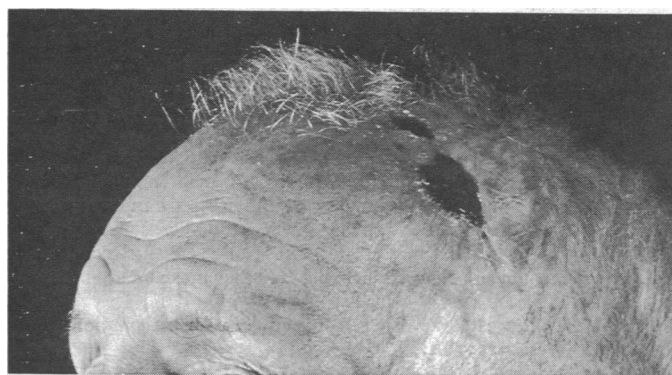

## Effect of scalp burns on common male pattern baldness

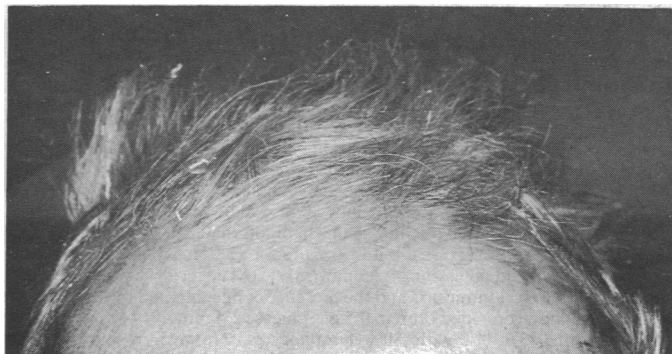
A 78 year old man with common male pattern baldness was dozing in his armchair when he fell head first into a coal fire. He sustained full thickness burns to the left parietotemporal region, the bridge of the nose, and the left infraorbital area. He refused hospital admission and early surgery and was consequently managed as an outpatient. Two weeks later he commented that his bald patch had started to grow hair again, and over the next four months this hair continued to grow. Although interesting, it is difficult to see how this type of stimulation could be applied therapeutically.—R BUCKLAND, G R WILSON, L SULLY, Burns Unit, City Hospital, Nottingham NG5 1PB.



Two weeks after the accident; new hair growth has started.



Six weeks after the accident; hair is now thicker.



Four months after the accident; thick hair growth is now visible.