

Controlled trial of medical treatment of active chronic otitis media

Active chronic otitis media is a common condition affecting 0.6% of adults in the United Kingdom. Initial management is usually by general practitioners, who annually prescribe systemic and topical antibiotics on at least 178 000 and 73 000 occasions respectively (unpublished observations). Despite this there have been few studies of the efficacy of antibiotics,¹⁻⁴ and no study has included a control group of untreated patients or of patients treated solely by aural toilet. We undertook a controlled study comparing appropriate systemic or topical antibiotic treatment with weekly aural toilet and insufflation of boric acid and iodine powder.

Patients, methods, and results

Seventy five patients aged over 16 with active chronic otitis media and without cholesteatoma or aural polyp were allocated randomly to one of three treatment regimens for four weeks. One group received aural toilet weekly by an otologist, who used microscopic vision and suction aspiration when necessary, followed by insufflation of boric acid and iodine powder. The second group received oral systemic antibiotics—namely, cephalexin, flucloxacillin, cloxacillin, or amoxicillin 1-2 g/day. The third group received topical aural antibiotics without steroids—namely, gentamicin (Genticin) three or four drops four times a day or chloramphenicol (Chloromycetin) one or two drops three times a day. The choice of antibiotic depended on the in vitro sensitivity of the aerobic flora isolated from the ear discharge the previous week. Because *Pseudomonas* spp are inherently resistant to oral antibiotics patients from whom they were isolated were randomly allocated to receive either aural toilet or topical antibiotics.

The allocation to treatment regimen was kept blind from the clinicians, with the necessary exception of aural toilet. All medication was supplied in the clinic. Patients were considered to be non-compliers if less than 75% of the medication was used. The efficacy of treatment was assessed after four weeks, when the ears were classified as showing active, mucoid, or inactive disease.⁵

Efficacy of four weeks of treatment in 51 patients with chronic otitis media. (No from whom Pseudomonas spp were isolated before treatment given in parentheses)

| Treatment | No of patients | State of disease | | |
|---------------------|----------------|------------------|--------|----------|
| | | Active | Mucoid | Inactive |
| Aural toilet | 20 (7) | 5 (2) | 8 (3) | 7 (2) |
| Systemic antibiotic | 13 | 8 | | 5 |
| Topical antibiotic | 18 (3) | 11 (1) | 4 (2) | 3 |
| Total | 51 (10) | 24 (3) | 12 (5) | 15 (2) |

Of the 75 patients, 24 were defaulters or non-compliers. The table shows that the disease became inactive in only 15 (29%) of the 51 patients who complied with treatment. Four (21%) of the 19 patients who previously had undergone modified radical mastoidectomy showed inactive disease. No significant difference in results was observed between any drugs or groups of patients.

Comment

The extremely poor results obtained with all three forms of treatment are disappointing and contrast strongly with the reported success rates in non-controlled studies of 80-92% with topical gentamicin^{1 2} and 92% with topical chloramphenicol.³ We are unaware of any study reporting the use of topical steroids. The only systemic antibiotic that has been reported is clindamycin, which had a success rate of 30%.⁴

This study might be criticised because of the relatively small number of patients. The 95% confidence limits suggest that if more patients had been studied a 60% response rate might have been achieved. Larger numbers have received similar management in the same department, albeit without randomisation, with similar results. We decided to investigate potentially more effective forms of treatment rather than to extend this study to show significant differences between treatments, the best of which might have had only a 60% success rate.

Why do antibiotics fail? Possibly our patients, because they were

secondary referrals, had more serious disease than those in other series, but the natural resolution rate in less severe disease would be higher than in our study. The success of topical antibiotics in only two of seven patients with a modified radical cavity suggests that failure of antibiotics is not just a matter of access.

An alternative explanation might be that chronic otitis media is not primarily a bacterial infection. Opportunistic pathogens may be isolated from half of ears with inactive disease (unpublished observations), which indicates that they may be secondary invaders of inflamed mucosa caused by other, as yet undefined, processes.

In conclusion, there is no firm evidence to support the use of systemic antibiotics or topical antibiotics without steroids in active chronic otitis media.

¹ Tambie B, Tambie T. Treatment of purulent otorrhoea with special reference to otitis media. *Clinical Trials Journal* 1976;13:129-36.

² Gyde MC. When the weeping stopped. *Arch Otolaryngol* 1976;102:542-6.

³ Fox FG. Suction combined with chemotherapy in purulent otitis media: a report of 76 cases. *Eye, Ear, Nose and Throat Monthly* 1964;43:48-51.

⁴ Kambata AS. Treatment of chronic discharging ears with clindamycin. *Clinical Trials Journal* 1972;6:20-21.

⁵ Browning GG, Picozzi GL, Sweeney G, Calder IT. Role of anaerobes in chronic otitis media. *Clin Otolaryngol* 1983;8:47-51.

(Accepted 1 June 1983)

Glasgow Royal Infirmary, Glasgow G4 0SF

G G BROWNING, MD, FRCS, consultant, department of otolaryngology
G L PICOZZI, MB, FRCS, senior registrar in otolaryngology, Glasgow rotation scheme

I T CALDER, MSC, MPS, staff pharmacist, pharmacy department
G SWEENEY, BSC, PHD, bacteriologist, department of bacteriology

Correspondence to: Mr G G Browning.

Pulmonary hypertension in systemic lupus erythematosus

Pulmonary hypertension has hitherto been reported rarely in systemic lupus erythematosus. We report on six patients with this condition seen recently at this hospital. None of them showed evidence of parenchymal lung disease considered to be sufficient to cause pulmonary hypertension, and none had overt pulmonary thromboembolism.

Patients, methods, and results

Six patients with systemic lupus erythematosus presented at this hospital with pulmonary hypertension. This had developed up to 29 years after the onset of symptoms of systemic lupus erythematosus. We did not identify parenchymal lung disease sufficient to cause pulmonary hypertension in any of them, and none showed evidence of pulmonary embolism. Five were found to have circulating lupus anticoagulant, an antibody associated with tendency to widespread, in situ thrombosis. Two (cases 2 and 6) had histories of venous thrombotic episodes elsewhere. All patients showed immune complexes as measured by Clq binding assay. We noted other symptoms thought to be associated with the pathogenesis of pulmonary hypertension (table).

Comment

Pulmonary hypertension is well recognised in certain connective tissue diseases, particularly scleroderma, but its occurrence in systemic lupus erythematosus has been infrequently reported.¹ Its aetiology is not clear. Possible factors in its pathogenesis are vasospasm, arteritis, platelet dysfunction, and thromboembolism. A link between pulmonary hypertension, Raynaud's phenomenon, and connective tissue disease was suggested by Walcott *et al*,² who described a series of 23 patients with pulmonary hypertension, seven of whom suffered from Raynaud's phenomenon and three from arthritis. Arthritis has been noted by other workers together with a family history of arthritis and Raynaud's phenomenon in patients with pulmonary hypertension. Raynaud's phenomenon has often been present in the cases of pulmonary hypertension with systemic lupus erythematosus reported to date. Three of our patients

Details of patients with pulmonary hypertension in systemic lupus erythematosus

| Case No | Age (years) | Sex | Raynaud's phenomenon | Lupus anticoagulant | Vasculitis | Pulmonary artery pressure (mm Hg) |
|---------|-------------|-----|----------------------|---------------------|------------|-----------------------------------|
| 1 | 47 | F | + | + | + | 60/25 |
| 2 | 41 | F | - | + | - | 135/25 |
| 3 | 31 | M | - | + | + | 44/20 |
| 4 | 19 | M | + | + | ! | 55/25 |
| 5 | 25 | F | + | - | + | 70/40 |
| 6 | 21 | F | - | + | - | 80/40 |

had Raynaud's phenomenon (though this was mild in all three), raising the possibility of vasospasm as an aetiological factor.

Another possible cause of pulmonary hypertension in our patients was vasculitis. Acute inflammation of small pulmonary arteries and arterioles has been found at necropsy in patients with systemic lupus erythematosus. In our series vasculitic lesions were noted in cases 1, 3, and 5 and one patient (case 4) developed a vocal cord palsy that may have been vasculitic in origin. Our data do not, however, suggest a major pathogenetic role for vasculitis.

Platelet dysfunction has recently been suggested as another possible aetiological factor in pulmonary hypertension in systemic lupus erythematosus. This was not, however, explored in our patients.

Thromboembolic disease is a well recognised cause of pulmonary hypertension, but recurrent small thromboemboli or in situ thrombosis may be easily overlooked clinically. A hypercoagulable state is occasionally seen in systemic lupus erythematosus and has been associated with the presence of a lupus anticoagulant, which has been found in up to 23% of patients with the disease.³ This antibody, which may be detected in either the IgG or IgM fraction of the serum, paradoxically prolongs kaolin partial thromboplastin time in vitro. It has also been associated with an increased risk of spontaneous abortion, thrombocytopenia, cerebral lupus, and a biological false positive result on testing for syphilis.⁴ Lupus anticoagulant was detected in five of our six patients (table), two of whom had a history of venous thrombosis. The remaining patient was immunosuppressed, and this might have accounted for the negative test result. It is interesting to speculate on the possible pathogenetic role of this anticoagulant in view of its association with thrombosis, and to suggest that its presence may perhaps be related to the development of intrapulmonary microthrombosis with consequent pulmonary hypertension. Twenty years ago Sleeper *et al*⁵ noted that, of their series of 10 patients with primary pulmonary hypertension, three had false positive serological reactions to tests for syphilis, and this perhaps may have indicated the presence of lupus anticoagulant. Studies of this association are now in progress.

We are grateful to Dr D D Gibbs, The London Hospital, for permission to report on one of his patients.

¹ Kramer N, Perez H. Pulmonary hypertension in systemic lupus erythematosus: report of four cases and review of literature. *Semin Arthritis Rheum* 1981;11:177-81.

² Walcott G, Burchell HB, Brown AL. Primary pulmonary hypertension. *Am J Med* 1970;39:70-9.

³ Mueh JR, Kenneth D, Herbst MD, Rapaport SI. Thrombosis in patients with the lupus anticoagulant. *Ann Intern Med* 1980;92:156-9.

⁴ Byron MA. The clotting defect in systemic lupus erythematosus. In: Hughes GRV, ed. *Clinics in rheumatic diseases*. Vol 8. No 1. Philadelphia: WB Saunders, 1982:137-51.

⁵ Sleeper JC, Orgain ES, McIntosh HD. Primary pulmonary hypertension: review of clinical features and pathologic physiology with a report of pulmonary haemodynamics derived from repeated catheterisation. *Circulation* 1962;26:1358.

(Accepted 27 June 1983)

Royal Postgraduate Medical School, Hammersmith Hospital, London W12 9HS

R A ASHERSON, MB, FCP(SA), visiting colleague
 C G MACKWORTH-YOUNG, MA, MRCP, registrar
 M L BOEY, MMED, honorary research fellow
 R G HULL, MB, MRCP, research fellow
 A SAUNDERS, MB, BS, senior house officer
 A E GHARAVI, MD, research fellow
 G R V HUGHES, MD, FRCP, consultant physician

Correspondence to: Dr G R V Hughes, Rheumatology Unit, Hammersmith Hospital, London W12 9HS.

Pregnancy complicated by gestational trophoblastic disease in a renal transplant recipient

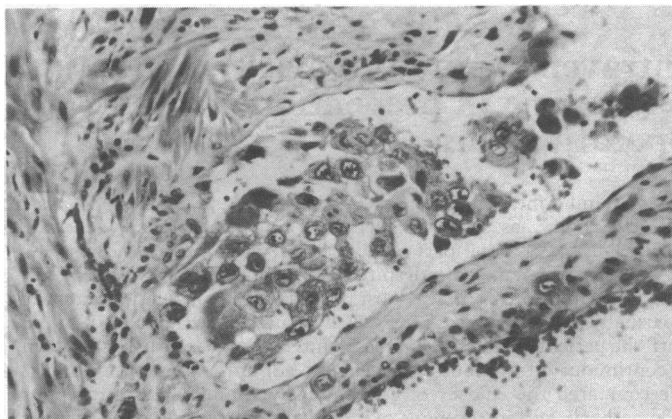
Fertility may return after renal transplantation. Several normal and abnormal pregnancies have been reported.¹ We can find no report of gestational trophoblastic disease arising de novo in a pregnant renal transplant recipient and therefore describe such a case.

Case report

A 22 year old woman developed hypertension and uraemia from presumed chronic pyelonephritis in 1979. There was no evidence of autoimmune disease. She was maintained with haemodialysis until May 1981, when she received a cadaveric renal transplant. Immunosuppressive treatment was given as prednisolone and azathioprine. Four rejection episodes were each treated with high dose pulses of methylprednisolone, and after the third episode continuous low dose cyclophosphamide (30 mg daily) was added for three months. Six months after transplantation her serum creatinine concentration was 110 μ mol/l (1.2 mg/100 ml).

Eleven months after transplantation, and after two months of amenorrhoea, she aborted spontaneously a hydatidiform mole. Despite uterine curettage on three subsequent occasions, serum chorionic gonadotrophin concentrations remained raised (up to 100 000 IU/l). There was no evidence of extra-uterine trophoblastic disease. She was referred for cytotoxic chemotherapy. During the first course of low dose methotrexate she developed acute abdominal pain, paralytic ileus, and became shocked. Emergency laparotomy showed rupture of the uterus, and a total abdominal hysterectomy was performed. Serum chorionic gonadotrophin values rapidly returned to normal postoperatively and remained so.

Gross examination of the specimen showed a fundal mass with an overlying tear. Histological study showed villi with pronounced trophoblastic proliferation. There was invasion of the uterine muscle and extensive permeation of vessels (figure) by atypical trophoblast. There were features of an invasive mole with possible incipient evolution into choriocarcinoma.



Uterine vein invaded by atypical trophoblast cells. Haematoxylin and eosin \times 215 (original magnification).

Comment

Patients with renal transplants have an increased incidence of malignant disease.² A proposed reactivation of latent choriocarcinoma has been described after renal transplantation,³ as has transmission of choriocarcinoma with the cadaver kidney,⁴ but no gestational trophoblastic disease arising de novo in a pregnant transplant recipient has been noted.

Gestational trophoblastic disease has a range of malignant potential from hydatidiform mole and invasive mole to choriocarcinoma. The clinical course is determined by factors such as the inherent malignant potential of the trophoblastic tumour and the immunological host response.⁵

In 80% of cases of classic hydatidiform mole human chorionic gonadotrophin concentrations become normal within 60 days of removal of the tumour, reflecting effective host immunological rejection mechanisms.⁶ The trophoblastic disease in our patient increased in malignant potential from the initial hydatidiform mole. It may be postulated that transformation occurred because of immunosuppression of the host, induced to prevent rejection of the transplanted kidney.