

and still be labelled "approximately 141 mmol/l" and comply with the BPC standard. Another variant of Difusor is stated to contain approximately 130 mmol/l of sodium, and a 5% variation would allow a range of 123.5 to 136.5 mmol/l.

The BPC limits for sodium content of haemodialysis solutions are $\pm 3\%$, and the manufacturers of our haemodialysis solutions work to limits of ± 3 mmol/l, which is equivalent to 2.16% on a sodium content of 139 mmol/l. We appreciate the difficulties encountered in manufacturing to narrow limits and possible problems with moisture loss on storage but think that a variation of 5% on the sodium content of peritoneal dialysis fluid is too wide. We would suggest that the *British Pharmaceutical Codex* limits be reduced to ± 3 mmol/l.

¹ Swales, J D, *British Medical Journal*, 1967, 3, 345.

(Accepted 20 March 1979)

Whipton Hospital, Exeter EX1 3RB

P G BISSON, MB, CHB, deputy director, renal failure, dialysis, and transplant unit

K M BAILEY, BSC, MPS, research pharmacist

Sicca syndrome associated with idiopathic haemochromatosis

The sicca syndrome in association with idiopathic haemochromatosis has not been reported. In the case described here bromhexine produced rapid objective as well as symptomatic improvement.

Case report

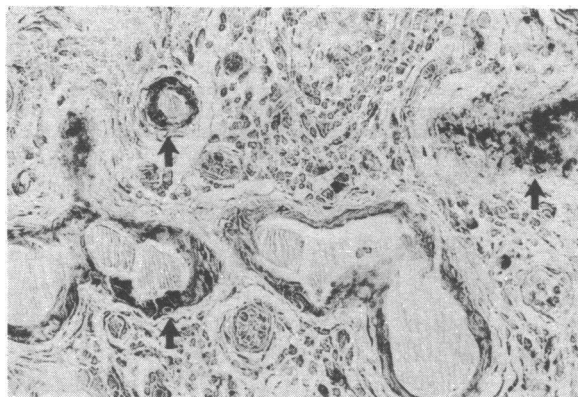
A 57-year-old housewife had complained of lethargy, dry mouth and eyes, dysphagia, and vague aches and pains in the extremities for about seven years. She had lost 12 kg in weight in four years. The menopause had occurred at the age of 49 years. Alcohol intake had been minimal and she had had no regular medication. She was admitted to hospital for further assessment after she developed congestive cardiac failure.

On examination she was wasted (weight 53 kg) and pigmented, with dry skin and mucous membranes and brittle nails. There was no adenopathy or salivary gland enlargement. The only abnormal clinical signs were a forceful, prominent left ventricular impulse, a fourth heart sound, and hepatomegaly. The liver edge was firm, slightly tender, and palpable 5 cm below the right costal margin. Investigations confirmed idiopathic haemochromatosis with hepatic, cardiac, and pancreatic involvement. Serum iron concentration was 33.5 $\mu\text{mol/l}$ (187.3 $\mu\text{g}/100$ ml), with 78% saturation, and serum ferritin concentration 5000 $\mu\text{g}/\text{l}$. Apart from minor abnormalities in liver function tests, the results of other relevant laboratory investigations were normal. Liver biopsy showed cirrhotic change with heavy iron deposition in hepatic cells, macrophages, and bile duct epithelium. ECG showed sinus rhythm and low voltage standard leads with T wave inversion in leads V2-V5. Diabetes mellitus was confirmed and satisfactorily controlled with carbohydrate restriction and 5 mg glibenclamide each morning. The results of lachrymal and salivary gland function tests were: Schirmer test nil (normal > 10 mm); resting mixed salivary flow rate 0.41 g/5 min (normal 1.35-9.4 g/5 min²); stimulated parotid flow rate 1.0 g/gland/10 min (normal > 5 g/gland/10 min²). A labial gland biopsy specimen showed glandular acini as well as ductal epithelium heavily stained with iron (figure). The most changed minor salivary glands showed complete loss of acini, striking dilatation of the ducts, mild lymphocytic infiltration in one or two areas, and replacement fibrosis where formerly there were acini. The histological changes were thought to result from the haemochromatosis.

The patient was given bromhexine 8 mg three times daily by mouth. She reported an improvement in her sicca symptoms within a matter of hours, and later commented that she had produced tears for the first time in several years. After six weeks the Schirmer test was 4 mm, the mixed salivary flow rate 0.60 g/5 min, and the stimulated parotid flow rate 2.06 g/gland/10 min.

Comment

Idiopathic haemochromatosis is an uncommon hereditary condition in which an excessive quantity of iron is absorbed and deposited in the tissues over many years. The presenting features are usually hepatic, pancreatic, or cardiac, with or without skin pigmentation. Functional impairment of the pituitary, adrenal, and testis is well recognised but impairment of salivary and lachrymal function does not seem to have been reported. Our patient's dry eyes and mouth



Haemosiderin deposits (arrows) in salivary duct epithelium. (Perl's stain. $\times 50$.)

suggested Sjögren's syndrome, but the histological changes were consistent with heavy iron deposition secondary to idiopathic haemochromatosis. Bromhexine increases sputum volume and decreases viscosity in some patients with chronic bronchitis by, it is suggested, increasing lysosome activity and increasing secretion of enzymes capable of hydrolysing the mucopolysaccharide fibril structure of mucus.³ Frost-Larsen *et al*⁴ recommended it for the lachrymal symptoms of Sjögren's syndrome. Xerostomia did not appear to be improved but objective tests of salivary function were not carried out. Our patient's rapid symptomatic improvement in both lachrymal and salivary function was later objectively confirmed.

¹ Adams, D, PHD Thesis, University Hospital of Wales, 1973.

² Mason, D K, *et al*, *Annals of the Rheumatic Diseases*, 1967, 26, 311.

³ *Drug and Therapeutics Bulletin*, 1971, 9, 91.

⁴ Frost-Larsen, K, Isager, H, and Manthorpe, R, *British Medical Journal*, 1978, 1, 1579.

(Accepted 23 March 1979)

University Hospital of Wales, Heath Park, Cardiff

R L BLANDFORD, MRCP, registrar

J R DOWDLE, MRCP, senior registrar

M R STEPHENS, MD, MRCP, consultant cardiologist

D M WALKER, MD, FDSRCS, senior lecturer in oral medicine

Incidence of nausea and vomiting with cytotoxic chemotherapy: a prospective randomised trial of antiemetics

Toxic side effects, particularly nausea and vomiting, of chemotherapy for malignant disease are distressing and may cause patients to refuse treatment. Surprisingly, therefore, little is known about the pattern of these symptoms and the efficacy of antiemetic treatment.¹

This study aimed at defining the incidence, severity, and duration of nausea and vomiting in patients receiving chemotherapy and to evaluate antiemetic preparations.

Patients, methods, and results

The patients studied were women with stage II breast cancer receiving adjuvant cyclophosphamide (300 mg/m²), methotrexate (40 mg/m²), and 5-fluorouracil (600 mg/m²) by intravenous bolus injection as outpatients. They were randomly allocated to receive one of the following preparations starting two hours before the chemotherapy and continuing for five days. (1) a placebo (ascorbic acid 50 mg thrice daily); (2) metoclopramide 10 mg thrice daily; (3) cyclizine 50 mg thrice daily; (4) fluphenazine 2 mg daily; or (5) fluphenazine 1.5 mg and nortriptyline 30 mg daily. The incidence, severity, and duration of nausea and vomiting were recorded at 12-hour intervals for five days by a self-administered questionnaire.

Nausea and vomiting in patients receiving the placebo occurred in 19

(83%) and 18 (78%) respectively of 23 assessments (figure). Nausea was severe in 15 (65%) and vomiting severe in 12 (52%). Both were maximal between 12 and 36 hours after injection. Vomiting decreased rapidly after 36 hours but nausea persisted for several days. Expressing the duration of nausea and vomiting in terms of days free of symptoms, 47 out of 115 days (41%) were free of nausea and 84.5 days (74%) free of vomiting. Metoclopramide, cyclizine, and fluphenazine failed to alter significantly the incidence, severity, or duration of nausea and vomiting. Nausea occurred in 10 (53%)

of 19 assessments of the fluphenazine and nortriptyline combination; vomiting occurred in 9 (47%). Severe nausea developed in only 4 (21%; $P < 0.01$); severe vomiting occurred in only two (11%; $P < 0.01$). The combination of fluphenazine and nortriptyline produced a highly significant reduction in the duration of both nausea and vomiting. Seventy out of 95 days (74%) were free of nausea ($P < 0.0005$) and 85.5 days (90%) free of vomiting ($P < 0.005$).

Discussion

The results of this study illustrate the extent of nausea and vomiting associated with a commonly used chemotherapeutic regimen. Gastrointestinal upset occurred in 83% of patients. Vomiting seldom persisted beyond 48 hours but nausea often continued for several days. Therefore there is an overwhelming need for effective antiemetic drugs. Our results confirm that neither metoclopramide nor cyclizine significantly influences the incidence and severity of nausea and vomiting.^{2,3} Phenothiazines are effective in controlling symptoms after radiotherapy³ and single-agent chemotherapy² but in our study, after multiple drug chemotherapy, fluphenazine alone was ineffective. In contrast, fluphenazine and nortriptyline combined significantly reduced the severity and duration of nausea and vomiting; the incidence was also reduced. Why this combination should be effective is not clear, but its effectiveness may be related to the relief of psychiatric morbidity which is common in patients receiving chemotherapy for breast cancer.⁴ Other drugs that influence mood have similar antiemetic effects.⁵ Nausea and vomiting are major limiting factors in the use of chemotherapy. We are continuing to study antiemetic drugs.

¹ Whitehead, V M, *New England Journal of Medicine*, 1975, **293**, 199.

² Moertel, C G, and Reitemeier, R J, *Gastroenterology*, 1969, **57**, 262.

³ Stoll, B A, *British Medical Journal*, 1962, **2**, 507.

⁴ Cooper, A F, et al, *British Journal of Surgery*. In press.

⁵ Sallan, S E, Zinberg, N E, and Frei, E, *New England Journal of Medicine*, 1975, **293**, 795.

(Accepted 13 March 1979)

Victoria Infirmary, Glasgow G42 9TY

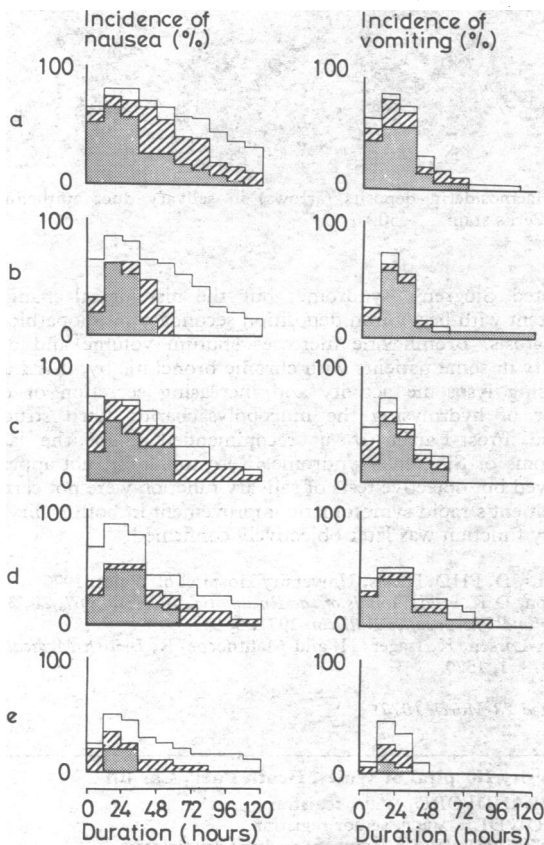
C MORRAN, MB, FRCS, surgical registrar
D C SMITH, MB, FRCS, consultant surgeon

Royal Infirmary, Edinburgh EH3 9YW

D A ANDERSON, MSc, MPh, principal pharmacist, drug information

Royal Infirmary, Glasgow G4 0SF

C S McARDLE, MD, FRCS, consultant surgeon



Incidence of nausea and vomiting. Mild □. Moderate ▨. Severe ■. (a) Placebo. (b) Metoclopramide. (c) Cyclizine. (d) Fluphenazine. (e) Fluphenazine and nortriptyline.

ONE HUNDRED YEARS AGO At the meeting of the Association of German Surgeons on April 16th, Herr Israel of Berlin showed a woman on whom he had operated successfully for echinococcus of the convexity of the liver. An operation by way of the abdomen was not possible, as the affected portion of the liver lay quite behind the wall of the chest. A portion of the sixth rib was excised, and the pleural cavity was opened under carbolic spray; the wound in the pleura was plugged with carbolised gauze, in order to produce adhesion between the wall of the chest and the diaphragm, which was much pushed up. Seven days later, the diaphragm was divided and the peritoneal cavity opened. The incision in the diaphragm was plugged with antiseptic gauze, in order to set up adhesions between the diaphragm and liver. This was effected in nine days; the liver was then incised, and the hydatids removed. The cavity in the liver was drained by a silver tube introduced through the opening in the chest. Recovery took place in nine-and-a-half weeks, without trace of pleurisy or of peritonitis; the sac of connective tissue being thrown off from the liver. At the same meeting, Herr Genzmer of Halle related a case of hydatid of the liver, also treated successfully in a similar manner. The hydatid had been punctured, and the contents had become ichorous; on account of its situation, it could not be reached through the abdomen. The operation differed from that of Dr. Istael in that it was performed in one stage, the liver being adherent to the diaphragm. The ichorous matter which escaped into the pleura when the sac was excised, was well washed out with salicylic acid. The course of the case was aseptic, and the patient was convalescent in eighteen weeks. (*British Medical Journal*, 1879.)

ONE HUNDRED YEARS AGO Dr Hedinger of Stuttgart has invented an apparatus for the purpose of illuminating the cavities of the body, especially those of the larynx, nose, and ear. It consists of a semiglobular convex mirror, made of finely polished silver, and having a platinum wire fixed to its focus. The wire is connected with a modified Bunsen's chromic acid battery, and can be heated to white heat. In cases where it is necessary to explore the larynx and nasal cavity, a plane mirror can be fastened to the concave one by means of a copper wire, so that it can be turned in all directions. In illuminating the ear or the nose, Dr Hedinger uses a concave mirror, which is perforated in its centre. The platinum wire is fixed a little athwart the latter, so as to allow the eye to look through the hole unimpeded. The author has tried the mirror both on himself and on several patients, and has never experienced the slightest inconvenience from the temperature of the wire. (*British Medical Journal*, 1879.)

Correction

Diabetes after infectious hepatitis

In the article by Dr J M Oli and Professor C Nwoko (7 April, p 926) the first sentence under Patients and Methods should have read: "Out of 119 patients who had infectious hepatitis during an epidemic in Eastern Nigeria 1970-72, 11 developed polyuria and glycosuria and were followed up between 1970 and 1978 either at a diabetic clinic or by special invitation to this hospital."