

PAPERS AND ORIGINALS

Antibiotic prophylaxis in total hip replacement

J P POLLARD, S P F HUGHES, J E SCOTT, M J EVANS, M K D BENSON

British Medical Journal, 1979, 1, 707-709

Summary and conclusions

A controlled prospective trial to compare the efficacy of the antibiotics cephaloridine and flucloxacillin in preventing infection after total hip replacement was conducted at three hospitals. The antibiotic regimens began before surgery, cephaloridine being continued for 12 hours and flucloxacillin for 14 days afterwards. Over an 18-month period 297 patients undergoing a total of 310 hip replacements were entered into the trial and randomly allocated to one of the regimens. The follow-up period ranged from one to two and a half years. All operations were performed in conventional operating theatres; at two of the hospitals these were also used by various other surgical disciplines. Four patients developed deep infection, two having received the cephaloridine and two the flucloxacillin regimen. The overall rate of deep infection was therefore 1.3%.

Thus three doses of cephaloridine proved to be as effective as a two-week regimen of flucloxacillin. Giving a prophylactic systemic antibiotic reduced the incidence of infection to a level comparable with that obtained in ultra-clean-air operating enclosures.

Introduction

Earlier reports have shown a high incidence of deep wound infection after total hip replacement.¹⁻³ Charnley⁴ reported an

infection rate of under 1% when ultra-clean-air operating enclosures were used. Such facilities, however, are not widely available. Another method is to attempt to reduce infection by using prophylactic antibiotics given systemically, applied locally to the wound, or introduced into the cement. We consider here the systemic use of prophylactic antibiotics. Ericson⁵ showed that cloxacillin given systemically with premedication and continued for 14 days is effective in preventing infection after total hip replacement. Flucloxacillin is recognised as a preferred alternative to cloxacillin in view of its superior absorption from the gastrointestinal tract.⁶ Cephaloridine given as three injections of 1 g, starting when anaesthesia is induced and repeated after six and 12 hours, reduces the rate of wound infection after various surgical procedures.⁷⁻⁹ Four injections of 1 g of cephaloridine are also effective in clean orthopaedic surgery.¹⁰ We have previously carried out a study using the 3-g cephaloridine regimen in patients undergoing total hip replacement, in which therapeutic concentrations were achieved in the bone capsule and the synovial fluid at the time of operation; in a one-year follow-up of these patients no infection occurred.^{11,12} A proportion of the bacteria isolated from infected hips are reported to be Gram-negative bacilli.^{1,13,14}

We specifically selected the broad-spectrum bacterial antibiotic cephaloridine for comparison with the narrow-spectrum bactericidal flucloxacillin to ascertain whether the spectrum of antibacterial activity affected the incidence of infection and the organisms that were isolated. We undertook a controlled prospective trial to study the efficacy of the two antibiotics in preventing infection after total hip replacement. As the operations were mostly performed in operating theatres in which the incidence of deep infection after total hip replacement was known to be high,¹ we felt that it was unethical to include an untreated control group.

Patients and methods

Patients were randomly allocated to either the cephaloridine or the flucloxacillin regimen. Only those with a history of hypersensitivity to cephalosporins or penicillins or with an appreciable degree of renal impairment were excluded. Those allocated to the cephaloridine regimen received 1 g intravenously when anaesthesia was induced and two intramuscular doses of 1 g six and 12 hours later. Those allocated to the flucloxacillin regimen received 500 mg intramuscularly with the premedication one hour before surgery and then 500 mg four times

The Middlesex Hospital, London W1

J P POLLARD, FRCS, senior orthopaedic registrar

S P F HUGHES, MS, FRCS, consultant orthopaedic surgeon (present address: Hammersmith Hospital and Royal Postgraduate Medical School, London W12 0HS)

J E SCOTT, FRCS, consultant orthopaedic surgeon (present address: St Stephen's Hospital, Chelsea)

M J EVANS, FRCS, consultant orthopaedic surgeon (present address: Hammersmith Hospital and Royal Postgraduate Medical School, London W12 0HS)

M K D BENSON, FRCS, consultant orthopaedic surgeon (present address: Nuffield Orthopaedic Hospital, Oxford)

daily for 14 days; for the first 24 hours the flucloxacillin was given intramuscularly, but subsequently it was taken by mouth.

The operations were performed in the main operating theatres of the Middlesex Hospital and King Edward VII's Hospital for Officers, and in the orthopaedic theatre of the Central Middlesex Hospital. The former theatres are used for various surgical procedures, and the latter is reserved for clean orthopaedic procedures. In each case the ventilation system has a turbulent rather than a laminar air flow. The systems are designed to give a maximum of 15 air changes per hour in the Middlesex Hospital and 20 changes per hour in the Central Middlesex and King Edward VII's hospitals. There is full thermostatic control at the Middlesex and King Edward VII's hospitals, while the Central Middlesex lacks a cooling system.

After the operation the patients were carefully monitored for infections, the wounds being inspected at regular intervals and at other times when the clinical condition indicated. Infections were classified as superficial or deep. Superficial infections were considered to be minor when there was a purulent discharge without pyrexia, moderate when there was a discharge accompanied by pyrexia, and severe when there was a major wound dehiscence. Deep infection was considered to be either early or late—early when it occurred before six months and late thereafter. Early infection was diagnosed by the presence of pain, fever, redness of the wound, and a discharge containing pathogenic organisms or many polymorphonuclear leucocytes. Late infection was diagnosed by the presence of two or more of the following criteria: pain in the hip; a discharging sinus; isolation of pathogenic organisms from a sinus or by direct aspiration; isolation of material from which no organisms could be cultured and which contained many polymorphonuclear leucocytes; an erythrocyte sedimentation rate (ESR) that was raised above the preoperative level by 30 mm or more in the first hour; or radiological evidence of infection such as periosteal reaction, bone reabsorption, or irregular reabsorption of the calcar. Follow-up was continued for a minimum of 12 months.

Results

During the 18 months from January 1976 to June 1977, 310 total hip replacements were performed on 297 patients in the trial, as there were 13 bilateral cases. Five patients died within 12 months after surgery, and two were lost to follow-up. These seven patients were therefore excluded from the trial, leaving 290 patients who underwent 303 total hip replacements. A total of 157 patients received flucloxacillin and 146 cephaloridine prophylaxis. Of the 303 operations, 178 were performed on women and 125 on men. Fifty-three of the patients were aged between 50 and 59 years, 133 between 60 and 69 years, 103 between 70 and 79 years, and the remaining 14 under 50 years.

The indications for surgery were osteoarthritis in 270 cases and rheumatoid arthritis in 23 cases, while nine operations were for sequelae of fractures and one for avascular necrosis of the femoral head. A total of 279 operations were primary, while the remaining 24 were secondary or subsequent procedures. Nine of these 24 followed subcapital fractures, of which four were treated initially by internal fixation and five by hemiarthroplasty; six followed intertrochanteric osteotomy; four were performed on failed total hip replacements; two were done for unsatisfactory arthrodesis; and the remaining three followed an unsatisfactory Girdlestone pseudoarthrodesis, an arthrotomy to remove loose bodies and osteophytes, and a Smith-Petersen cup arthroplasty. We used an anterolateral approach in all cases and carried out 248 Muller, 41 Howse, 13 Stanmore, and 1 Charnley arthroplasties. The duration of the operation was recorded from skin incision to skin closure: 79 were accomplished in under one hour, 218 in one to two hours, and only six took over two hours. In 161 patients a vacuum drain was used for 48 hours after the operation, and in 142 no drain was used. In addition, 96 of the 310 patients received prophylactic low-dose heparin treatment.

Four patients developed deep infection and five superficial infection. All of the superficial infections were minor and healed without evidence of deep infection. The table lists the organisms isolated from these nine patients. The case histories of the four patients with deep infection were as follows.

Case 1—A man aged 72 underwent a primary Muller total hip replacement in July 1976 for osteoarthritis and received cephaloridine prophylaxis. He made an uneventful recovery until two months after the operation, when the hip became painful. The ESR was 55 mm in the first hour compared with 14 mm in the first hour before surgery. A course of flucloxacillin was started, but his symptoms continued and radiological examination disclosed periosteal reaction over the lateral aspect of the femoral shaft. The hip was explored six months after surgery, and a small amount of pus was found around the

Organisms isolated from five patients with superficial infections and four with deep infections, and prophylactic antibiotics used

Organisms isolated	Superficial infection		Deep infection	
	No	Prophylactic antibiotic used	No	Prophylactic antibiotic used
<i>Staphylococcus aureus</i>	1	Cephaloridine	1	Cephaloridine
<i>Staphylococcus epidermidis</i>	1	Flucloxacillin	1	Flucloxacillin
<i>Streptococcus faecalis</i>	1	Flucloxacillin	1	Cephaloridine
Coliforms	3	2 Flucloxacillin, 1 cephaloridine	1	Cephaloridine
Anaerobic diphtheroids	1	Flucloxacillin
Totals	5	..	4	..

femoral neck. Culture of this pus showed a coliform that was resistant to cephaloridine and flucloxacillin. A new long-stem Muller prosthesis was inserted using cephaloridine in the cement. This prosthesis also became infected, however, and was finally removed.

Case 2—A woman aged 46 underwent a primary Muller total hip replacement for osteoarthritis of the hip in September 1976. In childhood she had sustained a slipped upper femoral epiphysis on that hip, which had not been treated surgically. She received flucloxacillin prophylaxis. She progressed well for four months after surgery and then developed pain radiating from the hip to the thigh. Her ESR was raised to 40 mm in the first hour, and radiological examination suggested an area of osteomyelitis in the mid-shaft of the femur (fig 1).

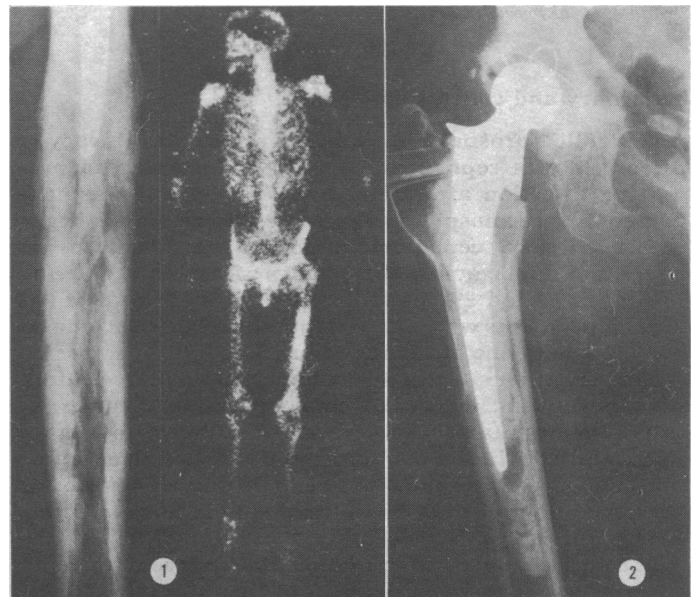


FIG 1—Case 2. Left: radiological changes suggesting osteomyelitis in mid-shaft of femur. Right: technetium diphosphonate bone scan showing increased uptake in the same area. FIG 2—Case 4. Resorption at bone-cement interface of the femoral component.

A bone scan using technetium diphosphonate showed an extensive area of abnormal uptake in the same area. The symptoms continued despite a course of flucloxacillin and sodium fusidate (Fucidin), and eight months after surgery the mid-shaft of the femur was explored without disturbing the prosthesis. No gross evidence of infection was found, but an anaerobic diphtheroid was grown from the bone specimens and a swab taken at that time. This organism was sensitive to penicillin and sodium fusidate but was not tested against flucloxacillin, although it is usually resistant to this. She is now free of pain, with the prosthesis in situ, and is taking a long-term course of sodium fusidate and flucloxacillin. Her ESR has dropped to 24 mm in the first hour.

Case 3—A primary Howse total hip replacement was performed on a man aged 73 for osteoarthritis in October 1976. He received cephaloridine prophylaxis. Immediately postoperatively he made good progress, but he developed increasing pain after four weeks. The wound discharged copious pus for six weeks, and *Staphylococcus*

aureus was grown. This was sensitive to flucloxacillin and cephaloridine. The patient was given a long-term course of flucloxacillin, and so far it has not been necessary to remove the prosthesis as he has had no further pain despite an intermittent discharge from the sinus.

Case 4—A woman aged 64 underwent a right Howse total hip replacement in September 1976. At the same operation the Muller-Harris spine that had been inserted nine years previously for osteoarthritis was removed. She was given flucloxacillin prophylactically. Four months later she developed right hip pain, which was aggravated by walking. Her ESR was raised to 44 mm in the first hour compared with a preoperative level of 12 mm in the first hour. Serial radiological examination showed increasing rarefaction at the bone-cement interface of the femoral component (fig 2). Her symptoms deteriorated in spite of a course of antibiotic treatment, and after 16 months the hip was explored. A small amount of pus was found in the femoral shaft, and a culture of this showed a moderate growth of *S epidermidis*, which was resistant to flucloxacillin but was not tested against cephaloridine. A new prosthesis was inserted using chloramphenicol powder mixed in the cement, and this proved satisfactory.

Thus of the four patients who developed deep infection, all suffered from osteoarthritis and one (case 4) had undergone a previous osteotomy. The operations were all recorded as unremarkable, taking between one and two hours. In all four patients a suction drain was used postoperatively. Interestingly, no infections occurred in the 142 patients in whom no drain was used, though this was not statistically significant. One of the four patients (case 1) received prophylactic low-dose subcutaneous heparin treatment.

Five patients died within 12 months after the operation. Each had undergone a unilateral procedure and died from causes unrelated to the total hip replacement. At the time of death no evidence of hip infection was found. We calculated the expected mortality per thousand population per year for a sample of this size, age, and sex distribution from *Mortality Statistics 1975*.¹³ We found that the actual mortality was 5 and the expected mortality 9.44 per year.

Discussion

In this series, in which 303 total hip replacements were carried out, four patients developed deep infection. Thus the rate of deep infection was 1.3%, which compares favourably with rates in other series in which antibiotics have been given as prophylaxis.¹³ Importantly, this figure also compares well with rates obtained with the ultra-clean-air operating enclosure.⁴ All the four deep infections we encountered occurred within six months after operation and therefore were probably the result of infection at the time of surgery or shortly afterwards in the ward. The five cases of superficial wound infection did not progress to deep infection (table). The rate of superficial infection was thus 1.65%. We isolated both Gram-positive and Gram-negative organisms from the infected joints, which agrees with the findings of others.^{13 14} In case 2 an anaerobic diphtheroid was isolated from the mid-femoral shaft. Anaerobic organisms cause both infection in total joint replacement¹⁶ and osteomyelitis.^{17 18} We feel sure that *S epidermidis* is pathogenic in patients undergoing total joint replacement and that it is relevant that we isolated this organism from the femoral cavity in one patient (case 4).

In searching for an appropriate antibiotic to minimise these effects we chose a cephalosporin and compared it against an established antibiotic regimen. Interestingly, *S epidermidis* and a diphtheroid were cultured from the two patients who developed infection after two weeks of flucloxacillin, while *S aureus* and a coliform were cultured from the two patients who received the cephaloridine regimen, though the coliform was unfortunately not speciated. This suggests that the two-week prophylaxis may encourage infection from less virulent organisms while the short cephaloridine regimen is not wholly effective against more virulent organisms; the number of cases of infection is too small, however, to form a definite conclusion on this point. The simplicity of the 3-g cephaloridine regimen, however, is an advantage, and the drug enters tissues at the time of surgery in therapeutic concentrations.¹¹ Improved cephalosporins such as cefuroxime are now available, which are more stable to the β -lactamase produced by the Gram-negative organisms and the

penicillinase produced by staphylococci, and thus a short preoperative regimen using such a cephalosporin might be more beneficial.

In the continuing search for a method of reducing the incidence of infection after total joint replacement our results have provided two conclusions. Firstly, a regimen of three doses of cephaloridine is just as effective as one of two weeks of flucloxacillin but seems to produce a different pathogenic flora; the cephaloridine regimen, however, is simpler to give. Secondly, when conventional operating theatres are used, giving a prophylactic systemic antibiotic can reduce the incidence of infection to a level that is comparable with that produced by the ultra-clean air systems, thus avoiding the inconvenience and expense of these systems.

We should like to thank Mr Rodney Sweetnam, Mr Michael Edgar, Mr Justin Howse, and Mr William Taor for allowing us to study their patients, and Mrs Pauline Dodi for preparing the manuscript.

We are grateful to Dr Clive Dash, Glaxo Limited, for supplying us with the antibiotics and for his help and advice with this trial.

References

- Benson, M K D, and Hughes, S P F, *Acta Orthopaedica Scandinavica*, 1975, **46**, 968.
- Harris, J, Lightowler, C D R, and Todd, R C, *British Medical Journal*, 1972, **2**, 750.
- Patterson, F P, and Brown, C S, *Journal of Bone and Joint Surgery*, 1972, **54(A)**, 257.
- Charnley, J, *Clinical Orthopaedics and Related Research*, 1972, **87**, 167.
- Ericson, C, Lidgren, L, and Lindberg, L, *Journal of Bone and Joint Surgery*, 1973, **55(A)**, 808.
- Sutherland, R, Croydon, E A P, and Rolinson, G N, *British Medical Journal*, 1970, **4**, 455.
- Polk, H G, and Lopez-Mayor, J F, *Surgery*, 1969, **66**, 97.
- Evans, C, and Pollock, A V, *British Journal of Surgery*, 1973, **60**, 434.
- Suri, P K, and Johnson, D W B, *Canadian Journal of Surgery*, 1975, **18**, 361.
- Pavel, A, *et al*, *Journal of Bone and Joint Surgery*, 1974, **56(A)**, 777.
- Hughes, S P F, *et al*, *Journal of Antimicrobial Chemotherapy*, 1975, **1**, suppl No 3, p 41.
- Hughes, S P F, *et al*, *Journal of the Royal College of Surgeons of Edinburgh*, 1978, **23**, 9.
- Fitzgerald, R H, *et al*, *Journal of Bone and Joint Surgery*, 1973, **55(A)**, 1242.
- Hunter, G, and Dandy, D, *Journal of Bone and Joint Surgery*, 1977, **58(A)**, 731.
- Office of Population Censuses and Surveys, Series DHI No 2, *Mortality Statistics 1975*. London, HMSO, 1978.
- Kramme, C, *et al*, *Scandinavian Journal of Infectious Diseases*, 1974, **6**, 161.
- Finegold, S M, and Rosenblatt, J E, *Medicine*, 1973, **52**, 311.
- Kelly, P J, Wilkowske, C J, and Washington, J A, 2nd, *Clinical Orthopaedics and Related Research*, 1973, **96**, 70.

(Accepted 22 January 1979)

ONE HUNDRED YEARS AGO The following statement, published in the *Missionary Herald* of January 1879, the organ of the American Board of Commissioners for Foreign Missions, is believed to be altogether reliable.

"Can the victim of opium-smoking be cured? It is commonly believed that, so terrible is his appetite, he is beyond help and hope. The asylum at Foochow has demonstrated the falsity of this assertion. Connected with the hospital of our mission, under charge of Dr Osgood, there is a separate building for the treatment of opium-smokers, where about sixty patients are received each month. In response to an inquiry as to the method of treatment, Dr Osgood sends the following account of his practice for the last two years, during which time about eight hundred cases have been successfully treated. '1. The total and absolute discontinuance of the use of opium from the beginning of treatment. 2. A trusty attendant to be with the patient day and night for the first three days. 3. Chloral-hydrate for the first three nights, if required. 4. Good food, milk, raw eggs, brandy (in some cases), chicken-broth. (The above is taken in small quantities and frequently.) 5. In diarrhoea, give two drachm doses of a mixture of equal parts of tincture of catechu and tincture of ginger.'" (*British Medical Journal*, 1879.)