

# Methylmercury poisoning in Iraqi children: clinical observations over two years

L AMIN-ZAKI, M A MAJEED, T W CLARKSON, M R GREENWOOD

*British Medical Journal*, 1978, 1, 613-616

## Summary and conclusions

The clinical features of 49 children who had eaten bread contaminated with methylmercury in rural Iraq were reviewed. Symptoms and signs relating to the nervous system—varying degrees of ataxia, weakness, and visual and sensory changes—dominated the clinical picture. The severity of poisoning was related to the blood mercury concentration, as was the degree of recovery. Follow-up over two years showed that children who had had mild or moderate poisoning slowly but steadily improved, some of them recovering normal function, though all had a residual generalised hyperreflexia. In some patients ataxia and motor weakness disappeared. Visual changes also improved, though less completely, and of 17 blind children, only five had recovered partial sight by the end of two years. Seven of the 18 children who suffered very severe poisoning were left physically and mentally incapacitated.

The degree of clinical progress shown by these children was better than that shown by some other groups of patients, possibly because the poisoning was relatively acute and mercury consumption was stopped immediately after its effects had become obvious.

## Introduction

Methylmercury compounds are highly neurotoxic. They are readily absorbed, slowly metabolised, and pass the blood-brain barrier easily.<sup>1</sup> Several sporadic incidents<sup>2,3</sup> and large epidemics<sup>4-8</sup> of methylmercury poisoning have been reported. One such outbreak occurred in rural Iraq in the winter of 1971-2, when Iraqi farmers used a mercury-treated seed grain to make bread.<sup>9</sup> Analysis of the flour used gave an estimated amount of 1.4 mg of mercury per loaf of bread.<sup>9</sup> The bread was eaten over two weeks to two months. Many of the victims of this disaster were children.

We were actively engaged in the management of these patients both in hospital and in their rural homes and had the opportunity to study the clinical manifestations. We describe here the clinical picture at the outset of the disease and the clinical progress over two years in the children who were old enough to have eaten the bread themselves. We have not included infants who were exposed in utero or through their mother's milk.

### Department of Paediatrics, Medical College, University of Baghdad, Iraq

LAMAN AMIN-ZAKI, DCH, MRCP, professor and chairman, department of paediatrics

MUHAMMAD A MAJEED, MB, CHB, DCH

### Environmental Health Sciences Centre, University of Rochester Medical Centre, Rochester, New York 14642, USA

THOMAS W CLARKSON, BSC, PHD, professor of radiation biology and biophysics and of pharmacology and toxicology

MICHAEL R GREENWOOD, BSC, MSc, instructor and assistant lecturer in radiation biology and biophysics and in environmental studies

## Patients and methods

Forty-nine children, all of whom had eaten homemade bread prepared from grain treated with a methylmercury compound, were included. All belonged to families whose members were affected by severe poisoning and who reported to the hospital asking for help. Their age and sex distributions are shown in table I. The children were admitted to hospital for periods of six to 12 months. After discharge they were visited in their homes at least once every six months and their progress was evaluated by standard clinical and neurological tests. Because of the youth of most of the patients the examination often had to be limited to basic neurological tests, and such sensory tests as the tuning fork test, two-point discrimination, and hot and cold discrimination were omitted. Visual changes were evaluated by a consultant ophthalmologist and hearing changes by a consultant otolaryngologist.

TABLE I—Age and sex distribution in 49 children who were observed over two years

Age (years):	2-4	5-9	10-16	Total
With symptoms and signs:				
Boys	3	3	10	16
Girls	6	11	7	24
Without symptoms and signs:				
Boys		2	3	5
Girls	3		1	4

Blood samples were collected in heparinised vacuum containers to prevent coagulation and were refrigerated or kept on ice until assayed for mercury within 48 hours. Mercury concentrations were determined in the blood by selective cold vapour atomic absorption.<sup>10</sup>

## Results and comment

### SIGNS AND SYMPTOMS

*Onset*—As reported,<sup>9</sup> the first symptoms often did not appear until up to six weeks after the patient had stopped eating the contaminated bread. But 22 patients stopped eating the bread because of the appearance of the clinical manifestations. The onset was always gradual and the early signs consisted of malaise or a feeling of severe bodily discomfort without clear signs of a particular illness, often associated with headache and insomnia in children old enough to describe what they felt. Of the 49 patients admitted to the hospital, nine were asymptomatic. The incidence of symptoms and signs in the 40 patients with neurological manifestations is given in table II.

TABLE II—Prevalence of neurological manifestations in 40 children exposed to methylmercury. Manifestations were those observed shortly after admission to hospital

Neurological signs	No of patients
Ataxia . . . . .	22
Dysarthria . . . . .	34
Visual disturbance . . . . .	30
Hearing disturbance . . . . .	24
Sensory changes . . . . .	12
Weakness . . . . .	34
Hyperreflexia . . . . .	40
Babinski's sign . . . . .	18
Clonus . . . . .	4
Changes in muscle tone . . . . .	24
Incontinence . . . . .	13
Salivation . . . . .	10
Priapism . . . . .	4
Involuntary movements . . . . .	27

**Ataxia and dysarthria**—Ataxia was found in 22 out of the 40 children with symptoms. The remaining 18 were too severely affected or too young to perform the clinical tests, which included: the finger-nose test, walking on a straight line, and picking up and drinking from a glass of water. The ataxia varied in severity from clumsiness in the handling of objects to broad-based gait, staggering, falling, and inability to stand or even sit. Thirty-four of the children had speech disturbances, which varied from slow, slurred, and explosive speech to an inability to utter clear, comprehensible words.

**Visual and hearing disturbances**—Visual disturbances ranged from blurred or hazy vision through various degrees of constricted visual fields to complete blindness. In all cases the constriction of visual fields was bilateral. The patients themselves described their constricted fields of vision as being "like a horse with blinkers." Auditory disturbances varied from reduced hearing to complete deafness. No other lesion that might cause constriction of the visual fields or bilateral loss of hearing could be identified except exposure to methylmercury. Visual changes were found in 30 and auditory changes in 24 of the 40 children.

**Sensory changes**—On admission 14 children were too severely affected and eight children were too young to be able to give information about paraesthesiae. Of the remaining 18 children, 12 complained of numbness in the glove-and-stockings areas and four had perioral paraesthesia as well. Sensory changes were commonly associated with motor weakness so that the complaint was usually "a feeling of numbness and ants moving under the skin; my hands are weak and do not obey me to do my work." All 40 patients could feel pin pricks easily, including those with paraesthesia.

**Changes in motor power, muscle tone, and deep tendon reflexes**—Varying degrees of weakness were found in 34 patients; 18 patients suffered complete paralysis and helplessness. Muscle tone was increased in 21 children, decreased in three, and normal in 16. There was obvious muscle wasting in the 18 patients who were paralysed. Deep tendon reflexes were exaggerated in all patients and Babinski's sign was extensor in 18. Clonus was present in only four cases.

**Disturbances of autonomic nervous system**—Excessive salivation and drooling were found in 10 cases. Thirteen children who had previously had normal toilet habits had incontinence of urine and faeces. Priapism was found in four boys.

**Involuntary movements**—Twenty-seven children had involuntary movements. Coarse tremors that became more pronounced during voluntary movements were the most common finding. Twitching was also present in four children and myoclonic jerks in three. Athetotic movements were found in only two cases.

**Deaths**—Our policy was to keep a clear airway; maintain the patients' nutrition through nasogastric feeding and, when necessary, intravenous infusions; and treat promptly any intercurrent infections during the critical period. As a result none of the patients died during the period of observation.

#### CLINICAL SEVERITY

The severity of each patient's clinical disease was classified according to the following definitions adapted from Damluji (see table III).<sup>11</sup>

**Asymptomatic** children were free from any signs or symptoms on admission but had raised blood mercury concentrations. They were admitted with affected members of their families and were considered to be at risk.

**Mild** poisoning was present in six children who had no or very little impairment of physiological function. The findings were mainly subjective and included symptoms such as malaise, headache, insomnia,

paraesthesia, weakness, blurring of vision, and gastrointestinal disturbance. Hyperreflexia was present in all cases.

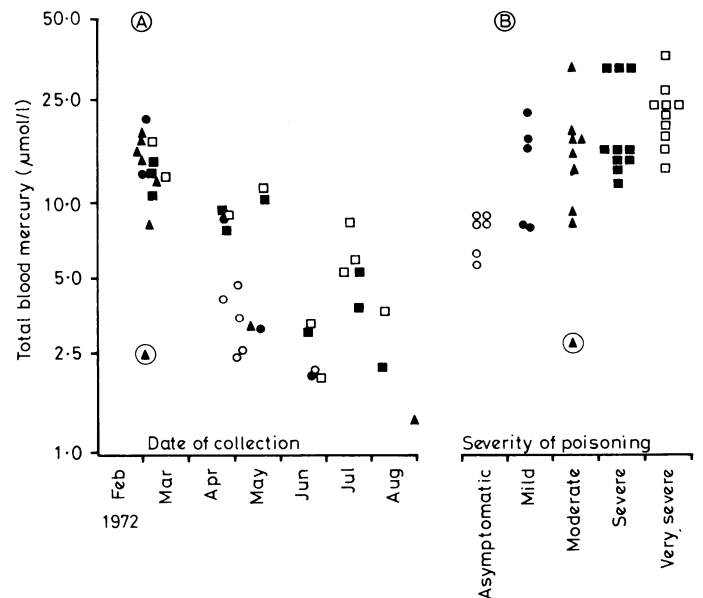
**Moderate** poisoning was present in 10 patients who had some impairment of physiological function. The most common findings, in addition to those seen in mild poisoning, were: ataxia elicited by tests such as the finger-nose test and walking on a straight line; mild dysarthria; paresis; tremor; and some visual and auditory impairment.

**Severe** poisoning affected 13 patients, who all had gross impairment of physiological function. The most common findings were stupor, gross ataxia, spastic paralysis, severe bilateral visual or auditory impairment, severe dysarthria, and incontinence.

**Very severe** poisoning affected 11 patients; all were physically and mentally incapacitated. The most common findings were blindness, deafness, decerebrate posture, bouts of severe excitement and crying, and spastic paralysis.

#### BLOOD MERCURY CONCENTRATION

The blood concentrations of total mercury at the time of admission to hospital are shown in the figure. There was no apparent relation between the severity of signs and symptoms and the mercury concentrations, but it was clear that blood concentrations were falling during this period (March to August 1972). This was to be expected. According to the clinical histories of the patients, the consumption of contaminated bread had stopped before admission to hospital. We therefore compared the severity of poisoning with the blood concentrations at a common point in time.



Total mercury concentrations in first sample of whole blood collected after admission. (A) Mercury concentrations plotted according to date of sample collection. (B) Mercury concentrations extrapolated to 1 March 1972 using half time of 73 days. Mercury values are grouped according to severity of poisoning.

○ = Asymptomatic. ● = Mild. ▲ = Moderate. ■ = Severe. □ = Very severe. The encircled triangle is a sample from a patient who had extensive exfoliative dermatitis in addition to other signs and symptoms of poisoning. This was an atypical case. Mercury concentrations in blood were not available for nine patients.

Conversion: SI to traditional units—Mercury: 1 µmol/l ≈ 201 ng/ml.

TABLE III—Clinical progress over two years according to severity of poisoning

Severity*	No of patients	Degree of improvement			Physical and mental incapacitation
		Recovery	Greatly improved, function good	Improved, function fair	
Mild	6	6			
Moderate	10	7	2	1	
Severe	13	1	4	8	
Very severe	11		1	3	7
Total	40	14	7	12	7

\*Nine were asymptomatic.

Enough blood samples were collected from 14 children to allow the biological half time to be estimated. The decline in blood concentration was exponential and could be adequately described by a single biological half time, as reported.<sup>9</sup> The average biological half time was 56 days (range 39 to 72 days). This did not differ significantly from an average biological half time of 65 days (range 45 to 105) reported in 16 adult Iraqi patients<sup>9</sup> and a value of 50 days computed for 16 volunteers who took tracer doses of radioactive methylmercury.<sup>12</sup> We decided to correct all the blood values shown in the figure (A) to 1 March 1972, the date when the first patients were admitted to the hospital. The individual's half time was used to make this correction for the 14 children whose half time was known and the average half

time of 56 days was used for the rest of the children. The corrected mercury concentrations are also shown in the figure, grouped according to the severity of poisoning.

The severity of the poisoning increased with increasing blood mercury concentrations. The asymptomatic group had significantly lower concentrations than the severe and very severe groups (Mann Whitney test:  $P < 0.01$ ). One-way analysis of variance<sup>13</sup> showed highly significant ( $P < 0.01$ ) differences between the mean concentrations of mercury in each clinical group, with the value increasing according to the severity of poisoning. The individual variation in mercury concentration in each group and the overlap between groups reflected both differences in individual sensitivity to methylmercury<sup>14</sup> and differences in biological half time.<sup>15</sup>

#### CLINICAL PROGRESS

Table III summarises the results of two years' follow-up. The degree of recovery was generally inversely related to the severity of signs and symptoms. Hyperreflexia with or without a bilaterally extensor Babinski's reflex remained in all patients, even after two years. Patients shown in the tables as having regained normal function did have hyperreflexia, but all coped well with their daily functions or school activities. All six children who had mild poisoning were normal at the end of one year. Seven of the 10 who had had moderate poisoning recovered normal function by the end of two years; two improved greatly and were able to work with residual sequelae such as constriction of visual fields, some slurring of speech, and a positive Babinski's sign; and one patient showed improvement but retained some muscle weakness, abnormal gait, and slurring of speech. Of the 13 patients who had had severe poisoning, one recovered her function, four showed great improvement, and eight (three of whom remained blind) improved slightly but did not regain full capacity to perform their previous activities. Of the 11 patients who had had very severe poisoning, none recovered; seven remained with physical and mental incapacity, and four showed some improvement. Table IV gives details of speech, ataxia, walking, and visual changes observed over two years.

TABLE IV—Clinical progress over two years according to selected signs and symptoms

	No of patients	One year later				Two years later			
		1*	2	3	Normal	1	2	3	Normal
<i>Speech</i>									
Slurred (1)*	13	2			11	2			11
Severely slurred (2)	8	5			3	4			4
Lost (3)	13	2			9	4	2	6	1
<i>Ataxia (tests)</i>									
Finger-nose (1)	22	10			12 <sup>†</sup>	8			14 <sup>§</sup>
Straight line (2)	21	10			11	8			13
Glass of water (3)	18		4		14		4		14
<i>Walking</i>									
Without support (1)	11	2			9	1			10
With support (2)	7	7				4			3
Bedridden (3)	18	9	1	8		9		7	2
<i>Vision</i>									
Blurred (1)	14				14				14
Constricted (2)	9		8		1		8		1
Blind (3)	17		5		12		5	12 <sup>‡</sup>	

\*Numbers used as column headings refer to same numbers after clinical finding in each row.

<sup>†</sup>12 out of 22 patients had normal results on all three tests.

<sup>‡</sup>Nine of these patients showed only perception of light.

<sup>§</sup>14 out of 22 patients had normal results on all three tests.

#### Discussion

Many workers have taken a pessimistic outlook towards patients with methylmercury poisoning, predicting either a fatal outcome or permanent and stable neurological damage.<sup>16-21</sup> In Japan most patients were permanently affected, and, once methylmercury exposure was stopped, their disease ran a progressive course. Harada<sup>22</sup> described 30 patients who had

developed infantile Minamata disease in 1953-9 after eating fish from Minamata Bay that had been contaminated with methylmercury compounds by industrial pollution. Ten of Harada's group died. Thus many of his patients were more severely affected than ours, and none were asymptomatic or had only mild poisoning. Of the 20 surviving patients, one showed no improvement, three were lost to follow-up, and 16 improved very slightly. In the original paper of Hunter *et al*<sup>2</sup> four older patients were reported, all of whom showed varying degrees of functional improvement, although "the actual neurological condition had improved little, if at all,"<sup>22</sup> and improvement was attributed to re-education and physical treatment. Two years after the exposure their patient who showed the most recovery retained many neurological deficits. He still had gross ataxia; his visual fields were unaltered; his speech was explosive, and he had fine tremor in the arms, head, and neck.

In Iraq the neurological symptoms and signs were grossly similar to those in Japan. But not only did we observe functional recovery but in many cases the neurological condition also improved. A preliminary report<sup>23</sup> indicated that improvement had already started in our cases by the end of 1972. Our two-year follow-up study indicates that those who were initially disabled, paralysed, and bedridden improved greatly with time and began to be independent in caring for themselves and walking around. We have no doubt that physiological function improves or even recovers completely.

Pierce *et al*,<sup>24</sup> commenting on an outbreak in New Mexico, suggested that the recovery might be related to the fact that ingestion of the mercury compounds occurred over a relatively short period (three months) and then abruptly stopped when the symptoms appeared. Exposure in Iraq<sup>2</sup> was also short. In Minamata the ingestion of mercury-contaminated fish probably supplied lower doses over longer periods, and even after the onset of symptoms. Although the consumption of fish from Minamata Bay was supposed to have stopped, occasional additional doses taken with fish meals, at long intervals, cannot be excluded in the absence of laboratory data. The Iraqi outbreak was comparable with that in the family studied by Pierce; hence the difference in the clinical picture and outlook. Furthermore, the short exposure in Iraq was similar to that reported by Hunter *et al*<sup>2</sup> in adults, although their patients showed poor recovery. This difference may reflect differences in the sensitivity of children and of adults.

The young central nervous system, unaffected by aging and vascular change, might give a pure clinical picture of methylmercury poisoning, in which recovery becomes evident. Children do not seem to be more susceptible than adults to comparable methylmercury exposure and their capacity to improve or recover appears to be greater.

Despite individual variation, the severity of the poisoning is related to blood concentrations of mercury. Furthermore, the severity of poisoning seems to determine the extent of recovery. Patients with mild poisoning completely recovered, while those with very severe poisoning recovered only slightly.

Mild cases of poisoning are more difficult to diagnose as they manifest themselves mainly as subjective complaints and usually disappear<sup>11 24</sup> over a few months. The proof that these symptoms are caused by methylmercury depends on (a) a correlation of these complaints with blood mercury concentrations<sup>9 25</sup> and (b) the patient's history indicating that the onset of symptoms coincided with exposure to methylmercury.

We thank the Minister of Health and the director of the Medical City, Baghdad, for supplying the hospital facilities. We also thank the deans of the medical schools of the Universities of Baghdad and Rochester for arranging the interuniversity collaboration. The co-sponsored analytical laboratory under the direction of Dr Hashim I Dahir supplied the analytical data on mercury. We are also indebted to the director general of the Mussayeb al-Kabeer Irrigation Project for help in this area; Dr A Harith for help with the study of patients at Salman Pak; and Dr S Sabelash, consultant ophthalmologist, and Dr G Toma, consultant otolaryngologist, for their help in assessing

visual and auditory effects. We also thank Drs S F Damluji, L Magos, and D O Marsh for reading and criticising this paper.

The University of Rochester was supported in part by a National Science Foundation (Research Applied to National Needs) Grant GI-300978, a Centre Grant (ES-01247), and a Programme Project Grant (ES-01248) from the National Institute of Environmental Health Sciences.

## References

- <sup>1</sup> Kurland, L T, in *Mercury, Mercurials, and Mercaptans*, ed M W Miller and T W Clarkson. Springfield, Illinois, Charles C Thomas, 1973.
- <sup>2</sup> Hunter, D, Bamford, R R, and Russell, D S, *Quarterly Journal of Medicine*, 1940, **33**, 193.
- <sup>3</sup> Hunter, D, and Russell, D S, *Journal of Neurology, Neurosurgery, and Psychiatry*, 1954, **17**, 235.
- <sup>4</sup> McAlpine, D, and Araki, S, *Lancet*, 1958, **2**, 629.
- <sup>5</sup> McAlpine, D, and Araki, S, *American Medical Association Archives of Neurology*, 1959, **1**, 522.
- <sup>6</sup> Jalili, M A, and Abbasi, A H, *British Journal of Industrial Medicine*, 1961, **18**, 303.
- <sup>7</sup> Damluji, S F, *Journal of the Faculty of Medicine, Baghdad*, 1962, **4**, 83.
- <sup>8</sup> Haq, I U, *British Medical Journal*, 1963, **1**, 1579.
- <sup>9</sup> Bakir, F, *et al*, *Science*, 1973, **181**, 230.
- <sup>10</sup> Magos, L, and Clarkson, T W, *Journal of the Association of Analytical Chemistry*, 1972, **55**, 966.

- <sup>11</sup> Damluji, S F, *The Bulletin of the World Health Organisation*, 1976, **53**, suppl, p 11.
- <sup>12</sup> Miettinen, S K, in *Mercury, Mercurials, and Mercaptans*, ed M W Miller and T W Clarkson. Springfield, Illinois, Charles C Thomas, 1973.
- <sup>13</sup> McCall, R B, *Fundamental Statistics for Psychology*. New York, Harcourt Brace Jovanovich Inc, 1975.
- <sup>14</sup> Nordberg, G F, and Strangert, P, *Effects and Dose Response Relationships of Toxic Metals*. Amsterdam, Elsevier Scientific Publishing Company, 1976.
- <sup>15</sup> Shahrastani, H, and Shihab, K M, *Archives of Environmental Health*, 1974, **28**, 342.
- <sup>16</sup> Kurland, L T, Faro, S N, and Siedler, H, *World Neurology*, 1960, **1**, 370.
- <sup>17</sup> Tshchiya, K, *Keio Journal of Medicine*, 1969, **18**, 213.
- <sup>18</sup> *British Medical Journal*, 1972, **2**, 605.
- <sup>19</sup> Hill, W H, *Canadian Public Health Journal*, 1943, **34**, 158.
- <sup>20</sup> Brown, I, *American Medical Association's Archives of Neurology and Psychiatry*, 1954, **72**, 674.
- <sup>21</sup> Hay, W J, *et al*, *Journal of Neurology, Neurosurgery, and Psychiatry*, 1963, **26**, 199.
- <sup>22</sup> Harada, Y, *Infantile Minamata Disease: Study Group of Minamata Disease*. Kumamoto University, Japan, 1968.
- <sup>23</sup> Damluji, S F, Amin-Zaki, L, and Elhassani, S B, *British Medical Journal*, 1972, **4**, 489.
- <sup>24</sup> Pierce, P E, *et al*, *Journal of the American Medical Association*, 1972, **220**, 1439.
- <sup>25</sup> Mufti, A W, *et al*, *Bulletin of the World Health Organisation*, 1976, **53**, suppl, p 23.

(Accepted 5 January 1978)

# Lichenoid tattoo hypersensitivity

A TAAFFE, A G KNIGHT, R MARKS

*British Medical Journal*, 1978, **1**, 616-618

## Summary and conclusions

**Four patients are described who developed granulomatous reactions in the red portions of their tattoos. Histopathological and immunofluorescence studies showed features of lichen planus. Mercury was identified in only one patient's lesion, and hypersensitivity to mercury was shown by patch testing in one other patient.**

**Tattooing may provide a localised antigenic challenge resulting in spontaneously occurring lichen planus.**

## Introduction

Tattoos occasionally have intriguing and even disastrous consequences in addition to remorse. Fortunately most complications of tattoos are rare, but of the complications that do occur a granulomatous response in the red portion is the most common. We describe four patients who presented over a six-month period with tattoo granulomata who had the same unusual tissue reaction.

**Department of Dermatology, University Hospital of Wales, Cardiff**  
A TAAFFE, MRCP, MRCPi, locum senior registrar (now senior registrar in dermatology, Royal Infirmary, Hull, and General Infirmary, Leeds)  
A G KNIGHT, MD, MRCP, consultant dermatologist

**Department of Medicine, Welsh National School of Medicine, Heath Park, Cardiff CF4 4XN**  
R MARKS, MB, FRCP, reader and consultant in dermatology

## Patients

The main clinical features of the four patients at presentation are shown in the table. The affected areas of all the tattoos were raised up to 0.5 cm above the level of the surrounding skin, were sharply confined to the red areas, and were slightly scaly or crusted in places (see fig 1). Three patients (cases 1, 2, and 4) were tattooed by the same tattooist in Cardiff within a nine-month period in 1976-7. The other patient (case 3) could not remember which tattooist was responsible for which tattoo, but knew that they were all done in Cardiff. The tattooist in cases 1, 2, and 4 was questioned about his technique. Samples of the pigments that he said had been used were obtained for analysis.

## Investigations and results

**Histological findings**—Biopsy specimens of the swollen red portions of all four patients' tattoos were examined histologically and by immunofluorescence. In all cases the histological features were similar. Scattered throughout the dermis were irregular granules and clumps of an amorphous black material that was assumed to be tattoo pigment. Most of the pigment was extracellular and did not seem to be related to the inflammatory cell infiltrate or to the degree of lichenoid change. The inflammatory cell infiltrate was dense and not aggregated around any anatomical structure. Lymphocytes and histiocytes predominated but there were also polymorphonuclear leucocytes and plasma cells. The inflamed areas were oedematous and there were small collections of extravasated red blood cells. The overlying epidermis showed quite striking lichenoid features (fig 2). There was irregular hypertrophy and hyperkeratosis interspersed with areas of epidermal atrophy. The dermoepidermal junction showed the typical "sawtooth" profile of lichen planus in some sites. The normal basal layer of the epidermis was replaced by a patchily vacuolated layer of cells that showed pronounced cytotid-body formation and was infiltrated in places by inflammatory cells. Cytoid bodies were grouped in grape-like clumps below the dermoepidermal junction (fig 3).

**Immunofluorescence**—Cryostat sections were examined by direct immunofluorescence with a Nikon microscope fitted with a