

Papers and Originals

Liver Transplantation in Man—I, Observations on Technique and Organization in Five Cases

R. Y. CALNE,* M.A., M.S., F.R.C.S.; ROGER WILLIAMS,† M.D., M.R.C.P.

[WITH SPECIAL PLATE]

Brit. med. J., 1968, 4, 535-540

Summary: In view of the extreme sensitivity of the human liver to ischaemic damage, the organization of clinical transplantation is of necessity complicated. From our preliminary experience of five human liver allografts we feel that active collaboration between hospitals is essential in order to practise human liver transplantation. It is unnecessary and undesirable to interfere in any way with potential liver donors. Nevertheless, the nature of the surgical technique requires that the liver is cooled within 15 minutes of death if satisfactory function is to result in the grafted organ.

This report describes technical difficulties that were encountered which can limit successful liver transplantation. The first patient was in severe liver failure and had an accessory liver graft in the splenic fossa after splenectomy. This liver suffered irreversible ischaemic damage, which led to an uncontrollable haemorrhagic state with exsanguination that resulted in death the day after operation. The second patient, a 10-month-old infant with biliary atresia and liver failure, died from cardiac arrest shortly after the operation.

The remaining three transplants developed good initial function. One patient survived 11 weeks, and one has returned to work.

Introduction

The liver can be transplanted to the normal anatomical position (orthotopic) or to an abnormal situation (heterotopic). A variety of heterotopic techniques have been described (Starzl *et al.*, 1966), but none is ideal. It is difficult to accommodate an extra liver in the abdomen in such a way that it receives arterial and portal blood and drains hepatic venous blood and bile. There is a danger that the multiple anastomoses will be kinked or otherwise compromised. Orthotopic liver transplantation requires preliminary hepatectomy of the recipient (Moore *et al.*, 1960; Starzl *et al.*, 1960). This provides the liver with normal anatomical surroundings, and revascularization and biliary drainage are straightforward.

Renal function can be replaced artificially by dialysis, which is used to support the patient before and if necessary after renal transplantation. There is no comparable method of replacing liver function. The two categories of fatal liver disease for which transplantation may be indicated are progressive liver failure with cirrhosis and primary malignant tumours of the

liver. If the liver is malignant then hepatectomy is an obvious prerequisite, but with non-malignant progressive liver disease there are theoretical advantages in leaving the residual function of the patient's own liver and avoiding a dangerous and difficult hepatectomy. The unsatisfactory surgical features of heterotopic liver transplantation may, however, make this an unwise choice.

If the liver is left at 37° C. without a blood supply for more than 15 minutes serious damage is likely to occur. The liver cell necrosis results in impairment of function and also appears to be responsible for the uncontrollable haemorrhagic syndrome that occurred in our first case. To prevent this damage it is therefore essential to cool the liver within 15 minutes of death, by infusion of a chilled innocuous fluid through the portal vein. If this is followed by a cold plasma/bicarbonate/dextrose solution the liver can be kept at 4° C. with little deterioration for two hours (Schalm, 1968). Slow deterioration does, however, occur, and, since hepatectomy of the recipient can be an extremely difficult and time-consuming operation, longer preservation is desirable. The most satisfactory method so far described by Brettschneider *et al.* (1968) utilizes hyperbaric oxygen, hypothermia, and continuous perfusion with diluted blood. With this technique excellent preservation of canine livers for eight hours has been achieved, and an identical method has been used to preserve human livers for transplantation by Starzl *et al.* (1968a). Before laparotomy of the donor, while the preservation apparatus is being prepared, it may be helpful to cool the cadaver by means of a heart-lung machine with a refrigeration unit (Marchioro *et al.*, 1963).

Organization

It follows from the above remarks that the requirements for a clinical liver transplantation are as follows: a recipient with fatal liver disease at a terminal stage, but who is nevertheless fit enough to withstand a major and prolonged operation, and a donor whose liver can be cooled within 15 minutes of death. It is not surprising that clinical liver transplantation has been slow in developing. Of five heterotopic liver transplants in man the longest survival was 35 days (Starzl *et al.*, 1967). Previous to July 1967 nine orthotopic liver transplants were performed in man and the longest survival was 23 days. Since that time the clinical liver transplantation programme at Denver has had more success (Starzl *et al.*, 1968a, 1968b). Of 17 transplants in 16 patients the longest survivor was more than a year, the patient eventually dying from secondary deposits of his original primary hepatoma. Of the seven patients surviving at the present time, one has received a second liver transplant after the first had been rejected and removed (Starzl, Brettschneider, and Porter, personal communication).

* Professor of Surgery, University of Cambridge.

† Consultant Physician, M.R.C. Group on Metabolism and Haemodynamics of Liver Disease, Department of Medicine, King's College Hospital, London S.E.5.

In view of the major organizational requirements for a successful liver transfer it is necessary for there to be a period of warning during which arrangements can be made. The recipient should therefore have sufficient residual liver function to permit him to wait for the availability of a transplant. The most suitable donors are cases in which resuscitation has been performed, but where irreversible brain damage has occurred and a decision has been made, quite irrespective of any transplantation considerations, to cease resuscitation. When recovery is impossible it is customary to cease artificial ventilation and support of the circulation. This was true before the development of organ transplantation, and we feel it is unnecessary to modify the procedure in any way for the purposes of transplantation. The medical staff caring for the patient should not be involved in the transplantation operation. After resuscitation has been abandoned no procedures are started on the donor until it is clear that there is no spontaneous respiration or heart beat, and death has been confirmed by independent medical staff. Liver transplantation can then be performed entirely within the confines of long-established ethical medical treatment. All that is necessary is for the doctors who have decided to stop resuscitation to inform the transplantation team, who will then be prepared.

Since the availability of suitable donors in any one institution is limited, it is felt that if clinical liver transplantation is to be developed in the United Kingdom it will be necessary for hospitals to collaborate. We do not feel justified in moving a potential donor from one hospital to another for the purposes of organ transplantation. Instead, we move the transplant team and the recipient to the same hospital as the donor. A close liaison has been established between Addenbrooke's Hospital, Cambridge, and King's College Hospital, London, where there are complementary interests in liver transplantation and liver disease. It is proposed to undertake a definitive programme of liver transplantation, collaborating with other hospitals where this is possible.

This report summarizes certain technical aspects of our first five cases. The full clinical details of Cases 3 and 4 are given in an accompanying article at p. 541 (Calne *et al.*, 1968). Reports of the anaesthesia and tissue typing are in preparation.

Case 1

A 47-year-old man was admitted to Addenbrooke's Hospital on 23 May 1967 with gastrointestinal bleeding. He had a past history of alcoholism which had led to liver failure, with ascites and periods of coma.

On examination he was pale, jaundiced, and ill-looking. The liver was not palpable, but the spleen could be felt below the left costal margin. There was marked ascites. Haemoglobin was 11.3 g./100 ml., white blood cell count 5,400/cu. mm., platelets 60,000/cu.mm., prothrombin ratio 17–13, and bilirubin 2 mg/100 ml. (1.6 mg./100 ml. conjugated). Spleno-portogram showed large gastro-oesophageal varices. Serum albumin varied between 1.9 and 2.3 g./100 ml. The patient had had two previous attacks of haematemesis and melaena requiring transfusion and had been comatose for one week. He recovered from coma and became fully alert. In view of his continued gastrointestinal bleeding, low albumin, clinical jaundice, and a previous history of coma, it was felt that any surgical procedure aimed at reducing portal venous pressure would result in irreversible coma. His liver disease was considered to be beyond conventional therapy. The possibility of hepatic transplantation was discussed with the patient, who was anxious that this should be tried.

The donor was a 50-year-old woman who died from a head injury. She was brought into hospital dead and attempts at resuscitation were made for half an hour. There was no response to the resuscitative efforts.

Via a midline abdominal incision the superior mesenteric vein was cannulated and perfused with 1 litre of chilled balanced salt solution. An incision was made in the right common iliac vein to allow egress of perfusate. While perfusion was in progress the liver

was removed and put into a plastic bag surrounded by cold perfusion fluid. The hepatic artery was similarly perfused and the plastic bag was surrounded with ice. This procedure was used in the four subsequent cases.

Before the start of perfusion there had been a period of one hour in which the liver at 37° C. had been unperfused.

Recipient Operation

Under light general anaesthesia a left subcostal incision was made and extended across the midline. Ascitic fluid was aspirated. The spleen, which was extremely large, was removed. The liver was taken out of the plastic bag at 11.30 a.m., three hours after the death of the donor. It was rotated so that the hilus faced towards the midline and it was placed in the splenic fossa, the shrunken cirrhotic liver allowing room for the transplant. The gall bladder faced anteriorly and the suprahepatic inferior vena cava faced towards the renal vein. The anastomoses were performed as shown in Fig. 1. The coeliac artery was anastomosed end-to-end to the splenic; the superior mesenteric vein was anastomosed end-to-end to the splenic vein, and the splenic vein of the transplant was anastomosed to an accessory splenic vein, which lay in the tail of the pancreas. Clamps were removed from the splenic vessels and blood was allowed to perfuse the liver. The infrahepatic inferior vena cava was ligated. The suprahepatic inferior vena cava was anastomosed end-to-side to the left renal vein. The liver appeared to perfuse satisfactorily. The common bile duct was ligated and the gall bladder was anastomosed to the end of a Roux loop of jejunum. The anastomoses took an hour, so that the total ischaemia time was four hours. The wound was closed in layers with drainage. Though no heparin had been given after operation there was a continuous steady loss of blood from the drains. Two hours after the operation bleeding became more profuse; blood oozed from the wound and around the intravenous infusion. The blood clotted and then underwent complete fibrinolysis after about 20 minutes. The patient did not recover consciousness.

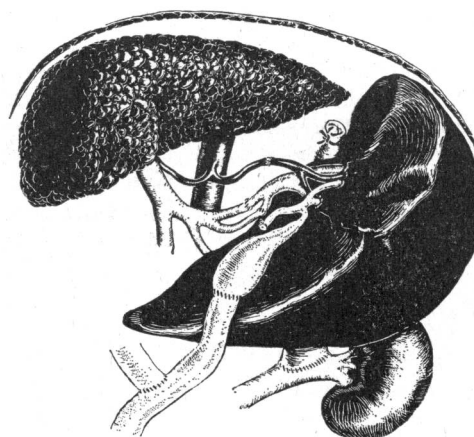

FIG. 1.—Diagram of operative procedure in Case 1, showing heterotopic liver allograft in the splenic bed.

The wound was reopened and bleeding was seen to be coming from the whole operative site and particularly from the caval anastomosis, where additional sutures were inserted. Haemorrhage continued in spite of the administration of aminocaproic acid, intravenous fibrinogen, and fresh blood. In all, 23 litres of blood were transfused. The patient died at 5.30 next morning.

The biopsy taken shortly after transplantation of the liver showed marked degenerative changes in many of the liver cells (Special Plate, Fig. 2). Necropsy revealed the typical changes of severe portal cirrhosis of the patient's own liver with large gastro-oesophageal varices. The transplanted liver was severely congested. The anastomoses were all patent, though the inferior vena caval anastomosis was narrowed by the additional sutures. Histology of the transplant showed congestion, haemorrhage, and areas of liver necrosis. Some liver cells were reasonably well preserved. There was no regular zonal distribution of these changes.

Comment.—This liver was removed from a cadaver after irreversible ischaemic damage had occurred, and this led to an

uncontrollable haemorrhagic state. The heterotopic situation of the liver was not satisfactory and congestion of the liver at necropsy indicated poor venous drainage.

Case 2

A child of 10 months was admitted to Addenbrooke's Hospital on 11 June 1968 with jaundice which had developed shortly after birth. Laparotomy at the age of 2 months confirmed the diagnosis of biliary atresia. During the two months preceding admission the child had developed biliary cirrhosis with ascites and was considered to be unsuitable for any further treatment.

Haemoglobin was 8.6/100 ml., bilirubin 8.2 mg./100 ml. (5.7 mg. conjugated), total protein 6.2 g./100 ml. with a moderate increase in α_2 - and γ -globulin.

On examination he was extremely jaundiced, with enormous abdominal distension, dilated superficial veins coursing over the anterior abdominal wall, and gross ascites. The liver was markedly enlarged. The spleen was just palpable. An umbilical hernia was present.

It was felt that the prognosis was hopeless, and the parents requested that an attempt should be made to perform a liver transplant.

The donor was a child of 2 who had died as a result of upper respiratory tract infection which led to cardiac and respiratory arrest. The time of death was 4.35 p.m. Cardiac massage and artificial ventilation were attempted without any result. At 4.57 p.m. a transverse upper abdominal incision was made, a cannula was inserted into the superior mesenteric vein, and the liver was perfused with 1 litre of cold Hartmann's solution containing 2,000 i.u. of heparin and then with 500 ml. of plasma/bicarbonate/glucose solution¹ (Schalm, 1968). An incision was made into the inferior vena cava to allow the perfusate to escape. An accessory right hepatic artery was found to be arising from the superior mesenteric artery; this was preserved together with the other vessels and the bile ducts.

Recipient Operation

A bilateral subcostal incision was made. Dilated anastomotic veins in the anterior abdominal wall were individually ligated and divided. Ascitic fluid was aspirated. Dense adhesions between the bowel, the parietes, and the liver were divided. The liver was huge, green, and embossed with bile cysts; there were large lymph nodes at the hilus. Removal of the diseased liver was time-consuming. The liver was skeletonized until it was attached only by its vascular connexions. The portal vein and inferior vena cava were temporarily occluded, and since this produced no deterioration in the general condition of the patient no vascular shunts were used. Hepatectomy was completed at 7.35 p.m., when the donor liver was removed from ice.

The vena cava was anastomosed to the vena cava above the liver, and the portal vein was anastomosed to the portal vein end-to-end. The clamp was removed from the portal vein at 7.55 p.m. and blood was allowed to perfuse the liver. After 10 ml. of blood had been discharged from the inferior vena cava below the liver this vessel was clamped and the vascular clamp was removed from the inferior vena cava above the liver. The aorta was mobilized and cross-clamped, a Carrel patch with the coeliac artery of the donor was anastomosed end-to-side to the aorta of the recipient. The superior mesenteric artery of the donor was anastomosed end-to-end to the recipient's hepatic artery and the inferior vena cava was anastomosed end-to-end to the inferior vena cava below the liver. All anastomoses were completed by 8.50 p.m. The bile duct was ligated and the gall bladder was anastomosed to a Roux loop of jejunum (Fig. 3). The liver was rather pale and blotchy and did not appear to be perfusing well, but all anastomoses looked satisfactory. The falciform ligament of the transplant was sutured to that of the recipient. No heparin was used, 4 mg. of fibrinogen was given intravenously, haemostasis was achieved, and the wound was closed in layers. Intravenous dextrose and bicarbonate were given.

¹ Preservation fluid containing 400 ml. of reconstituted human plasma, 10 ml. of 2% procaine, 8 ml. of 5% glucose, and 20 ml. of 1.4% sodium bicarbonate.

The child's condition improved at the end of the operation; he was breathing spontaneously and regained consciousness. Half an hour after the end of the operation there was a sudden cardiac and respiratory arrest, the cause of which was not determined. Attempts at resuscitation failed. At necropsy no cause of death could be found. All anastomoses of the transplant were patent. Microscopy of the transplant showed slight centrilobular necrosis of many lobules and oedema of the portal tracts with dilatation of lymphatics. There was a slight neutrophil infiltrate of the hepatic capsule. Most of the liver parenchyma was well preserved.

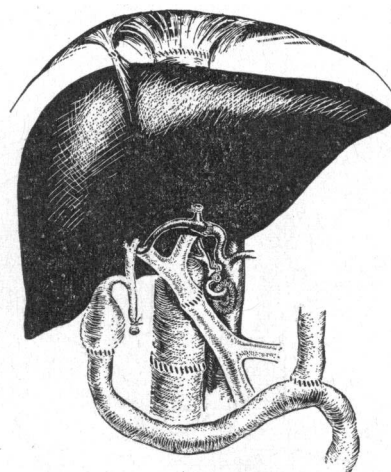


FIG. 3.—Diagram of operative procedure in Case 2.

Comment.—It was felt that the extensive operative procedure in an exceedingly ill child was too great for it to withstand, but the liver preservation appeared to be adequate.

Case 3

A 46-year-old woman was admitted to Addenbrooke's Hospital on 7 February 1968 with a primary cholangiocarcinoma which had caused obstructive jaundice and gastrointestinal haemorrhage. Chlorambucil treatment for her tumour resulted in marrow depression and septicaemia. Full details are reported elsewhere (Calne *et al.*, 1968).

Though in an extremely ill state, the patient was most anxious to have a liver transplant, and in spite of persisting marrow damage liver transplantation was performed.

The donor was a 5-year-old child who had died as a result of mumps encephalitis. Death occurred at 4.50 p.m. A transverse abdominal incision was made and the superior mesenteric vein was perfused with cold heparinized Ringer's solution at 5.05 p.m. An incision was made in the right common iliac vein to allow egress of perfusate. The perfusate was changed to plasma bicarbonate dextrose solution. Similar perfusate was used in the hepatic artery.

Recipient Operation

A bilateral subcostal incision was made. The liver was found to be huge, with deposits of growth palpable in both lobes but no ascites and no evidence of growth outside the liver. There were dense vascular adhesions between the porta hepatis, omentum, and duodenum. The liver was skeletonized until it was attached only by its vascular connexions. During the dissection the patient's blood pressure tended to fall, probably owing to manipulation of the liver causing embarrassment of respiration and cardiac action and intermittent obstruction of the vena cava. The patient was systemically heparinized with 10,000 units of heparin. The portal vein was clamped at 6.08 p.m. and portal venous blood was shunted to the right internal jugular vein (Fig. 4). It was felt that the inferior vena cava of the recipient was much too large to be anastomosed to the vena cava of the small donor liver; therefore the liver was filleted off the vena cava, clamping the main hepatic vein and ligating all other branches. The malignant liver was removed at 6.20 p.m. and the donor liver was removed from the ice at 6.40 p.m.

The suprahepatic inferior vena cava was anastomosed end-to-end to the main hepatic vein. The portal vein was anastomosed end-to-end to the portal. There was considerable discrepancy in size, and plication was necessary in order to complete the anastomosis. The clamp was removed from the portal vein at 7.11 p.m. and blood was allowed to perfuse the liver. After 30 ml. of blood had been discharged from the inferior vena cava below the liver this vessel was ligated and the clamp on the hepatic vein was removed. The coeliac artery with a rim of aorta was anastomosed end-to-end to

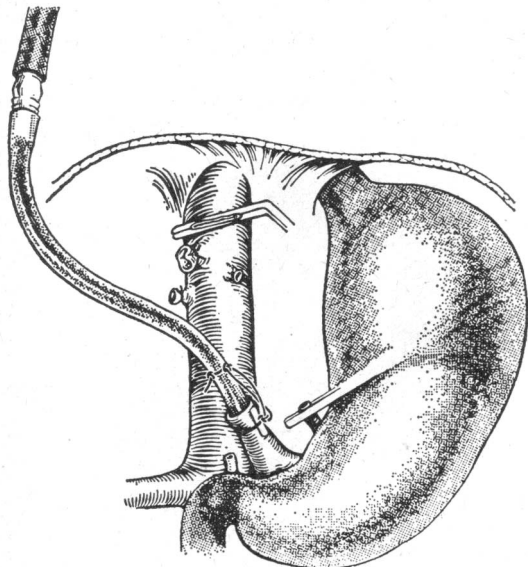


FIG. 4.—Diagram of the operation at the stage of hepatectomy in Case 3, showing the hepatic veins clamped and the inferior vena cava intact. A direct shunt emerges from the portal vein and drains into the right internal jugular vein.

the divided hepatic artery of the recipient (Fig. 5). This anastomosis was completed at 7.23 p.m., and on release of the arterial clamp an excellent pulse was felt throughout the length of the hepatic artery of the donor and the liver changed from a dark red colour to bright salmon pink with a normal consistency. The diameter of the common bile duct of the recipient was 0.7 cm., while that of the donor was 0.3 cm. An end-to-end anastomosis was felt to be surgically unsatisfactory. The alternative of anastomosing the gall bladder to the bowel was felt to be undesirable because of the danger of ascending cholangitis. Accordingly the gall bladder was mobilized from its bed.

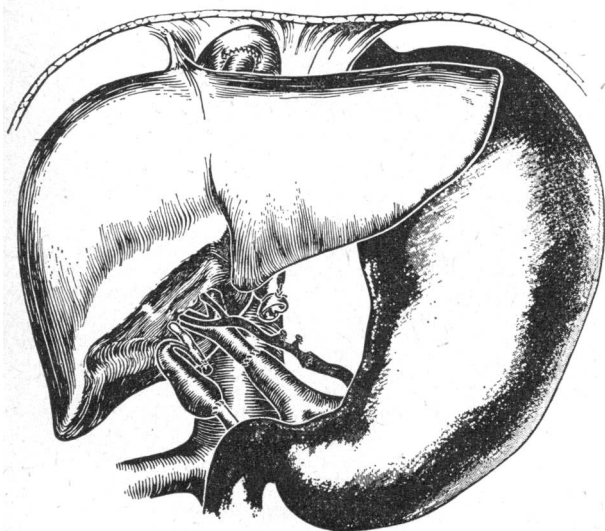


FIG. 5.—Diagram of operative procedure in Case 3, showing anastomosis of the suprahepatic inferior vena cava to the hepatic veins. The infrahepatic inferior vena cava is ligated.

The distal two-thirds were freed from the liver and turned downwards. There was no acute kink and the fundus of the gall bladder was anastomosed to the open end of the common bile duct with

continuous 4/0 chromic catgut. The anastomosis lay in a satisfactory position, and bile was seen to be produced from the liver at this stage. The common bile duct was then ligated. The falciform ligament was sutured to the diaphragm, and a minute liver biopsy was taken. Yates drains were brought out of the lateral extremities of the wound, which was closed in layers. Every attempt was made to secure haemostasis, but the whole of the operation site was oozing blood at the end of the operation and the patient felt cold. The heparin was reversed with protamine. Fibrinogen was given, and the patient was warmed with blankets. Significant bleeding from the wound ceased in the subsequent two hours. During the operation the patient received 7 litres of blood, 100 ml. of 20% mannitol, and intravenous dextrose and bicarbonate solutions.

Biopsy of the transplanted liver shortly after revascularization showed well-preserved liver cells. Initial function of the liver was considered to be good (Fig. 6). The patient rapidly regained consciousness. Full postoperative details are recorded elsewhere (Calne *et al.*, 1968).

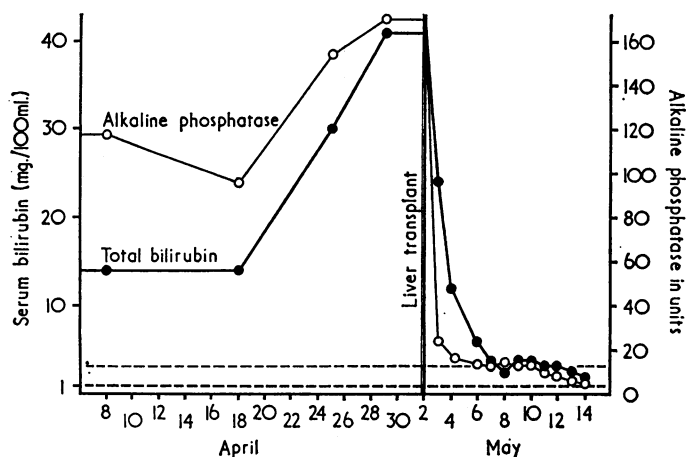


FIG. 6.—Chart of alkaline phosphatase in King-Armstrong units and total bilirubin in mg./100 ml. of blood (Case 3). Blood levels of both fell very rapidly after liver allografting on 2 May 1968.

The patient died 11 weeks after operation following partial infarction of the liver. This appeared to be caused by a clot arising in the recipient hepatic artery, where it had been clamped during the operation.

Case 4

A 41-year-old man was admitted to King's College Hospital on 23 September 1968 with a primary liver cell cancer. Full details are reported elsewhere (Calne *et al.*, 1968). There was massive enlargement of the liver, but the patient was not jaundiced and was ambulant. In view of the hopeless prognosis he was anxious to have a liver transplant.

The donor was a 13-year-old child who had died as a result of a head injury. Death occurred at 11.27 p.m. A bilateral subcostal incision was made, and the superior mesenteric vein was perfused with 2 litres of cold heparinized Hartmann's solution followed by 200 ml. of plasma bicarbonate dextrose solution. The cold infusion began at 11.40 p.m. An incision was made in the right common iliac vein to allow egress of perfusate. An accessory right hepatic artery was found to be arising from the superior mesenteric artery. This was preserved together with the other vessels and the bile ducts. The liver was immersed in cold saline in a bowl surrounded with ice at 12.35 a.m.

Recipient Operation

A bilateral subcostal incision was made. The liver was grossly enlarged, and there were numerous vascular adhesions between the liver, parietes, and surrounding viscera. These were ligated and divided. Huge veins were coursing over the surface of the liver, which bled on touch. During mobilization of the liver bleeding occurred whenever the venous outflow was obstructed. There was no evidence of extrahepatic spread of tumour, but the whole of the

left lobe of the liver was replaced by tumour and multiple small tumour deposits were scattered through the right lobe. During the final stages of the skeletonization of the liver the infrahepatic vena cava was divided; both ends were controlled and ligated. The patient's systolic blood pressure fell to 60 mm. Hg, but gradually rose with replacement of blood. The hepatectomy was completed at 1.00 a.m., when the donor liver was removed from the ice. The vena cava was anastomosed to the vena cava above the liver; the portal vein was anastomosed to the portal vein end-to-end. The clamp was removed from the portal vein at 1.26 a.m., and blood was allowed to perfuse the liver. After 30 ml. of blood had been discharged from the inferior vena cava below the liver this vessel was clamped and the suprahepatic caval clamp was removed. The liver rapidly assumed a satisfactory colour of pale pink and normal consistency. The coeliac artery was anastomosed end-to-side to the proximal hepatic artery of the recipient, a Carrel patch being used. The donor superior mesenteric artery was anastomosed end-to-end to the cut distal hepatic artery (Fig. 7). The clamp was removed from the hepatic artery at 1.55 a.m., and the infrahepatic vena caval anastomosis was made end-to-end.

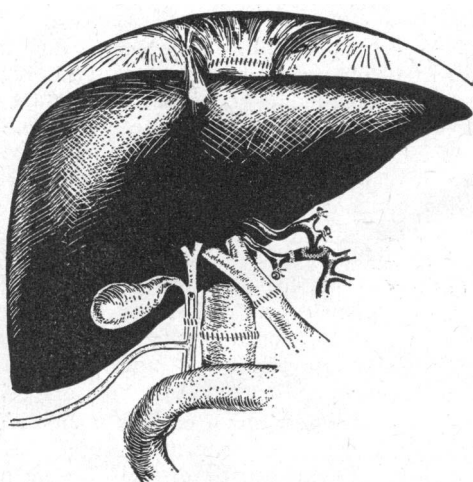


FIG. 7.—Operative procedure in Case 4. The long arm of the T tube emerges through the recipient's common bile duct.

The common bile duct was anastomosed with 4/0 interrupted catgut sutures end-to-end over the upper limb of a rubber T-tube, which was brought out through the recipient's common duct below the anastomosis. Bile was seen to be produced by the liver at this stage. The T-tube was brought out through a stab incision. Haemostasis was achieved, the falciform ligament was sutured to the diaphragm, and a minute liver biopsy was taken. Two grammes of ampicillin dissolved in 50 ml. of saline was introduced under the diaphragm and in the subhepatic space. Yates drains were brought out by stab incisions through both flanks from both subdiaphragmatic areas and from the subhepatic space of the right side. The wound was closed in layers.

The patient's general condition at the end of the operation was good and he woke immediately from the anaesthetic, but continuous haemorrhage occurred from the drainage site on the right side, and after 12 hours the abdomen was re-explored. One litre of clotted blood was found in the peritoneal cavity; this was removed. No bleeding could be found at any point in relation to the liver or elsewhere. The wound was closed, and haemorrhage was then seen to be coming from the drain site in the right flank. This wound was opened further, and an artery in the subcutaneous tissue was found to be bleeding; this was oversewn, and other small vessels near by were clamped. Bleeding then ceased, and the patient's general condition became excellent. He had received mannitol, bicarbonate, dextrose, and 22 litres of blood. The transplant biopsy taken shortly after revascularization showed well-preserved liver parenchyma (Special Plate, Fig. 8).

The subsequent postoperative course is recorded elsewhere (Calne *et al.*, 1968). At the time of writing the patient is clinically well and has returned to work, having been discharged from hospital on the seventeenth postoperative day.

Case 5

A 46-year-old man was admitted to King's College Hospital on 27 October 1968 with a primary cholangiocarcinoma which had caused obstructive jaundice. In view of the hopeless prognosis he was anxious to have a liver transplant.

The donor was a 64-year-old man who had died as a result of a head injury. Death occurred at 10.26 p.m. A bilateral subcostal incision was made, and the superior mesenteric vein was perfused with 2 litres of cold heparinized Hartmann's solution followed by 200 ml. of plasma/bicarbonate/dextrose solution. Cold infusion began at 10.30 p.m. An incision was made in the right common iliac vein to allow egress of perfusate. The liver was removed and placed in cold saline at 11.15 p.m.

Recipient Operation

A bilateral subcostal incision was made. The liver was grossly enlarged, but there was no evidence of growth on the surface of the liver or elsewhere in the peritoneal cavity. There were dense adhesions in the region of the aditus. The common bile duct was extremely fibrotic, and it was felt that it would be unsuitable for anastomosis. It was therefore divided and ligated just above the duodenum. Some purulent material discharged from the hilus of the liver; this was cultured. Hepatectomy was completed at 11.15 p.m., when the donor liver was removed from the ice.

The vena cava was anastomosed to the vena cava above the liver, and the portal vein was anastomosed to the portal vein end-to-end and blood was allowed to perfuse the liver. After 30 ml. of blood had been discharged from the inferior vena cava below the liver the vessel was clamped and the suprahepatic vena caval clamp was removed. The liver rapidly assumed a satisfactory colour of pale pink and normal consistency. The coeliac artery of the donor was anastomosed to the hepatic artery of the recipient end-to-end. The clamp was removed from the hepatic artery at 12.15 a.m., and there was an excellent arterial pulse up to the hilus of the liver, with no evidence of kinking or obstruction (Fig. 9). The infrahepatic vena caval anastomosis was made end-to-end, and the fundus of the gall bladder was anastomosed to a Roux loop of jejunum which was brought up through the mesocolon. There was considerable bleeding from the jejunal wall in spite of the fact that diathermy had been used to open it, but it appeared that the all-coats catgut layer had stopped the bleeding. Two grammes of ampicillin dissolved in 50 ml. of saline was introduced under the diaphragm and in the subhepatic space. A Yates drain was brought out through the right extremity of the main wound, which was closed in layers.

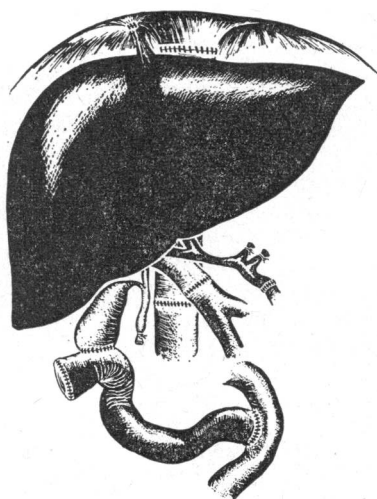


FIG. 9.—Diagram of operative procedure in Case 5.

The patient's condition at the end of the operation was good, and he rapidly regained consciousness. The following day there was severe gastrointestinal haemorrhage, which continued in spite of normal clotting factors and transfusion of fresh blood. Laparotomy

was therefore performed, and the bleeding was found to be coming from the jejunal side of the cholecystoduodenostomy. The bleeding points were individually ligated and the anastomosis was redone. The transplant biopsy taken shortly after revascularization showed a well-preserved liver. He received, in all, 7 litres of blood, 4 g. of fibrinogen, and 200 mg. of hydrocortisone in addition to mannitol, bicarbonate, and dextrose. No heparin or protamine was given. The postoperative course was complicated by further gastrointestinal haemorrhage, jaundice, and peritonitis. Death from sepsis occurred after three weeks.

Discussion

These five cases allow several conclusions to be made. The irreversible ischaemic damage in Case 1 leading to an uncontrollable haemorrhagic syndrome reinforces the importance of reducing the warm ischaemic time to a minimum of 15 minutes between death of the donor and cooling of the liver. In the subsequent four cases the donor liver was cooled within 15 minutes of death, and in Cases 3–5, with total ischaemic times (from death of donor until revascularization with portal blood) of 141, 106, and 94 minutes, excellent preservation was achieved by the simple cooling that was used (Schalm, 1968).

The extremely serious liver failure in Case 1 by the time the transplantation was performed made the likelihood of success unlikely even with a well-preserved and satisfactorily transplanted heterotopic liver. Though the splenic fossa provided room for the liver transplant, and the anastomoses appeared satisfactory at the time of the operation, the venous drainage was inadequate, and the other anastomoses might have been compromised if the patient had adopted an upright posture. We feel that the orthotopic site is preferable.

In Cases 1, 2, and 5 biliary drainage was to a Roux loop of jejunum. This was felt to be preferable to cholecystoduodenostomy, though less desirable than biliary drainage, which retains the patient's own sphincter of Oddi, as in Cases 3 and 4.

The cause of death in Case 2 was not apparent; however, the child was extremely frail and ill, and the recent rapid development of ascites indicated terminal liver failure.

In Case 3 there were technical difficulties in fitting a small child's liver into an adult. The infarction of the transplant, however, was not due to the discrepancy in size, since the arterial thrombus arose on the recipient hepatic artery where the vascular clamp had been applied. The cholecystcholedochostomy appeared satisfactory and well vascularized at the time of operation.

One patient (Case 4) was less ill than the others. The hepatocytoma was particularly difficult, but he withstood the operation extremely well.

We are in full agreement with Starzl *et al.* (1968b) that in humans it is unnecessary to shunt blood from the inferior caval and portal systems when the patient is anhepatic. It is, however, desirable to have two intravenous infusions set up in the superior vena caval system before clamping the inferior vena cava, so that the return of blood to the heart can be augmented should there be a precipitous fall in blood pressure.

At present we believe the most suitable cases for liver transplantation are patients with primary hepatic or biliary tract carcinoma and biliary atresia. Some idea of the number of such cases present in this country was obtained by Terblanche and Riddell (1967) from an analysis of the Registrar General's Statistical Review of England and Wales for the year 1964. There were 429 deaths from primary hepatic carcinoma and 1,070 deaths from primary biliary carcinoma (gall bladder and bile duct) for all age groups, with corresponding figures for those dying between 0 and 60 years of 145 and 195. Orthotopic transplantation of the liver is a major surgical procedure,

and it is unlikely that patients over the age of 60 will often be considered, in view of the high incidence of associated disease, particularly of the cardiovascular system. About 30% of primary hepatic tumours may have distant metastases by the time of diagnosis, and perhaps another third of such patients are treatable by hepatic lobectomy. Carcinomas of the hepatic and common bile duct are often slowly growing and metastasize late, so that about 130 to 160 patients from these two groups may be suitable for hepatic transplantation each year.

Biliary atresia, though rare, is another condition with an almost uniformly poor prognosis, in which the defect can rarely be corrected surgically. In the same year in the 0–60 age group there were 490 deaths from cirrhosis, 106 from acute viral hepatitis, and 54 from acute hepatic failure due to other causes, including drugs. All these are potential recipients, but the metabolic derangements of hepatic coma, the portal hypertension, and the frequently attendant renal impairment usually present in these patients are likely to increase the operative and immediate postoperative mortality considerably. Operating on patients with acute viral hepatitis may also carry grave dangers to the surgical and nursing teams.

With regard to the availability of donors in 1964 there were 1,135 deaths from subarachnoid haemorrhage and primary brain tumour and 2,478 from motor-vehicle accidents with a fractured skull or head injury in the 0–45 age group (Terblanche and Riddell, 1967). In both these groups some of the patients are likely to be maintained on respirators until the final demise. The patients dying in the older age groups carry a higher risk of their livers containing an occult secondary carcinoma. Despite an apparent adequate supply of donors, there will be major problems in organization for the individual patient, as already outlined. These problems will persist until organ preservation techniques have been developed, which will enable the donor liver to be preserved for periods of more than two to three hours.

Though the indications for liver transplantation will be widened in the future, at the present time the most suitable cases are adults with fatal hepatic disease who are too ill for an independent existence outside hospital, but have not yet reached a moribund stage.

We wish to thank our medical, nursing, and technical colleagues who have helped to initiate this transplantation programme. We have had most generous assistance from so many people that it would be invidious to mention individual names. We are particularly indebted to the anaesthetists, bacteriological, biochemical, pathological, haematological, radiological, and medical illustration departments of Addenbrooke's Hospital and King's College Hospital. We thank Mrs. M. Allen for preparing the drawings.

REFERENCES

- Brettschneider, L., *et al.* (1968). *Surg. Gynec. Obstet.*, **126**, 263.
- Calne, R. Y., *et al.* (1968). *Brit. med. J.*, **4**, 541.
- Moore, F. D., *et al.* (1960). *Ann. Surg.*, **152**, 374.
- Marchioro, T. L., Huntley, R. T., Waddell, W. R., and Starzl, T. E. (1963). *Surgery*, **54**, 900.
- Schalm, S. W. (1968). A Simple and Clinically Applicable Method for the Preservation of a Liver Homograft. Thesis, University of Leiden.
- Starzl, T. E., Kaupp, H. A., jun., Brock, D. R., Lazarus, R. E., and Johnson, R. V. (1960). *Surg. Gynec. Obstet.*, **111**, 733.
- Starzl, T. E., Marchioro, T. L., and Porter, K. A. (1966). *Advanc. Surg. (Chic.)*, **2**, 295.
- Starzl, T. E., Marchioro, T. L., Porter, K. A., and Brettschneider, L. (1967). *Transplantation*, **5**, 790.
- Starzl, T. E., *et al.* (1968a). *Ann. Surg.*, **168**, 392.
- Starzl, T. E., *et al.* (1968b). *Surgery*, **63**, 549.
- Terblanche, J., and Riddell, A. G. (1967). In *The Liver*, edited by A. E. Read, p. 321. London.

R. Y. CALNE AND ROGER WILLIAMS: LIVER TRANSPLANTATION IN MAN—I

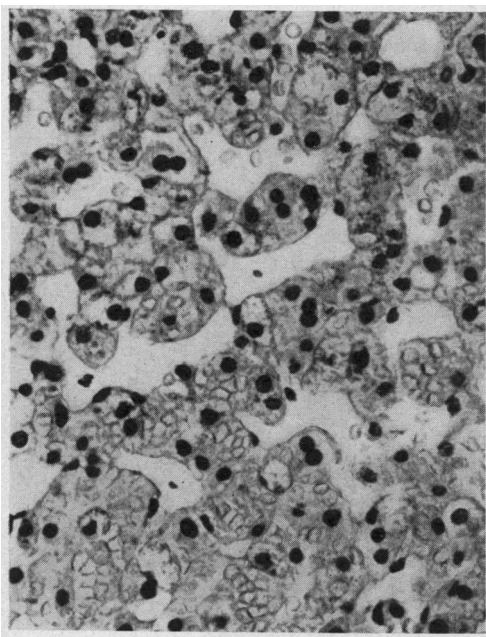


FIG. 2.—Biopsy of liver allograft in Case 1, showing degeneration of liver cells and intra-hepatic haemorrhage. ($\times 335$.)

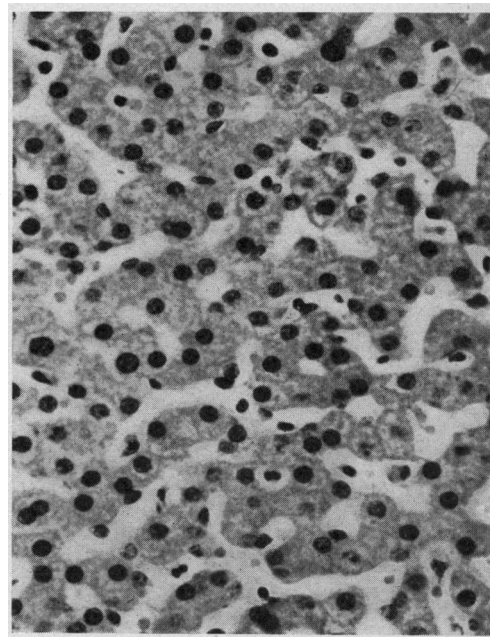


FIG. 8.—Operative biopsy of liver allograft of Case 4 at the time of transplantation, showing well-preserved liver parenchyma. (H. and E. $\times 335$.)

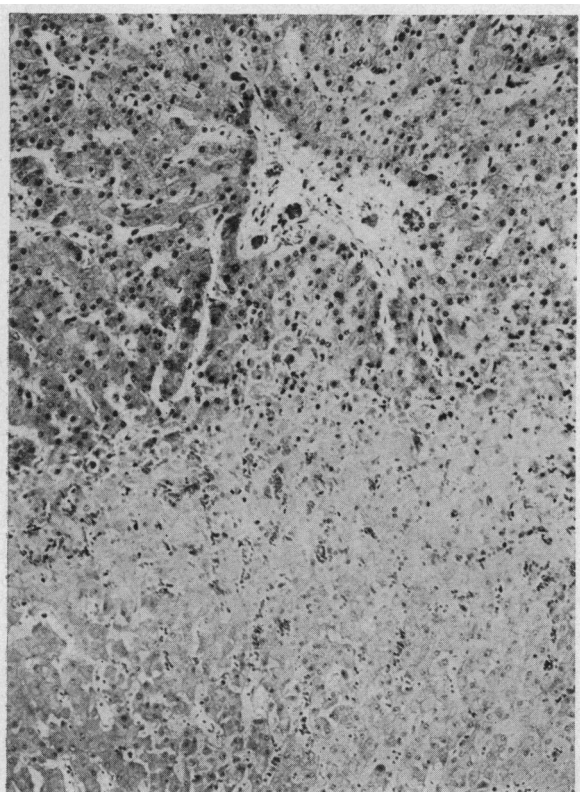
R. Y. CALNE *ET AL.*: LIVER TRANSPLANTATION IN MAN—II

FIG. 2.—Case 3. Microscopical appearance of allografted liver at post-mortem examination, showing well-preserved liver parenchyma above with no evidence of mononuclear cell infiltration or other stigmata of rejection, while the lower area shows necrosis characteristic of infarction. No cellular infiltration in portal tract. (H. and E. $\times 100$.)

FIG. 3.—Case 4. ^{99m}Tc sulphur colloidal scans. (A) Pre-operatively, showing a small area of liver with normal activity lying above the large epigastric mass which does not take up the colloid; and (B) postoperatively, showing that the liver size, shape, and position are normal. Splenic activity is slightly increased. The dots mark the outline of the nipples, costal margins, xiphisternum, and liver edge as palpated.

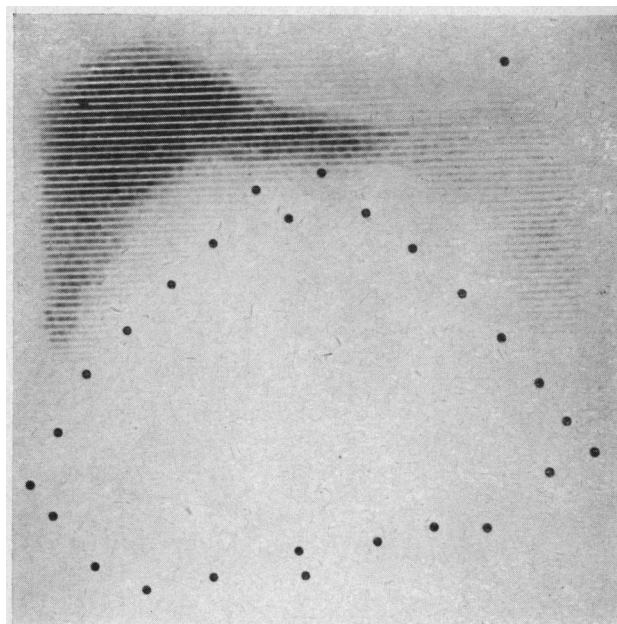


FIG. 3A

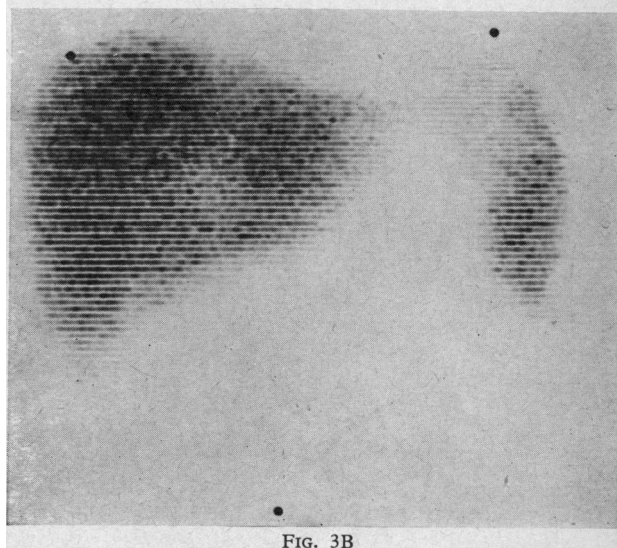


FIG. 3B