

ENDGAMES

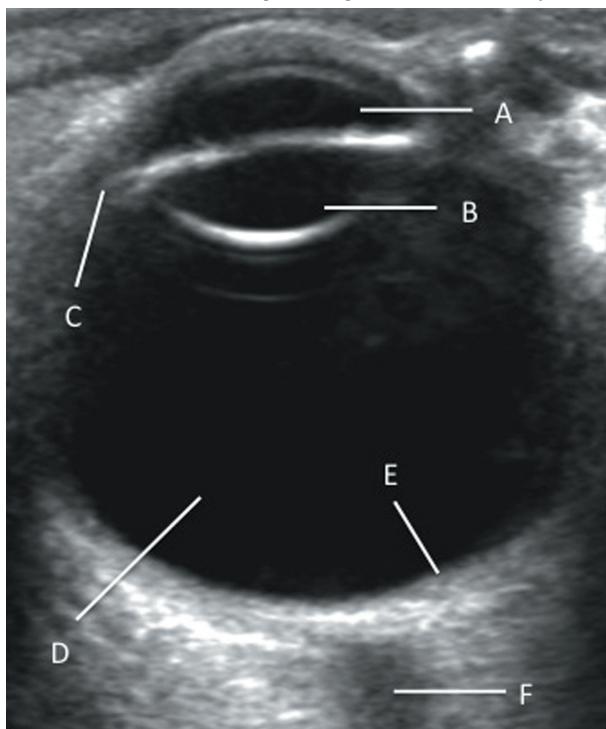
ANATOMY QUIZ

Transverse ultrasound image through the orbit

Sundip D Udani *senior radiology registrar*¹, Roger W Bury *consultant radiologist*²

¹Department of Clinical Radiology, North Western Deanery, Blackpool, Fylde and Wyre Teaching Hospitals, Blackpool FY3 8NR, UK; ²Blackpool, Fylde and Wyre Teaching Hospitals, Blackpool, UK

Identify the structures labelled A, B, C, D, E, and F in this transverse ultrasound image through the orbit of the eye.



Answers

- A: Anterior chamber
- B: Lens
- C: Ciliary body
- D: Vitreous body
- E: Posterior wall of globe
- F: Optic nerve

Cite this as: *BMJ* 2013;347:f6780

© BMJ Publishing Group Ltd 2013