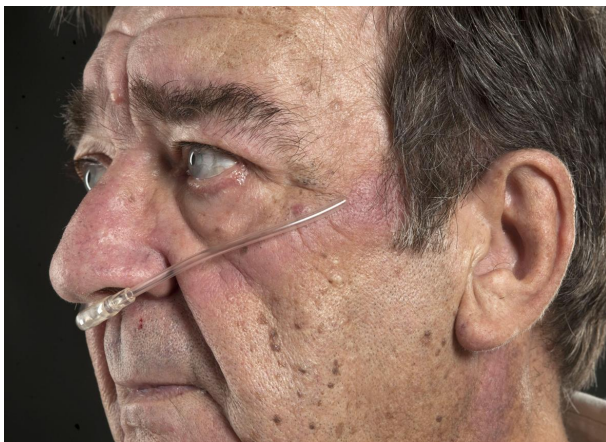


MINERVA

Olga Golberg *specialist registrar*, Robert Burd *consultant*, Graham Johnston *consultant*

Department of Dermatology, Leicester Royal Infirmary, Leicester LE1 5WW, UK



disease and was on long term oxygen treatment. Examination showed well defined, linear, erythematous scaly patches across his cheeks, behind his ears, and extending to the sides of his neck. The configuration of the skin lesions corresponded exactly to the course of the oxygen cannulae across his face. Irritant dermatitis occurs from direct chaffing of medical cannulae on the skin. Applying hypoallergenic tape to lessen the chaffing effect had a beneficial effect in this patient.

Patient consent obtained.

Cite this as: *BMJ* 2012;344:e3338

© BMJ Publishing Group Ltd 2012

A 73 year old man presented with itchy red scaly skin on his face and neck. He had a history of chronic obstructive airways