and presenting information for which the knowledge available is unclear, poorly defined, uncertain (for instance, the long term effects of the contraceptive pill in terms of risk of breast cancer or the problem of its interactions). An educational approach to possible lines of action in situations of uncertainty is indeed needed, both on the part of the public and of the doctors, together with a mechanism allowing the timely updating of information.

A systematic long term exercise in preparing and testing consumer oriented drug information should be given priority in the near future; it should not only be directed to avoid inappropriate and potentially dangerous drug use but also towards fostering a more conscious attitude with respect to drugs among the public. Community pharmacists represent an important resource in the promotion of educational practices; doctors, on their part, should be prepared to face and to encourage dialogue oriented relationships with patients.

Key participants in this study were:

Steering and coordination of the study:
Mauro Miselli, PHARMD, *clinical pharmacist*

Preparation of the report:
Mauro Miselli, PHARMD
Gianni Tognoni, MD (Laboratory of Clinical Pharmacology, Regional Centre for Drug Information)

Scientific advisory board:
A Del Favero, MD, M Miselli, PHARMD, N Montanaro, MD, G F Nasi, PHARMD, G Tognoni, MD, D Zanfi, PHARMD

We thank all of the pharmacists who joined the study, particularly Adalgisa Berti, Maurizio Casadei, Angela Castelli, Aldo Ceriotti, Daniela Chini, Bruno Collevasone, Elisabetta De Bastiani, Fabrizia Ferrarini, Gabriella Giovannardi, Olivia Grasselli, Claudio Lazzeri, Fiorita Lazzeri, Giancarlo Manfredotti, Franco Masi, Francesco Moretti, Manuela Mussio, Cecilia Ossicini, Ugo Perrucci, Giulia Reverberi, Tiziana Rigo, Luciano Segnini, Giorgio Tenucci, Rolando Tucci, and Elisabetta Vezzani. We also thank Franco Canovi and Ferdinando Morotto for their help with data input.

1 Strategie ed efficacia dell 'informazione sui farmaci. Proceedings of the International Meeting of the International Society of Drug Bulletins, Reggio Emilia, 7-8 April 1988. *Informazioni sui Farmaci* 1989;suppl 1:9-57.
2 Anonymous. Telling patients about their medicines [Editorial]. *Lancet* 1987;ii:1064.
3 Hermann F, Herxheimer A, Lionel NDW. Package inserts for prescribed medicines: What maximum information do patients need? *BMJ* 1978;ii:1132-5.
4 Johnson MW, Mitch WE, Sherwood J, *et al*. The impact of a drug information sheet on the understanding and attitude of patients about drugs. *JAMA* 1986;**256**:2722-42.
5 Ridout S, Waters WE, George CF. Knowledge of and attitudes to medicine in the Southampton community. *Br J Clin Pharmacol* 1986;**21**:701-12.
6 George CF, Waters WE, Nicholas JA. Prescription information leaflets: a pilot study in general practice. *BMJ* 1983;**287**:1193-6.
7 Herxheimer A. Regulatory approaches: the consumer viewpoint. In: Bogaert M, Vander Stichele R, Kaufman J-M, Lefebvre R (eds). *Patient package insert as a source of drug information*. Amsterdam: Excerpta Medica, 1988:73-6. (International congress series 853.)
8 Del Favero A. Il prontuario terapeutico del Servizio Sanitario Nazionale. *Informazioni sui Farmaci* 1983;7:141-9.
9 Gestione e verifica dell 'informazione sui farmaci nelle USSL. *Informazioni sui Farmaci* 1984;suppl 2:9-175.
10 Italian Drug Utilization Research Group. *Prontuario terapeutico commentato*. Rome: Il Pensiero Scientifico Editore, 1988.
11 Tognoni G. Cultura e politica dei farmaci. *Ricerca and Pratica* 1988;**23**:173-9.
12 Ehsanullah RSB, Page MC, Tildesly G, *et al*. Prevention of gastroduodenal damage induced by non-steroidal anti-inflammatory drugs: controlled trial of ranitidine. *BMJ* 1988;**297**:1017-21.

(Accepted 31 August 1990)

Everyday Aids and Appliances

Dentures

Oliver J Corrado

A quarter of all adults in Britain have no natural teeth. This proportion increases progressively with age to 65% of people aged 65-74 and 82% of those aged 75 and over.[1] Many people with partial or complete tooth loss can be helped by wearing dentures.

History

Fairly elaborate partial dentures were made by the Etruscans as early as 700 BC. Some were removable; others were fixed to neighbouring teeth. Subsequently, artificial teeth were made from ivory, wood, bone, silver, mother of pearl, enamelled copper, or porcelain. Even teeth from other humans have been used. Until the middle of the nineteenth century denture bases were generally made from gold or ivory, but these were superseded by vulcanite (rubber hardened with sulphur), which remained popular until the 1940s, when poly (methylmethacrylate) resin was used to construct teeth and bases. Some elderly people still possess vulcanite dentures—these can be recognised by their characteristic colours.

Classification of dentures

Dentures can be divided into two groups.[2] Complete dentures are designed to replace either the entire maxillary (upper) or mandibular (lower) dentitions. Most are made from acrylic resin but some incorporate metal palates (generally either cobalt-chromium alloy or stainless steel) when additional strength is required. Removable partial dentures are designed to replace missing teeth for partially edentulous patients and are made of acrylic resin or metal. Some are retained by physical forces such as adhesion and cohesion and by muscular control, but many incorporate mechanical devices (retainers) for this purpose. These include clasps, studs, and more elaborate locking mechanisms (fig 1).

An overdenture (overlay denture) is a removable denture (partial or complete) that is fitted over retained, prepared roots or natural teeth. Partial dentures and overdentures can be used as an interim step before complete dentures are fitted, enabling patients to

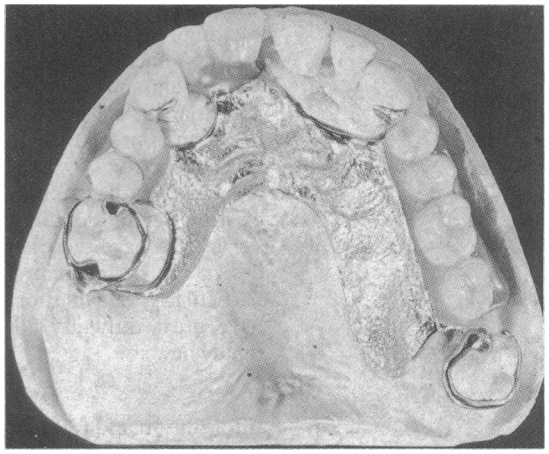

FIG 1—*Partial denture incorporating metal (cobalt-chromium alloy) retainers. Denture is mounted on plaster model*

Wharfedale General Hospital, Otley
Oliver J Corrado, MRCP, *consultant geriatrician*

Correspondence to: Dr O J Corrado, Department of Medicine for the Elderly, Chapel Allerton Hospital, Harehills Lane, Leeds LS7 4RB.

Series edited by: Professor Graham Mulley.

Br Med J 1990;**301**:1265-8.

BMJ: first published as 10.1136/bmj.301.6763.1265 on 1 December 1990. Downloaded from http://www.bmj.com/ on 19 April 2024 by guest. Protected by copyright.

gradually adapt to denture wearing. Partial and complete dentures may have to be modified to include an obturator, which is an extension of the denture base designed to fill a congenital defect (for example, cleft palate) or one that has been acquired (for example, after operation) (fig 2). The obturator improves speech, masticatory function, and appearance.

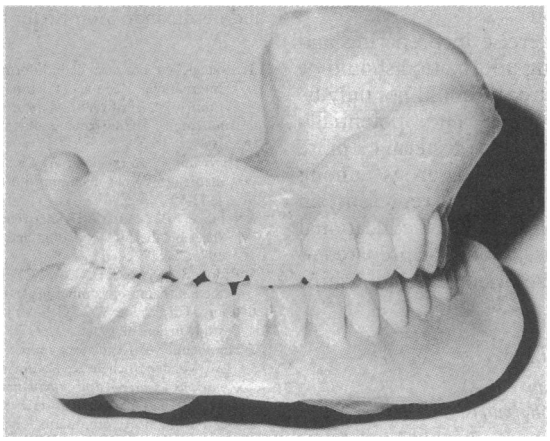

FIG 2—*Complete dentures supplied for a patient after maxillary surgery. Upper denture includes obturator on left side*

The first set of complete dentures

Patients used to wait several months after tooth extraction before complete dentures were fitted. This allowed the tissues to heal and much of the alveolar bone to resorb. Nowadays most patients have complete dentures fitted at the same visit as their remaining natural teeth are extracted (immediate dentures). This method is advantageous because it maintains dental and facial appearances, reduces masticatory and speech disturbances, facilitates adaptation to dentures, and allows the appearance of the natural teeth to be copied. Patients have to be monitored closely after immediate dentures are fitted as modifications will often be required.

To make the dentures, impressions are taken, casts made, and the correct anatomical relation of the upper and lower jaws recorded and reproduced. Trial dentures are formed on the casts with the artificial teeth positioned in wax and these dentures are tried in the patient. Tooth selection is important: artificial teeth come in a variety of shades, shapes, and sizes, and their incisal edges and surfaces have varying degrees of smoothness and regularity. The shade should complement the skin or complexion, and the shape should be appropriate for the patient's sex, facial structure, personality, and body build. Most teeth are made of acrylic resin and are attached to the denture base by chemical union. Sometimes porcelain teeth attached to the base by pins are used: these are harder wearing, but may make more noise and chip more easily. Whichever material is used the arrangement should look natural: if too perfect, the teeth may appear artificial (fig 3). When the cosmetic appearance has been approved the trial dentures are processed in acrylic resin.

Patients with symptoms of recent onset who have an existing set of dentures that has given satisfactory service can have these copied; fairly minor changes in design can be made on the copies. This technique is particularly valuable for elderly patients, who might have great difficulty adapting to and controlling a totally new s-

Information and follow up

Patients should be advised about oral hygiene and denture care at the time of fitting and also given written information about eating, cleaning, controlling, and possible problems.[3] Providing written information helps to prevent unnecessary difficulties. Recommendations regarding the review of patients fitted with dentures vary. Patients fitted with partial dentures and overdentures should be seen at intervals of about six months to monitor oral hygiene and to undertake regular maintenance of the remaining teeth and associated periodontal tissues. Immediate dentures often require early modification, and patients should be seen frequently over the first three months (for example, after 24 hours, one week, two weeks, one month, and three months) and annually thereafter. Patients with complete dentures should have a routine check every three to five years.

Patient satisfaction

The principal objectives in denture construction are that: facial appearance and shape should be restored and the artificial teeth should appear attractive and natural; the denture should be as well retained and as comfortable as the remaining oral structures allow; the denture should permit a satisfactory level of function; and the denture should not damage supporting tissues.

The patient's attitude greatly influences the success of dentures.[4] Natural tooth loss may be associated with a mild grief reaction: this was found in half the wearers of complete dentures and more commonly in women than men.[4] Successful prosthetic treatment depends on good relation between the patient, dental surgeon, and dental technician. With time 70% of patients accept complete dentures as part of themselves, and 75% feel awkward about being seen without them.[4] Many patients are quite satisfied with dentures that are judged by dental surgeons to be less than satisfactory. Equally, some patients have the greatest difficulty in accepting dentures that have been designed and constructed to the highest standards.

Denture problems

Systemic disease may predispose to denture problems. For example, diabetes is associated with an increased incidence of oral candidiasis. Xerostomia, which commonly occurs as a side effect of drug treatment, may make it more difficult to retain dentures and cause excessive mucosal irritation because of reduced salivary lubrication. Problems are more common with complete dentures. Sheppard *et al* found denture related oral lesions in almost half of patients.[5]

Pain is a common symptom in wearers of complete dentures and may be caused by small or large defects in denture design, problems in the denture bearing tissues, or as a consequence of systemic disease. Mandibular parafunction not infrequently contributes to the complaint. Patients should be encouraged to seek advice from their dental surgeon and must be discouraged from trying to treat themselves with "over the counter" products.

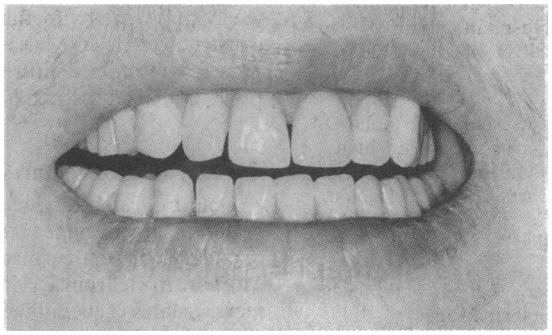

FIG 3—*Variation in tooth alignment to create a more natural appearance in complete dentures*

BMJ: first published as 10.1136/bmj.301.6763.1265 on 1 December 1990. Downloaded from http://www.bmj.com/ on 19 April 2024 by guest. Protected by copyright.

Loose dentures—Alveolar resorption occurs with time and causes dentures to lose their fit (fig 4). This happens much less commonly with the type of partial denture that is supported by the remaining natural teeth. The problem occurs most often in the lower edentulous jaw, which resorbs about four times faster than the upper. If the problem is related to the fitting surface of the denture, the fit may be improved by relining or rebasing the denture. An immediate denture usually needs to be rebased in the first few months after the last teeth were extracted. As with the complaint of pain, the aetiology is diverse and correct treatment depends on an accurate diagnosis.

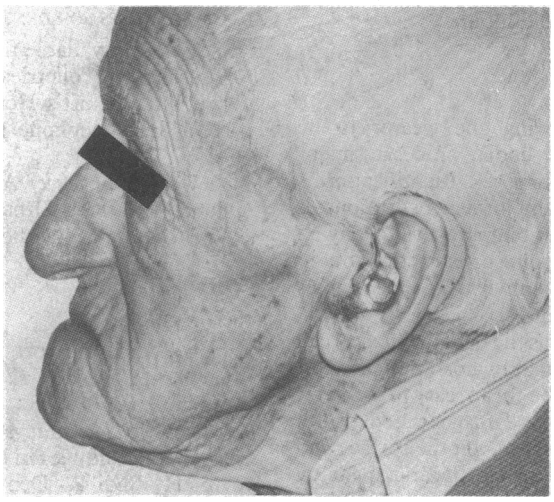

FIG 4—*Altered facial appearance due to ill fitting complete dentures resulting in loss of facial height and protrusion of mandible*

Denture stomatitis is an inflammatory condition affecting the oral mucosa covered by the denture. It occurs in up to 60% of denture wearers, is commoner in the upper jaw and in women, and is generally painless. The condition may be caused by infection (particularly candidiasis) or denture trauma and may be complicated by systemic problems. It is therefore important to establish the correct diagnosis so that appropriate treatment can be given. Where there is an infective component a fungicide is often unnecessary as the condition will often resolve when plaque on the denture surface is controlled with hypochlorite denture cleansing solution. Chemical irritation from mouthwashes, ointments, pastes, fixatives, and chemical constituents in the denture material may also cause stomatitis. Pain or discomfort is usually a component of stomatitis arising from these causes.

Angular stomatitis (cheilosis) is an erythematous condition of the angles of the mouth; it is usually bilateral (fig 5) and is often associated with an infective denture stomatitis. Creasing of the skin at the mouth angles, which is a contributory factor, may indicate poor lip support by the dentures, but this creasing may result from an age related loss of muscle tone.

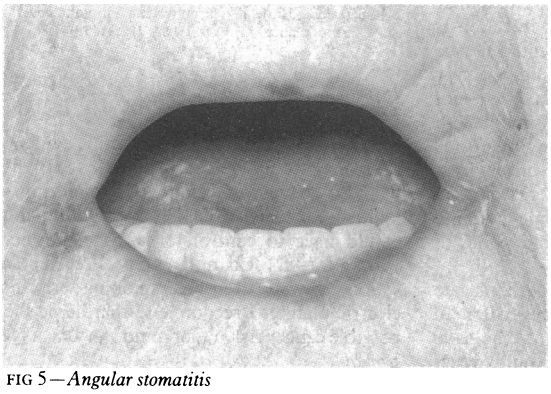

FIG 5—*Angular stomatitis*

Papillary hyperplasia—Irritation of the palatal mucosa by the denture may produce mucosal hyperplasia, which may be associated with denture stomatitis. Treatment should include denture hygiene and reducing denture trauma, sometimes by constructing a new denture with a smoother fitting surface. As for denture stomatitis, dentures should not be worn at night.

Denture trauma may produce bands of fibrous tissue, commonly in the labial sulci. This condition is often painful at first, and it may be associated with ulceration, but patients often put up with the discomfort and allow the trauma to produce the relatively painless hyperplasia. Poorly fitting dentures should be adjusted and occlusal abnormalities corrected. Excision of the tissue may be required, in which case the specimen should be sent to an oral pathologist for examination.

Excessive salivation and impaired speech—Excessive salivation may occur for a few days after a new denture has been fitted, but it will settle. Similarly, some difficulty with speech may be encountered until patients adapt to denture wearing; persisting speech disturbance needs to be investigated.

Chewing—The chewing efficiency of a wearer of complete dentures is about a fifth of that of people with natural dentition. Patients may encounter difficulty eating crisp foods such as apples, and a third of wearers of complete dentures have to avoid certain foods. Patients with new dentures should be advised to cut food up into small pieces, to eat soft foods at first, and to distribute food equally on both sides of the mouth. As muscular control improves in the first few weeks, so does chewing efficiency.

Denture fixatives

Many denture wearers purchase fixatives to improve retention. Bates and Murphy found that a tenth of denture wearers had used these at some time.[6] Fixatives are available as powders, pastes, liquids, and adherent bandages[7]; common ingredients are karaya gum or tragacanth gum, which become gelatinous with water. Fixatives can help retain immediate or new dentures in the short term, help retain obturators, and aid denture rentention when physiological factors are suboptimal —for example, when there is xerostomia.[7] Fixatives should not be used without professional advice because they may hide a problem that may lead to further resorption of the underlying bone.

Denture hygiene

Half of denture wearers clean their dentures inadequately (fig 6). Poor denture hygiene allows plaque to develop, leading to halitosis and predisposing to denture stomatitis. The problem is particularly important with partial dentures as plaque will lead to periodontal disease and dental caries. Dentures should be removed at night to let the oral tissues rest. Denture cleansers include alkaline hypochlorite solutions, alkaline peroxides available as soluble powders or

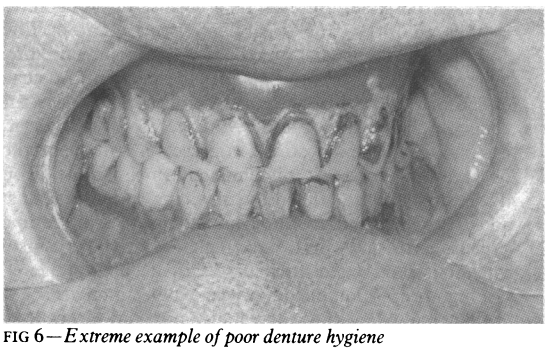

FIG 6—*Extreme example of poor denture hygiene*

BMJ: first published as 10.1136/bmj.301.6763.1265 on 1 December 1990. Downloaded from http://www.bmj.com/ on 19 April 2024 by guest. Protected by copyright.

tablets, acid solutions, antibacterial and enzymatic preparations, and pastes with varying abrasion. Hypochlorite solutions are highly effective at removing plaque and are probably the cleanser of choice,[2] but they may corrode metal.

Harrison has recommended the following cleaning procedure.[2] The denture should be brushed with a soft toothbrush and soap and water. This should be done over a full washbasin or bowl of water to reduce the chance of damage if the denture is dropped. After rinsing the denture should be soaked in an alkaline hypochlorite solution overnight to reduce plaque; if the denture incorporates metal it should be immersed for no longer than 30 minutes in solution of the manufacturer's recommended dilution.

Denture identification

Identification marks allowing the wearer to be identified may be useful in coma, amnesia, major disasters, and for forensic purposes. Identification is also valuable in hospitals and other institutions if dentures are misplaced or lost temporarily. Ideally all dentures should be marked during construction, but in Britain this is done routinely only by the armed forces and by certain dental laboratories.

Identification marks (such as the patient's name) can be applied to the denture surface by hospital staff. The ideal marking system should be cheap, easy to perform, and durable and should not damage the denture. Identification marks can be written on the surface and then coated with a protective sealant. Marks made by spirit pens are not very durable. A commercial denture marking kit (see below) includes an abrasive pad to clean and roughen the surface of the denture, a marking pencil, and sealant; the marks remain legible for about six months.[2]

The loss of a set of dentures belonging to an elderly person is often a major problem. Advanced age and deteriorating health may make it impossible for the patient to learn to control new shapes. Providing replacement dentures is not a simple procedure. The message should be clear—prevention is better than cure.

I thank Professor R M Basker, professor of dental prosthetics and consultant in restorative dentistry, University of Leeds, for advice; Mr B R Nattress, lecturer in restorative dentistry, University of Leeds, for supplying figure 2; and the photographic departments of the Leeds General Infirmary and School of Dentistry.

Appendix

USEFUL INFORMATION

Identure Marking Kits cost about £31.50 (including VAT). Information of local suppliers can be obtained from: Dental Products Group, 3M Health Care Ltd, 3M House, 1 Morley Street, Loughborough LE1 1EP (telephone: 0509 611611).

ADVICE LEAFLETS FOR DENTURE WEARERS

Keep Smiling. Available from: The Product Manager, Household Toiletries Division, Reckitt and Colman, Reckitt's House, Stoneferry Road, Hull HU8 8BD (telephone: 0482 26151).

Smile With Confidence. Available from: The Professional Relations Officer, Stafford-Miller House, The Common, Hatfield AL10 0NZ (telephone: 0707 261151).

FURTHER READING

Basker RM, Davenport JC, Tomlin HR. *Prosthetic treatment of the edentulous patient*. London: Macmillan, 1983.

Woodforde J. *The strange story of false teeth*. London: Routledge and Kegan Paul, 1968.

Devlin H, Bedi R. Denture use and abuse. *Dental Update* 1988;March:78-80.

Abelson DC. Denture plaque and denture cleansers: review of the literature. *Gerodontics* 1985;**1**:202-6.

1 Office of Population Censuses and Surveys. The 1983 update on adult dental health from OPCS. *Br Dent J* 1986;**160**:246-53.
2 Harrison A. Denture care. *Nursing Times* 1987;**83**:28-9.
3 Wendt DC. How to promote and maintain good oral health in spite of wearing dentures. *J Prosthetic Dent* 1985;**53**:805-7.
4 Berg E, Ingebretsen R, Johnson TB. Some attitudes towards edentulousness, complete dentures and cooperation with the dentist. *Acta Odontol Scand* 1984;**42**:334-8.
5 Sheppard IM, Schwartz LR, Sheppard SM. Oral status of edentulous and complete denture-wearing patients. *J Am Dent Assoc* 1971;**83**:614-20.
6 Bates JF, Murphy WM. A survey of an edentulous population. *Br Dent J* 1968;**124**:116-21.
7 Polyzois GL. An update on denture fixatives. *Dental Update* 1983;October:579-83.

ANY QUESTIONS

What prophylactic chemotherapy, if any, is recommended for a patient with a prosthetic joint replacement who is having dental treatment?

Antibiotic prophylaxis against bacteraemia of oral origin is of questionable value as a means of reducing the incidence of late infection of hip prostheses. Reports of infection after dental manipulation are unconvincing as most of the organisms could equally well have come from other sites. There is one account of infection with *Actinomyces israelii*, a specific oral organism, occurring within four weeks of dental treatment, but the authors cite similar infection in the absence of dental disease.[1] Haematogenous infection is therefore possible, but even on a balance of probabilities it could not be established that dental treatment was the cause. Interestingly, many American orthopaedic surgeons who recommend prophylaxis do not believe that dentistry is a cause of hip infection.[2] An analogy is made with endocarditis, but it is weak as the sites of infection and the organisms concerned are quite different. Furthermore, the efficacy of prophylaxis against viridans endocarditis is based on tenuous argument rather than observation. The most influential arguments in its favour come from the discreditable area of defensive medicine, and it is against public policy to add yet another doubtful indication for prescribing antibiotics.

Common sense would suggest that if oral organisms were a threat late infection would be seen much more often. This argument holds even if there is a high proportion of edentulous people among those patients who have implants simply because of their high number. Moreover, you would expect that plates and pins used extensively to treat fractures would also be susceptible, but in fact there is no recognised clinical problem. Those recommending prophylaxis should, to be consistent, also assess their patient's dental health preoperatively. There is no evidence from published reports or personal experience that this is done.—A J MacGREGOR, *reader in oral surgery, Leeds*

1 Strazzeri JC, Anzel A. Infected total hip arthroplasty due to Actinomyces israelii after dental extraction: a case report. *Clin Orthop* 1986;**210**:128-31.
2 Jaspers MT, Little JW. Prophylactic antibiotic coverage in patients with total arthroplasty; current practice. *J Am Dent Assoc* 1985;**111**:943-8.

Is there any evidence that electric blankets are carcinogenic?

I know of no soundly based scientific evidence that even remotely suggests that there could be a cancer risk from the use of electric blankets. It would need a dedicated epidemiologist to want to compare cancer incidence in electric blanket users with that in non-user controls; he or she would have to control for a large number of potentially confounding variables —for example, body size, diet, ambient temperature, other sources of warmth in bed, smoking, etc. If someone enjoys the use of an electric blanket I recommend that he or she does so and puts all fears of possible cancer risk out of mind.—FRANCIS J C ROE, *consultant in toxicology, London*

BMJ: first published as 10.1136/bmj.301.6763.1265 on 1 December 1990. Downloaded from http://www.bmj.com/ on 19 April 2024 by guest. Protected by copyright.