

the meninges and abducens nerve on its long intracranial course.

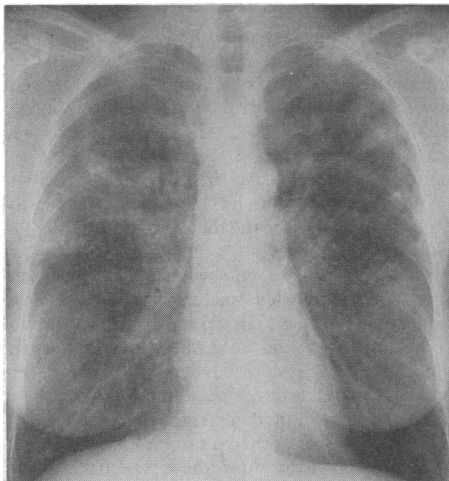
The sixth nerve occupies a superficial position in relation to the fourth ventricle, which communicates directly through the foramina of Magendie and Luschka with the subarachnoid space. Dye studies have shown that agents introduced into the spinal canal frequently reach the medulla, which may explain the peculiar affinity of the sixth nerve to palsy.⁴

The contrast agents introduced in the procedure of myelography have a toxicity of their own, and the incidence of cranial nerve palsy is higher than after merely dural puncture.⁵ This may be due to a previously unreported direct neurotoxicity of the contrast agent iopamidol itself.

- 1 Lamb JT. Iohexol versus iopamidol for myelography. *Invest Radiol* 1985;20(suppl):537-43.
- 2 Wallers K, Chaudhuri AKR. Severe meningeal irritation after intrathecal injection of iopamidol. *Br Med J* 1985;291:1688.
- 3 Robinson C, Fon G. Adverse reaction to iopamidol. *Med J Aust* 1986;144:553.
- 4 Fawcett KR. Extraocular muscle paralysis following spinal anaesthesia. *Minn Med* 1931;14:648-9.
- 5 Fincham RW, Joynnt RJ, Skultety FM. Neurological deficits following myelography. *Arch Neurol* 1967;16:410-4.

Hypersensitivity pneumonitis induced by trimethoprim

Drs T HIGGINS (Department of Paediatrics) and P M NIKLASSON (Department of Infectious Diseases, Växjö County Hospital, S-385 17 Växjö, Sweden) write: We report on a patient who developed hypersensitivity pneumonitis induced by trimethoprim. A 43 year old woman with no history of allergy received a 25 day course of trimethoprim 100 mg/day in February 1989 for recurrent urinary tract infection. A new course was begun in September 1989. Four weeks later she presented with a two week history of a severe hacking cough and a five day history of fever, muscle pain, nausea, and headache. No other medications had been taken. The chest radiograph showed a nodular pattern of opacities (figure).



Chest radiograph showing nodular pattern of opacities

Myoplasmal pneumonia was tentatively diagnosed and a 10 day course of erythromycin succinate 500 mg twice daily was prescribed and trimethoprim withdrawn. Three days later the patient felt well and restarted prophylaxis with trimethoprim. Within eight hours of taking one tablet she developed a temperature of 39.5°C, an incessant cough, muscular pains, and joint pain. Investigations showed a white cell count of $8.3 \times 10^9/l$ with 11% eosinophilia and moderately raised liver enzyme activities. Trimethoprim and erythromycin succinate were withdrawn and the patient was prescribed a 10 day course of doxy-

cline 100 mg/day. She improved rapidly. The chest radiograph, the liver enzyme activities, and the differential blood count were normal three weeks later. Paired sera analysed for antibodies to viral pathogens, ornithosis, *Mycoplasma pneumoniae*, and toxocara gave negative results. A nasopharyngeal culture was negative. No cysts or ova were found in three examinations of the stools.

We believe that our patient had hypersensitivity pneumonitis induced by trimethoprim because the symptoms vanished when trimethoprim was withdrawn and reappeared when it was restarted and there were pulmonary infiltrates similar to those seen in Loeffler's syndrome, transient eosinophilia, and a lack of evidence of infectious disease. A rechallenge would have provided definitive proof but was deemed unethical. Rash is a common adverse reaction associated with trimethoprim. The British Committee on the Safety of Medicines has received reports of bronchospasm and dyspnoea in connection with trimethoprim. Neither the Swedish Advisory Committee of Adverse Drug Reactions, the Committee on Safety of Medicines, nor the manufacturer (Astra, Sweden) has received reports of hypersensitivity pneumonitis in connection with trimethoprim.

Interstitial nephritis associated with indapamide

Drs C G NEWSTEAD, R H MOORE, and A J BARNES (The London Hospital, London E1 1BB) write: Acute interstitial nephritis secondary to thiazide diuretics has been reported, but it has not been reported with the new generation of thiazides. We report a case of tubulointerstitial nephritis leading to acute renal failure associated with the use of indapamide.

A 74 year old man had been taking digoxin 0.0625 mg and one tablet of Navidrex-K (cyclopenthiiazide 250 µg and potassium 8.1 mmol) every morning for four years following a diagnosis of hypertension. He visited his general practitioner 35 days before admission complaining of lethargy. The dose of digoxin was doubled, and indapamide 2.5 mg every morning was substituted for Navidrex-K. Seventeen days later he developed a generalised purpuric urticarial rash. This was attributed to the indapamide, which was stopped. The rash resolved over three days. The following week the patient noticed a diminution in his urine volume, as well as progressive fatigue and anorexia. Five days before admission he developed a chest infection, which was treated with ciprofloxacin 250 mg twice daily. On admission he was clinically acidotic and uraemic. Investigations showed haemoglobin 121 g/l, bicarbonate 9 mmol/l, potassium 5.5 mmol/l, phosphate 2.99 mmol/l, urea 75.6 mmol/l, creatinine 1819 µmol/l, and 24 hour protein excretion 0.74 g, and ultrasound showed normal sized non-obstructed kidneys. No casts or eosinophils were seen in the urinary deposit. Later a percutaneous renal biopsy showed increased fibrosis in the interstitium with a patchy infiltrate of lymphocytes and occasional polymorphs; immunofluorescence gave negative results.

On admission probable acute tubulointerstitial nephritis was diagnosed. Haemodialysis was started and he was treated with prednisolone 60 mg every morning and cimetidine 200 mg twice daily; all other drugs were withdrawn. The patient required haemodialysis for eight days; his creatinine concentration subsequently fell to 130 µmol/l.

Acute interstitial nephritis has been described after treatment with thiazide drugs¹ but no cases of interstitial nephritis due to indapamide are known to the manufacturers or to the Committee on Safety of Medicines. Hypokalaemia is the most frequent problem observed with this drug,² and in one case of profound hypokalaemia in a 39 year old man there were also electrocardiographic changes,

renal casts, marked muscular weakness, and proteinuria. Renal function, however, was normal.⁴

In this case the patient was admitted to hospital in a state of advanced uraemia, and a renal biopsy confirmed the clinical diagnosis of tubulointerstitial nephritis. There was no evidence of infection or obstruction or of multisystem or immunological disease. There was no history of exposure to toxins apart from drugs. Several features suggest that indapamide was responsible. The patient had been taking an alternative thiazide diuretic (cyclopenthiiazide) for four years without any side effects; the urticarial rash developed 17 days after he started indapamide and resolved after he stopped this drug; the improvement in the rash occurred while digoxin was continued at the same dose. The history suggested that the renal disturbance had antedated the admission by two weeks, some nine days before first exposure to ciprofloxacin, and the degree of kidney disturbance on admission was too profound to have been caused by ciprofloxacin started only five days earlier. Thus the clinical evidence points to an acute drug induced hypersensitivity reaction secondary to indapamide being responsible for this patient's acute renal failure.

- 1 Anonymous. Case records of the Massachusetts General Hospital: progressive azotemia in an elderly hypertensive man. *N Engl J Med* 1983;309:970-8.
- 2 Pusey CD, Saltissi D, Bloodworth L, Rainford DJ, Christie JL. Drug associated acute interstitial nephritis: clinical and pathological features and the response to high dose steroid therapy. *Q J Med* 1983;52:194-211.
- 3 Thomas JR. A review of 10 years' experience with indapamide as an antihypertensive agent. *Hypertension* 1985;7:11-152.
- 4 Di Giacomo V, Tedeschi A. Grave episodio ipocalcemicico indotto da abuso di fluoroprednisolone acetato per via nasale e contemporanea assunzione orale di indapamide. *Clin Ther* 1985;112:163-7.

Mononeuritis multiplex associated with prolonged vancomycin treatment

Drs G LEIBOWITZ, D GOLAN, D JESHURUN, and M BREZIS (Department of Medicine, Hadassah University Hospital-Mt Scopus, Jerusalem, Israel) write: Vancomycin is the antibiotic of choice for methicillin resistant staphylococci and has relatively few side effects (fever, phlebitis, allergic reactions, ototoxicity, and neutropenia¹). We recently observed a patient with severe peripheral nerve toxicity after prolonged vancomycin administration. After mitral valve replacement a 49 year old woman developed methicillin resistant staphylococcus septicaemia from a sternal wound infection. Her fever rapidly remitted on vancomycin treatment, which was continued for several weeks for suspected endocarditis. Serum concentrations of vancomycin were therapeutic. The only other medications were warfarin and diuretics, which she had been taking for many years. After a month on vancomycin she complained of tinnitus and weakness of her right leg. She remained afebrile, and neurological examination showed foot drop of her right leg. Nerve conduction studies confirmed right peroneal nerve block and disclosed bilateral partial block of the tibial nerves, consistent with mononeuritis multiplex. On discontinuation of vancomycin the tinnitus resolved but the foot drop persisted.

Vancomycin can cause vestibular toxicity, but peripheral neuropathy has not been reported. Although vancomycin can, rarely, induce a vasculitis,^{2,3} mononeuritis multiplex has not been observed. Our patient showed no evidence of systemic vasculitis. We conclude that peripheral neuropathy may be an additional adverse effect of vancomycin.

- 1 Levine JF. Vancomycin: a review. *Med Clin North Am* 1987;71:1135-45.
- 2 Markman M, Lim HW, Bluestein HG. Vancomycin-induced vasculitis. *South Med J* 1986;79:382-3.
- 3 Rawlinson WD, George CR. Vancomycin-induced vasculitis. *Med J Aust* 1987;147:470.