

Papers and Originals

Neonatal Hirschsprung's Disease

G. C. FRASER,* M.B., F.R.C.S., F.R.C.S.ED.; A. W. WILKINSON,† CH.M., F.R.C.S., F.R.C.S.ED.

Brit. med. J., 1967, 3, 7-10

During the 18 years since Swenson and Bill (1948) first showed that Hirschsprung's disease could be cured by resection of the abnormally innervated distal segment of rectum and colon the clinical status of the disease has been transformed. Though the early onset of the clinical disturbance in Hirschsprung's disease has been repeatedly emphasized, the diagnosis was seldom made or the disease treated in the early days or weeks of life (Forshall, 1964). It seems likely that formerly many of the babies born with this disease died undiagnosed within a few weeks or months of birth. Bodian *et al.* (1949) and Eek and Knutrud (1962) estimated that the mortality in the first year was 50%. Most of these children probably died of gastroenteritis superimposed on the intestinal obstruction caused by the unrecognized aganglionosis.

Hirschsprung's disease has long been associated clinically with the picture of a young child with chronic or occasionally intermittent but severe constipation, accompanied by progressive distension of the abdomen and a striking failure to thrive. In the few survivors this led eventually to the classical form of the disease still described in many textbooks—a child with wasted limbs and a wizened face looking anxiously over the top of a huge belly packed with hard masses of faeces. Such children were often the survivors of regimens of repeated bowel washouts and constant purgation, and were poor subjects for radical surgical treatment.

The aganglionosis of Hirschsprung's disease affects the developing lower bowel at a very early stage (Bodian and Carter, 1963). That some degree of intestinal obstruction has been present for weeks before birth is indicated by the hypertrophy of the intestinal muscle of the transitional segment and the most distal part of the normally innervated segment. This hypertrophy may be readily seen at operation just after birth. With few exceptions the clinical features on which a diagnosis of Hirschsprung's disease can be made are evident within a day or two of birth (Forshall, 1964). One consequence of the increased interest in neonatal disorders during the past 10 years has been the recognition that Hirschsprung's disease is much commoner than had been suspected.

This report is based on a review of 54 babies (44 boys, 10 girls) who were admitted to the Hospital for Sick Children between 1 January 1958 and 31 December 1965, and who were under the age of 1 month on admission. The diagnosis of Hirschsprung's disease has been confirmed by histological evidence in every case. Only 36 patients survived their initial admission, a mortality of 33%. The birth weight was known in 53 patients (Fig. 1), of whom 22 weighed more than 3.5 kg. (7½ lb.), and 6 (27%) of these died, whereas 11 died of

the 31 who weighed less than 3.5 kg. (7½ lb.) and 8 of the 12 who weighed less than 3 kg. (6½ lb.). Age on admission varied from a few hours to 28 days, but this did not seem to have any relation to mortality, because the average age on admission of babies who died was 12 days and of the survivors 10 days.

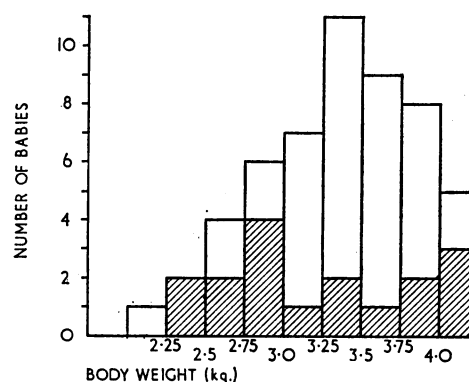


FIG. 1.—Birth weight in 53 cases. Cross-hatched squares indicate patients who died.

The lesions extended proximal to the pelvic colon ("long segment") in 12 babies, of whom 8 (66%) died, whereas of the 42 patients in whom only a short segment was involved 10 (24%) died.

Clinical Features

When Forshall (1964) reviewed a group of children of all ages with Hirschsprung's disease she found that four main clinical features were common in the neonatal period—vomiting, abnormality of bowel habit, abdominal distension, and reluctance to feed. In addition to these features the general appearance also may be characteristic. The face is thinner than normal and wrinkled; the skin looks dull and grey and feels limp even when the baby is only 2 or 3 days old and vomiting has not been so severe as to cause dehydration. The neonate with Hirschsprung's disease may have a worried or frowning appearance, which, combined with thin features, makes the baby look like a little old man. Often the baby is irritable and the head may be rolled from side to side. Abdominal distension may hinder the normal respiratory excursion, and breathing may be rapid and grunting in character.

Vomiting was recorded in 53 cases (98%). Persistent vomiting, especially when the vomitus was bile-stained, usually led to prompt referral to hospital, but this did not affect the mortality rate, because 7 died of the 23 patients in whom vomiting began on the first day, and 11 died of the 31 who began to vomit later (Fig. 2).

* Formerly Resident Assistant Surgeon, the Hospital for Sick Children, Great Ormond Street, London W.C.1. Present address: Department of Surgery, Health Centre for Children, Vancouver General Hospital, Vancouver, B.C., Canada.

† Nuffield Professor of Paediatric Surgery, the Institute of Child Health (University of London); Surgeon, the Hospital for Sick Children, Great Ormond Street, London W.C.1.

Abnormality of bowel habit was noted in 49 patients and was an even more common disturbance on the first day of life (28 cases) than was vomiting (Fig. 2). It was usually first manifest by the failure to pass normal meconium. Subsequently stools might be infrequent, abnormal in colour, loose, or offensive.

Abdominal distension was recorded in 51 patients (94%) and appeared in the first three days in 31 (60%) out of 51, most commonly on the second day of life (Fig. 2). The mortality was not closely related to the time of onset of distension.

Failure to progress is difficult to define, and its recognition may depend a good deal on the vigilance and experience of the nursing staff and the clinician. The main features are reluctance to feed or a poor performance during feeding, listlessness, irritability, and a failure to gain weight satisfactorily. This type of disturbance was found in 40 patients (74%) (Fig. 2), and the observation was often first made by the nursing staff, nearly always during the first week of life.

It is usually said that on rectal examination the anal canal and rectum feel narrow and grip the finger. As the finger is withdrawn it may be followed by a forcible gush of flatus and liquid offensive pale faeces. These features are not always present, especially when the rectum has already been examined in this way on several occasions, and their absence does not exclude the diagnosis.

Confirmation of Diagnosis

So far the clinical features of the disease have been emphasized because the early diagnosis of Hirschsprung's disease in the neonatal period mainly depends on awareness of them and their recognition. Some support for this provisional diagnosis may come from a radiograph of the abdomen with the baby in the erect position, and in sufficiently fit babies it can be confirmed by x-ray examination after a barium enema. A radiograph taken with the baby erect will usually show the degree and distribution of gaseous distension of the intestine; further useful information may be obtained from a lateral erect exposure, since this often shows more clearly how far down into the colon and rectum the gaseous distension extends. In a neonate with a distended abdomen absence of gas from the pelvis, especially on an erect lateral radiograph, is suggestive of Hirschsprung's disease.

In the present series 27 patients were x-rayed after a barium enema, some in the first two or three days of life. The diagnosis of Hirschsprung's disease was correctly made in 24

instances, in one the appearances were equivocal, and in the remaining two patients the diagnosis was incorrect, but in both of them the rectum had been washed out before the barium examination. No complications were associated with the radiological examination in these 27 patients. The diagnosis may also be confirmed by histological examination of a biopsy specimen taken from the aganglionic bowel. Biopsy specimens were taken from the rectum in 21 patients in this series, of whom two died of peritonitis due to perforation during or soon after the biopsy was done.

Cause of Death

The causes of death of the 18 babies are shown in the Table. One (Case 5) was dead on arrival at the hospital and three (Cases 6, 7, and 11) were very ill when admitted. Some kind of severe infection occurred in all but one (Case 16), but in eight of these it was a direct consequence of the surgical treatment. In two patients (Cases 1 and 2) peritonitis was due to the bowel being perforated while the rectum and colon were being washed out, and in two others (Cases 3 and 4) peritonitis was secondary to perforation during or soon after diagnostic rectal biopsy. Five patients (Cases 5, 6, 7, 8, and 9) died of enterocolitis. One of these was dead on arrival at hospital with peritonitis due to perforation of the ascending colon secondary to enterocolitis. Two others (Cases 6 and 7) arrived already very ill with enterocolitis and survived colostomy for only a few hours. In two others (Cases 8 and 9) enterocolitis developed after the institution of a colostomy for the relief of low obstruction. Another child (Case 10) died of gangrene of the jejunum and ileum of uncertain cause 30 hours after an ileostomy had been made for relief of a long-segment obstruction.

A long segment of the bowel (more than the rectum and pelvic colon) was involved in 12 of the 54 patients of this series, of whom 8 died (67%), whereas for babies in whom only a short segment was involved the mortality was 24%. In five patients (Cases 11–15) a long segment of bowel was involved, the full extent of which was not recognized at the first operation. Repeated operations were needed for the relief of intestinal obstruction and were associated with infective complications; in four of these there were also obstructions due to adhesions. It may be very difficult to recognize exactly, by eye alone, the extent of the aganglionic segment at a primary laparotomy for relief of a neonatal intestinal obstruction. Whenever possible the diagnosis and the extent of the aganglionosis should be confirmed by the immediate

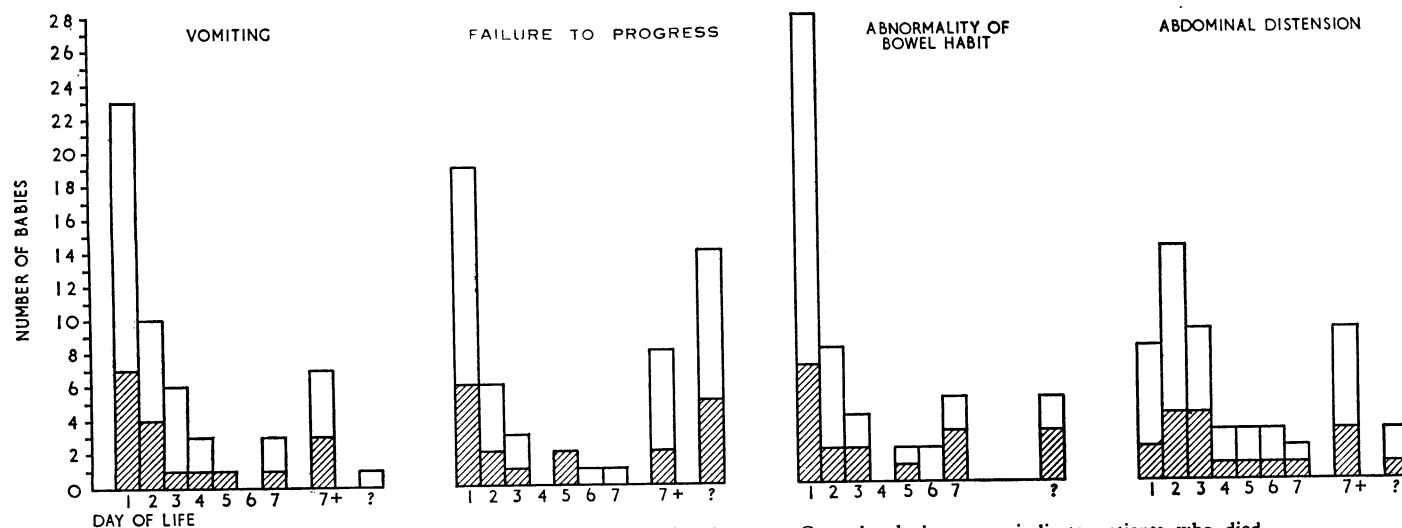


FIG. 2.—Day of onset of the important clinical disturbances. Cross-hatched squares indicate patients who died.

histological examination of a frozen section of a specimen from the bowel wall.

There were three mongols, of whom two died without any surgical treatment—one of bronchopneumonia due to aspiration of vomitus, and the other of cardiac failure. The third patient was treated conservatively for 30 days and then was subjected to a primary pull-through operation of the Soave type; after operation abdominal distension persisted except when relieved by bowel washouts per anum. This child died of cardiac failure at the age of 10 weeks, and necropsy showed a pelvic abscess and congenital defects.

Discussion

It is of the nature of Hirschsprung's disease that there is a high degree of intestinal obstruction from the time the bowel first develops in utero long before the baby is born. This is because the obstruction is due to the defective development of

the nerve supply to the muscle coats of a varying length of the rectum and colon and very rarely of the small intestine (Swenson and Bill, 1948). Though in a few patients only a centimetre or two of the lowest part of the rectum may be aganglionic, and in such patients a satisfactory response may sometimes follow conservative treatment by repeated digital dilatation, the passage of rectal tubes, and rectal washouts, this response may be transient and the risks of perforation and water intoxication are well known. In those babies in whom the aganglionic segment extends above the lower two-thirds of the rectum it is unlikely that dilatation of the upper anal canal and lower rectum will be effective in relieving the obstruction. When the pelvic or more proximal parts of the colon are involved the narrow segment cannot be completely dilated, and bowel washouts are clearly useless and dangerous. A colostomy or ileostomy is essential for complete relief of the obstruction.

In general the babies in this series were of normal size at birth. This is in contrast with the situation in atresia of the oesophagus or duodenum, in which about a quarter of the babies weigh less than 2.5 kg. (5½ lb.) (Waterston *et al.*, 1963; Young and Wilkinson, 1966), compared with only 3 (5.5%) in this series. It is of interest that only 10 out of 106 patients with meconium obstruction treated in this and another hospital weighed less than 2.5 kg. (5½ lb.) (Holsclaw *et al.*, 1965), a proportion not much different from that in the normal population. However, in meconium obstruction the mortality was higher (46%) in babies weighing 6 to 8 lb. (2.7 to 3.6 kg.). In this series of babies with Hirschsprung's disease there was not much variation in mortality rate with different birth weights. In an earlier report from this hospital Wyllie (1957) found the preoperative weights were below average for age, but this was because his patients were older and had failed to thrive. Only 33 of Wyllie's 157 patients were operated on in the first year of life.

Like Forshall (1964), we found few other congenital anomalies associated with Hirschsprung's disease, which in this way resembled meconium obstruction and was unlike oesophageal and duodenal atresia. Hofmann and Rehbein (1966), however, found other serious malformations in 17 (32%) of the 53 neonates in their series.

When persistent and detailed inquiry had been made clinical evidence of the disease during the first week of life was established in almost every child in this series. Vomiting (98%), abdominal distension (94%), and abnormal stools, constipation, or diarrhoea or both (98%) were the most important features and were usually present together. Though such disturbances might appear within a day or two of birth they were not invariable or progressive. Especially when only a very short segment of the rectum was involved, remission of the obstruction might follow digital rectal examination and the subsequent expulsion of gas and liquid faeces. In a few cases such a remission lasted several weeks or even months, but more often recurrent disturbances led to relief by operation. Hofmann and Rehbein (1966) found abdominal distension in all 53 of their neonates with Hirschsprung's disease and bilious vomiting in all but one, and that in 70% meconium had not been passed or had appeared in only small quantities. In the neonate episodes of vomiting of bile-stained fluid, especially if accompanied by abdominal distension, always justify the taking of a radiograph of the abdomen in the upright position to see if there is evidence of intestinal obstruction.

The best and safest way of confirming the clinical diagnosis is by radiological examination after a barium enema, provided that the bowel has not been washed out. Only in those babies whose general condition is too poor for radiological examination and who urgently require the decompression of their obstructed bowel should a colostomy be made without establishing the diagnosis; in these the barium-enema examination can be done a few days later. Rectal biopsy is difficult and dangerous in the neonate and may provide too little tissue for a satis-

Details of Fatal Cases

Case No.	Sex	Age on Admission (Days)	Age at Death (Days)	Length of Segment	Cause of Death at Necropsy	Comments
1	M	3	15	Short	Peritonitis	Perforation during wash-out. Laparotomy; died 3 hours later
2	F	2	4	"	"	Perforation during wash-out. Colostomy; died 10 hours later
3	M	23	62	Long	Obliterative peritonitis	Perforation after rectal biopsy. Laparotomy, colostomy, ileostomy. 1 week later, small intestinal fistula
4	M	8	21	"	Peritonitis, bronchopneumonia	Ileostomy, perforation of rectal biopsy, peritonitis, laparotomy
5	M	5	5	Short	Enterocolitis, perforation of ascending colon, peritonitis	Dead on arrival
6	M	19	19	"	Enterocolitis	Very ill on admission. Colostomy; died 5½ hours later
7	M	25	26	"	Enterocolitis, necrosis of ileum	Very ill on admission. Peritonitis. Laparotomy, colostomy; died 8 hours later
8	M	8	17	"	Peritonitis, enterocolitis	Gangrene of left iliac and transverse colostomies and colon
9	M	10	17	"	Purulent colitis beyond colostomy, ? early enterocolitis above colostomy	Ill on admission. Colostomy sclerema 3rd to 5th postoperative days —subsided; sudden death on 7th day
10	M	2	4	Long	Gangrene of jejunum and ileum. ? Cause	Malrotation of midgut and Hirschsprung's disease to distal ileum; died 30 hours after ileostomy
11	M	14	20	"	Septicaemia, multiple abscesses in lungs and heart	Admitted very ill after several operations elsewhere for "meconium obstruction." Ileostomy; died 8 hours later
12	M	1	50	"	Multiple infections and abscesses	Colostomy on 12th day. Laparotomy 44th day for intestinal obstruction due to adhesions at biopsy site
13	M	27	76	"	Multiple infections, dehydration	Ileostomy, rectal biopsy, laparotomy for obstruction due to adhesions. Repeated bouts of diarrhoea with parenteral therapy
14	M	3	67	"	Septicaemia, lung abscesses, subacute intestinal obstruction	Original colostomy wrongly sited because of erroneous report on frozen section; repeated operations to resite colostomy and relieve adhesion obstructions
15	M	28	38	"	Chronic peritonitis, perforated anterior duodenal ulcer	Colostomy 24 hours after admission, adhesion obstruction 4 days later. Laparotomy
16	M	12	37	Short	Cardiac failure, multiple anomalies	No surgical treatment. Mongol
17	M	24	48	"	Bronchopneumonia, cardiac failure	No surgical treatment. Mongol
18	M	3	70	"	Cardiac failure, pelvic abscess	Primary Soave rectosigmoidectomy; needed postoperative washouts. Mongol

factory histological examination; it should be done only when the result of radiological examination is equivocal.

A third of the patients in this series died, a clear indication of the serious potentialities of Hirschsprung's disease. That such a high mortality should be found in a series of patients in whom the disease had been recognized within the first month of life adds weight to the former estimates (Bodian *et al.*, 1949; Eek and Knutrud, 1962) that 50% died in the first year of life.

The higher mortality in neonates has also been emphasized by Hofmann and Rehbein (1966): 15 of their 53 neonates died. They prefer to treat the condition by washouts and hot packs rather than by colostomy, to which they resorted only when conservative treatment failed. Only two of their patients died during conservative treatment and the remaining 22 survived subsequent resection of the aganglionic bowel. However, of the 31 in whom a colostomy had to be made, 8 died and 19 had a complicated course, and five more died subsequently after resection of the affected bowel.

It seems to us that when Hirschsprung's disease is diagnosed soon after birth the safest form of treatment is decompression of the obstructed bowel by a colostomy or ileostomy with as little delay as possible. Resection of the abnormally innervated segment of bowel should be delayed until the child is 1 year old or weighs 20 lb. (9.1 kg.).

It is not surprising that the mortality rate should be higher in the babies with the "long segment" type of disease, especially when the full extent of the lesion is not recognized at the first or subsequent operations to relieve the obstruction, and the colostomy or ileostomy is first made in aganglionic bowel.

In Hirschsprung's disease the term "abnormality of bowel habit" may imply either constipation or bouts of diarrhoea owing to the passage of faecal stained mucus round an impacted mass of faeces. In its most extreme form diarrhoea may be due to a sort of enterocolitis with mucosal ulceration and toxæmia that is often fatal. In another series of 47 patients with Hirschsprung's disease (Bill and Chapman, 1962) there were 24 with enterocolitis, of whom 21 were neonates and 8 died; though in this series enterocolitis did not occur after colostomy, it did in two of our patients (Cases 8 and 9). Bill and Chapman also found that patients who had once had enterocolitis were liable to its recurrence, especially after rectosigmoidectomy. Swenson and Davidson (1960) have

reported a mortality rate of 33% in patients who were treated medically, but in those for whom a colostomy was made as soon as the disease was diagnosed the mortality rate was only 4%. It seems that the best way to prevent enterocolitis may be to make a colostomy as soon as the diagnosis of Hirschsprung's disease is made, but it must be recognized that this does not always provide complete protection from enterocolitis or prevent death from it.

Summary

Of 54 babies suffering from Hirschsprung's disease who were admitted within a month of birth, 18 (33%) died—5 of enterocolitis and 11 of other complications of the treatment; 2 mongols were not treated surgically.

The clinical disturbance associated with this form of congenital intestinal obstruction usually begins within the first two or three days after birth and is characterized by vomiting, abdominal distension, and abnormality of the bowel action. The clinical diagnosis was confirmed by x-ray examination after a barium enema in 24 out of 27 patients in this series; in one patient the appearances were equivocal and in two others the bowel had been washed out before the examination.

Neonatal intestinal obstruction due to Hirschsprung's disease should be relieved by a colostomy or ileostomy as soon as the diagnosis is established.

We are indebted to the late Mr. G. H. Macnab, Mr. D. J. Waterston, and Mr. H. H. Nixon for allowing us to include patients under their care in this survey.

REFERENCES

- Bill, A. H., jun., and Chapman, N. D. (1962). *Amer. J. Surg.*, **103**, 70.
 Bodian, M., and Carter, C. O. (1963). *Ann. hum. Genet.*, **26**, 261.
 — Stephens, F. D., and Ward, B. C. H. (1949). *Lancet*, **1**, 6.
 Eek, S., and Knutrud, O. (1962). *J. Oslo Cy Hosp.*, **12**, 245.
 Forshall, I. (1964). *J. roy. Coll. Surg. Edinb.*, **10**, 31.
 Hofmann, S., and Rehbein, F. (1966). *Zbl. Kinderchir.*, **3**, 182.
 Holsclaw, D. S., Eckstein, H. B., and Nixon, H. H. (1965). *Amer. J. Dis. Child.*, **109**, 101.
 Swenson, O., and Bill, A. H., jun. (1948). *Surgery*, **24**, 212.
 — and Davidson, F. Z. (1960). *New Engl. J. Med.*, **262**, 64.
 Waterston, D. J., Bonham-Carter, R. E., and Aberdeen, E. (1963). *Lancet*, **2**, 55.
 Wyllie, G. G. (1957). *Ibid.*, **1**, 850.
 Young, D. G., and Wilkinson, A. W. (1966). *Ibid.*, **2**, 18.

Overinflation of the Lungs in Coal Miners

COLIN OGILVIE,* M.D., M.R.C.P.; KEITH BROWN,† M.D., M.R.C.P.; W. E. KEARNS,‡ M.B., CH.B.

Brit. med. J., 1967, **3**, 10-14

Coal miners whose chest radiographs are normal tend to be more breathless than non-miners of the same age group, but a pattern of dysfunction distinct from chronic non-industrial lung disease has not been observed.

The purpose of this report is to compare the results of lung-function tests in coal miners referred to a physiological laboratory because of unexplained dyspnoea with those obtained in a group of men suffering from chronic non-specific lung disease.

Patients

The first group consists of 17 miners (two from Yorkshire and 15 from West Lancashire coal fields) who were referred during 1963-6 to a lung-function laboratory providing a routine service for the region. In each case the miner had been referred by a consultant physician because physical and radiological

examination had failed to reveal an adequate cause for his disability. These 17 cases represent the total number of miners referred to the laboratory in this way. Apart from clinical or radiological signs compatible with either chronic non-specific lung disease or pneumoconiosis, no cardiac or pulmonary cause for dyspnoea could be found in any of these patients. The only miners attending the laboratory during 1963-6 and excluded from this report were those referred for routine preoperative assessment or for the investigation of a disease not directly related to their occupation (mitral stenosis, bronchiectasis, bronchial carcinoma, or tuberculosis).

* Consultant Physician.

† Senior Medical Registrar.

‡ Medical Registrar.

Regional Cardiothoracic Centre, Broadgreen Hospital, Liverpool 14.