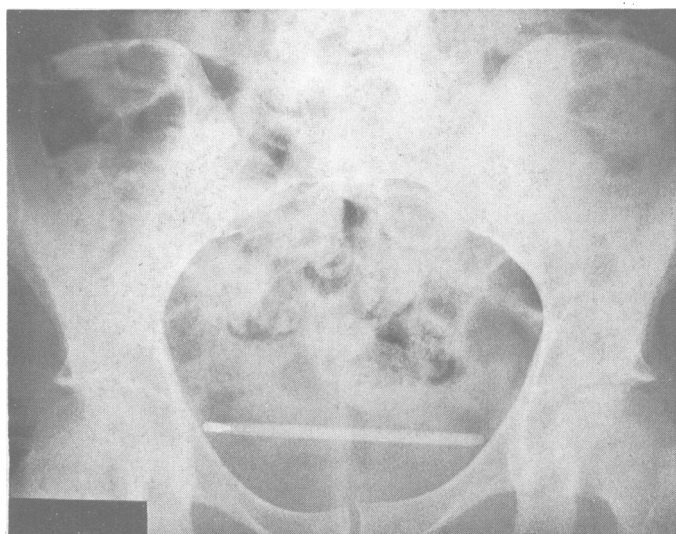


## Hazard of recording vaginal temperature

A 37 year old woman with secondary infertility had been advised by her general practitioner to record her basal body temperature vaginally. One morning she presented to a casualty department complaining that she could not remove the thermometer. Vaginal examination and a radiograph of the pelvis (figure) suggested that the thermometer was in the bladder. This was confirmed at cytoscopy, when the thermometer was removed under general anaesthesia with stone crushing forceps whose jaws were shod with rubber cylinders cut from a latex catheter. The patient made a full recovery and was discharged the next day.

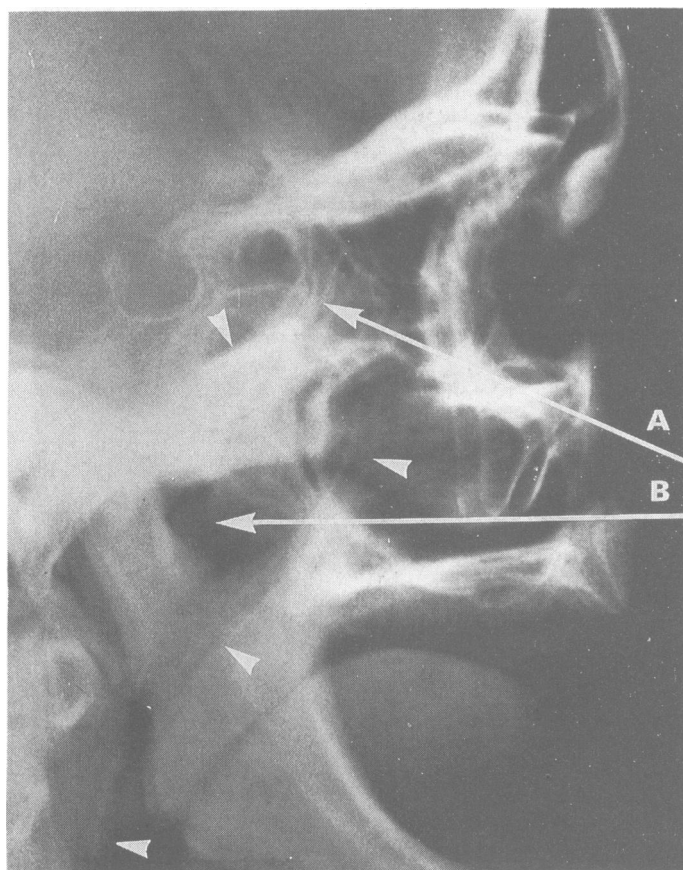
Inadvertent insertion of a thermometer into the bladder during recording of vaginal temperature has been reported many times before, and we think it time that doctors stopped advising women to record their basal temperatures vaginally: oral recording is safe and adequate.—E EYONG, D J BURCH, Department of Obstetrics and Gynaecology, University Hospital of South Manchester, Manchester M20 8LR.



## A nasogastric tube in the sphenoid sinus

A 75 year old woman was admitted with suspected subacute intestinal obstruction. A nurse passed a Ryles large bore nasogastric tube through the nose by pointing it backwards and upwards (arrow A). After she had passed 10 cm of the tube the tip would advance no further and could not be retracted. A lateral skull radiograph showed the tube's tip within the sphenoidal sinus. The tube was removed with the patient under general anaesthesia.

A nasogastric tube should be passed directly backwards close to the horizontal nasal floor (arrow B) and through the least obstructed side of the nose. Failure to do this may result in the tube's tip entering the sphenoid sinus ostium.—N S VIOLARIS, Ear, Nose, and Throat Department, Greenbank Hospital, Plymouth PL4 7JH.



## A case of organ pipe dermatitis

For the past ten years I have been consumed with a passion for pipe organs. I woke one morning with my lower lip slightly paralysed. Red patches appeared on my nose and chin, my face was flushed and itchy, and I had lumpy ridges on my cheeks. One eye became swollen half shut, and my chest and arms were red. The day before I had been asked to look at a pipe from a burnt out organ. The pipe was covered with something chemically toxic or a fungus and was unlike any pipe I had ever seen. After cleaning off about 0.1 mm of combined metal, grime, burnt varnish, smoke, and general dirt I had put the pipe to my mouth about 10 times. That was the culprit. Is this the only case of organ pipe dermatitis reported?

In the photograph (taken by Father Lawrence of Westminster Abbey, Mission, British Columbia) I am blowing an oboe pipe in the abbey—RALPH SPITZER, 1191 Knox Road, Vancouver, British Columbia V6T 1S5.

