

SHORT REPORTS

Sarcoidosis and multiple myeloma: an association

An association between sarcoidosis and neoplasia has been suggested.¹ The development of malignant lymphoma has been reported in several patients with sarcoidosis,² but there have been few reports of patients with sarcoidosis and multiple myeloma.^{2,4} We describe five patients with sarcoidosis who developed multiple myeloma.

Case histories

The table shows details of five patients with sarcoidosis seen by us during 1969-86. In each case the diagnosis of sarcoidosis was based on both the clinical findings and histological evidence of non-caseating epithelioid cell granulomas. The mean age of the patients at the time of diagnosis was 55 (range 42-65). In four patients myeloma developed several years after the diagnosis of sarcoidosis; in one both diagnoses were made at the same time. The duration of sarcoidosis was more than two years in three patients (cases 1, 2, and 4), and sarcoidosis was considered to be active at the time of diagnosis of myeloma in two (cases 2 and 5). Two patients (cases 1 and 2) had been treated with steroids.

All patients met the diagnostic criteria for multiple myeloma. Four patients (cases 1-4) were treated with cytotoxic drugs and the other (case 5) was followed up without treatment. Four patients survived, but the other (case 3) died in 1985, four years after the diagnosis of myeloma.

Comment

All our patients showed features consistent with sarcoidosis and were not thought to have had a sarcoidosis like reaction, such as has been described in association with malignant tumours, among them lymphoma and myeloma. In four of the cases the long time interval between the diagnoses (three to 12 years) increases the chance that these patients had two separate disease processes. In the one patient who presented with sarcoidosis and myeloma at the same time it is of course conceivable that both disorders were due to the same disease process.

The mean age of our patients at the time of diagnosis of sarcoidosis was appreciably higher than the average age at which sarcoidosis is diagnosed. We thus agree with Brincker that it is the chronic active type of sarcoidosis that develops in middle aged patients that is associated with the subsequent development of neoplastic disease.²

Proof of a causal rather than a merely coincidental association between sarcoidosis and myeloma may be obtained only by prospective epidemiological studies. Both diseases, however, are comparatively rare, the incidence of sarcoidosis in Finland varying from 5 to 21/100 000 and that of myeloma being about 3/100 000. On the basis of these figures, the expected number of cases of both sarcoidosis and myeloma in the Finnish population (somewhat below five million) during a 10 year follow up is less than 0.3, which suggests a very low chance of the two disorders occurring by coincidence.

Although the aetiology of multiple myeloma is unknown, evidence suggests that chronic stimulation of the immune system may be a predisposing factor, presumably in combination with genetic or viral factors.⁵ Sarcoidosis is a chronic granulomatous disease, also of unknown aetiology, that has pathogenetic features that may predispose to the development of lymphoproliferative diseases, such as myeloma. In sarcoidosis activated T helper/inducer lymphocytes in the sites of inflammation cause a polyclonal stimulation of B lymphocytes, which may result in hyper-

gammaglobulinaemia. Prolonged stimulation of B lymphocytes together with a disturbance in the regulation of the immune system might result in the development of an autonomous plasma cell clone producing a monoclonal immunoglobulin. Alternatively, a common primary immunological derangement or a common aetiological factor might underlie the development of both sarcoidosis and myeloma in certain people.

- 1 James DG, Sharma OP. Overlap syndromes with sarcoidosis. *Postgrad Med J* 1985;61:769-71.
- 2 Brincker H. The sarcoidosis-lymphoma syndrome. *Br J Cancer* 1986;54:467-73.
- 3 Selroos O, Brander L, Virolainen M. Sarcoidosis and myeloma of lambda-type IgG. *Acta Med Scand* 1974;195:59-63.
- 4 Schafer AI, Miller JB. Association of IgA multiple myeloma and pre-existing disease. *Br J Haematol* 1979;41:19-24.
- 5 Isobe T, Osserman EF. Pathologic conditions associated with plasma cell dyscrasias: a study of 806 cases. *Ann NY Acad Sci* 1971;90:507-18.

(Accepted 6 August 1987)

Fourth Department of Medicine, Helsinki University Central Hospital, 00170 Helsinki, Finland

TOM PETTERSSON, MD, senior physician

Department of Medicine, Tampere University Central Hospital, Finland

ELLI KOIVUNEN, MD, senior physician

Lapland Central Hospital, Rovaniemi, Finland

MIRJA ILVONEN, MD, internist

Seinäjäki Central Hospital, Seinäjäki, Finland

JUSSI JOUPPILA, MD, internist

Härmä Hospital, Alahärmä, Finland

ERKKI AALTO, MD, chest physician

Finnish Leukaemia Group, Vasa

CURT WASASTJERNA, MD, professor

Correspondence to: Dr Pettersson.

Acute mesenteric ischaemia: a presenting feature of coeliac disease?

We describe two patients with acute mesenteric ischaemia requiring extensive small bowel resection. Both had a prolonged and difficult convalescence that was presumed to be due to the short bowel syndrome. Underlying coeliac disease was later diagnosed in both cases and presumably contributed towards their management problem.

Case reports

CASE 1

A 37 year old woman presented with a two week history of abdominal pain and vomiting. Clinical examination showed features of peritonitis. At laparotomy there was small bowel infarction thought to be due to mesenteric venous thrombosis. The infarcted bowel was resected and primary anastomosis per-

Clinical data on five patients with sarcoidosis and multiple myeloma

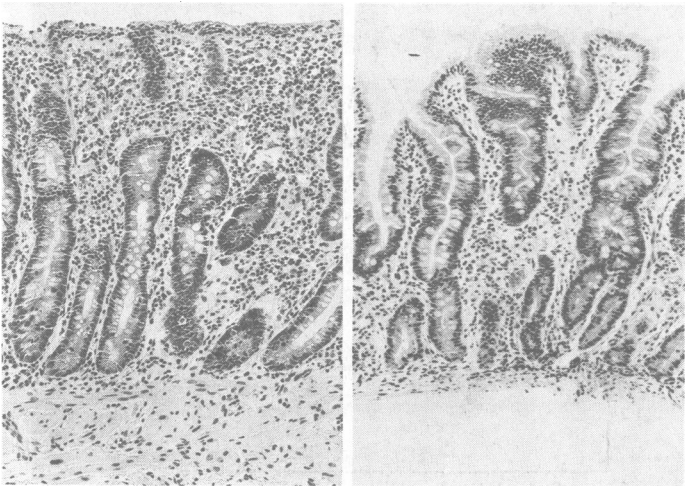
Case No	Age* (years) and sex	Time between diagnoses (years)	Type of myeloma	Features consistent with sarcoidosis	Evidence for myeloma
1	42 M	6	IgG λ	Fever, hilar adenopathy, positive result on Kveim testing	Bone marrow plasmacytosis >90%; monoclonal IgG 69.8 g/l; λ chain excretion 1.8 g/day; lytic bone lesions; reduction in IgA and IgM
2	58 M	6	IgA κ	Hilar adenopathy, uveitis, parotid enlargement and biopsy findings	Bone marrow plasmacytosis 70%; monoclonal IgG 51.7 g/l
3	56 M	3	IgG κ	Breathlessness, arthralgia, hilar adenopathy, lung parenchymal infiltration, scalene node biopsy findings	Monoclonal IgG 65.5 g/l; κ chain excretion 1.5 g/day; bone marrow plasmacytosis 10%; lytic bone lesions; reduction in IgA and IgM
4	65 F	12	IgG λ	Mediastinal node enlargement and biopsy findings	Bone marrow plasmacytosis 30%; monoclonal IgG 42.6 g/l; λ chain excretion 3.0 g/day; lytic bone lesions; reduction in IgA and IgM
5	60 F	None	IgG λ	Erythema nodosum, hilar adenopathy, bronchial mucosa biopsy findings	Bone marrow plasmacytosis 50%; monoclonal IgG 17.5 g/l; reduction in IgA and IgM

*Age at onset of sarcoidosis.

formed. Postoperatively she had recurrent symptoms necessitating a further laparotomy. There was infarction around the anastomotic site and further resection was performed. Altogether 300 cm of small bowel was resected. The postoperative course was complicated by pulmonary embolism requiring anticoagulation. She had prolonged diarrhoea, weight loss, and nutritional deficiencies despite enteral nutritional support.

Five months later she was referred to our unit, where investigations showed thrombocytosis (platelets $654 \times 10^9/l$) and features of hyposplenism in a blood film. A histological review of the resected specimen showed features of coeliac disease with crypt hyperplastic villous atrophy at the proximal resection margin. This was confirmed at jejunal biopsy (figure, left). She also had selective IgA deficiency and was positive for rheumatoid factor. Extensive investigations showed no thrombotic disorder.

She improved dramatically on a gluten free diet, a repeat jejunal biopsy showed histological improvement (figure, right), and her platelet count reverted to normal. She later developed rheumatoid arthritis but otherwise remained well at follow up.



Left: Jejunal biopsy showing subtotal villous atrophy, crypt hyperplasia, and increase in intraepithelial lymphocytes. Right: Jejunal biopsy showing reversion towards normal villous pattern.

CASE 2

A 58 year old man was admitted at another hospital with abdominal pain, distension, and vomiting. Because of the features of peritonitis a laparotomy was done, at which a large segment of gangrenous small bowel associated with pulseless superior mesenteric artery was noted. About 330 cm of small bowel was resected. Postoperatively he had persistent diarrhoea and weight loss. Later he was transferred to our care, where he developed acute abdominal symptoms. At laparotomy there was a perforation in the proximal small bowel and a strictured area just distal to this. A 7 cm segment of bowel, including the stricture and perforation, was resected. Histological examination of the resected specimen showed features of coeliac disease, and there was also some fibrotic change suggesting chronic ischaemia. A retrospective review of the original resected specimen showed features of coeliac disease—distinctly different from ischaemic change, in which there is crypt hypoplasia.

He had a complicated postoperative course and died. At necropsy there was infarction of the entire large and small bowel with gangrenous greater curve of stomach. The superior mesenteric artery was occluded at the aortic origin. There was no evidence of generalised atherosclerosis, and the cardiac chambers were free from clot.

Comment

To our knowledge, these are the first reports of acute mesenteric ischaemia associated with coeliac disease. Although coeliac disease in case 2 could not be confirmed, the histological appearances of both the resected specimens of this patient's bowel were typical.

Investigations in case 1 failed to show any evidence of a thrombotic disorder, and no other predisposing factors (such as oral contraceptive use) could be incriminated. This patient had thrombocytosis, although unfortunately the platelet count at the time of presentation was not available. Might the thrombocytosis be relevant to the aetiology of mesenteric venous thrombosis in this patient?

Thrombocytosis has been noted before in coeliac disease.¹ In one study 57% of patients with untreated coeliac disease had peripheral blood thrombocytosis, which fell significantly after treatment.² This feature was present in our first patient as well, thus suggesting its association with coeliac disease. Although usually asymptomatic, thrombocytosis causes thrombosis in a few cases.³ There are reports of mesenteric venous thrombosis occurring

late after splenectomy in association with thrombocytosis.⁴ Thus, the acute mesenteric ischaemia in case 1 might be a presenting feature of coeliac disease.

These cases also illustrate the importance of excluding intrinsic small bowel disease in patients with prolonged symptoms after small bowel resection.

- 1 Brooks FP, Powell KC, Cirda JJ. Variable clinical course of adult coeliac disease. *Arch Intern Med* 1966;117:789-94.
- 2 Nelson EW, Ertan A, Brooks FP, Cerda JJ. Thrombocytosis in patients with coeliac sprue. *Gastroenterology* 1976;70:1042-4.
- 3 Hirst J, Davie JV. Persistent post-splenectomy thrombocytosis and thromboembolism: a consequence of continuing anaemia. *Br J Haematol* 1966;12:44.
- 4 Nagsue N, Inokuchi K, Kobayashi M, Saku M. Mesenteric venous thrombosis occurring late after splenectomy. *Br J Surg* 1977;64:781-3.

(Accepted 21 July 1987)

Gastroenterology Unit and Department of Pathology, Royal Infirmary, Glasgow G31 2ER

R UPADHYAY, MRCP, research registrar in gastroenterology
R H R PARK, MRCP, registrar in gastroenterology
R I RUSSELL, MD, PHD, consultant gastroenterologist
B J Z DANESH, MRCP, senior registrar in gastroenterology
F D LEE, MD, FRCPATH, consultant pathologist

Correspondence and requests for reprints to: Dr Russell.

Bacterial keratitis in contact lens users

Microbial keratitis occurs in eyes with existing diseases of the ocular surface because these predispose to infection by disrupting ocular defence mechanisms.¹ Recently bacterial keratitis has been reported in people wearing soft contact lenses, most of whom had normal eyes; Gram negative organisms were often responsible.² This study documented current predisposing factors and organisms in microbial keratitis at a major centre in the United Kingdom and investigated epidemiological factors in people wearing contact lenses.

Patients, methods, and results

During one year from 25 February 1985, 53 consecutive admissions for microbial keratitis were examined. Cases in which a bacterial or fungal cause was treated presumptively were included as failure to isolate an organism does not exclude a microbial cause. Patients with herpes simplex virus keratitis were included only if bacterial superinfection was suspected. The χ^2 test and Fisher's exact test (two tailed) were used to analyse data.

Contact lenses were worn at the onset of keratitis by 22 patients. In 13 cases they were used as an alternative to spectacles: in 10 for cosmetic reasons (low hypermetropia and myopia) and in three for aphakia. Three of these patients lost vision with postresolution acuities of 6/12, 6/18, and perception of light; only one patient was wearing a hard contact lens. Most of the patients who did not wear contact lenses had pre-existing ocular surface disorders or trauma. Thus all patients had predisposing factors; only those using cosmetic lenses and the patient with a myeloblastic disorder had previously normal eyes. Corneal isolates are shown in the table. Patients who did not wear contact lenses or who wore them for therapeutic reasons were predominantly infected by Gram positive cocci. Other lens users were principally infected with Gram negative bacteria ($p=0.0006$), of which pseudomonas were most strongly associated with soft contact lenses ($p=0.001$); three of these patients had not handled their lenses for from four to 42 days before the onset of symptoms and had sterile lens care solutions.

Comment

Microbial keratitis is probably a rare complication of cosmetic contact lens wear,³ but lenses are now a major predisposing factor in microbial keratitis at this centre and in some centres in the United States.² Altogether 13 of the patients were wearing contact lenses when spectacles would have been appropriate. The increased frequency of Gram negative keratitis in all patients wearing lenses and of pseudomonas keratitis in those wearing soft contact lenses, except therapeutic ones, suggests that use of contact lenses may have modified the range of bacteria causing microbial keratitis and that soft lens users may be predisposed to infection by pseudomonas. Contamination of lens solutions is an important factor in the aetiology of keratitis associated with lens wear.⁴ Failure to show a relation between lens care solutions and keratitis in three patients, however, suggests that another factor may be the susceptibility of the eyes of some soft lens wearers to