

tion is believed to be the presence of a short intramural tunnel and the absence of adequate detrusor support for the intravesical ureter. In the normal urinary tract as the ureter approaches the bladder it loses its circular fibres and within the bladder wall it is surrounded solely by longitudinal muscle fibres. These latter continue downwards beyond the ureteric orifice into the trigone, fanning out and mingling with similar fibres from the opposite side and being firmly attached to the mucosa of the trigone. Thus the ureter has only one firm attachment to the bladder—that is, at its orifice by its longitudinal muscle fibres running into the trigone. Congenital deficiency or absence of the longitudinal muscle of the submucosal ureter, as seen in primary reflux, results in upward or lateral displacement of the ureteric orifice, thereby reducing the length and obliquity of the intramural ureter. In addition to producing a solid support behind the intravesical ureter, the Teflon implant also provides a firm anchorage to the intravesical ureter, thereby preventing it from sliding upwards during micturition and thus preventing reflux. From these data we believe that it may be possible to treat vesicoureteric reflux in man by endoscopic injection of Teflon paste.

We thank Professor Niall O'Higgins for providing facilities at the Woodview Research Laboratories. We are particularly indebted to Mr Nicholas O'Connor and Ms Josephine Mulligan for their help.

References

- Stephens FD, Lenaghan D. The anatomical basis and dynamics of vesicoureteric reflux. *J Urol* 1962;**87**:669-80.
- King LR, Kazmi SO, Belman AB. Natural history of vesicoureteric reflux: outcome of a trial of nonoperative therapy. *Urol Clin North Am* 1974;**1**:441-5.
- Lyon RP, Marshall S, Tanago EA. The ureteral orifice: its configuration and competency. *J Urol* 1969;**102**:504-9.
- Hodson CJ, Cotran RS. Reflux nephropathy. *Hosp Pract* 1982;**17**:133-56.
- Jerkens GR, Noe HN. Familial vesicoureteral reflux: a prospective study. *J Urol* 1982;**128**:774-8.
- Smellie JM, Gruneberg RN, Leakey A, et al. Long-term low-dose co-trimoxazole in prophylaxis of childhood urinary tract infection: clinical aspects. *Br Med J* 1976;**iii**:203-6.
- Politano VA, Leadbetter WF. An operative technique for the correction of vesicoureteric reflux. *J Urol* 1958;**79**:932-41.
- Paquin AJ Jr. Ureterovesical anastomosis: description and evaluation of a technique. *J Urol* 1959;**82**:573-83.
- Cohen SJ. Ureterozystoneostomie: eine neue antireflux Technik. *Aktuel Urol* 1975;**6**:1-9.
- Arnold GE. Alleviation of aphonia or dysphonia through intrachordal injection of teflon paste. *Ann Otol Rhinol Laryngol* 1963;**72**:384-95.
- Goff WF. Teflon injection for vocal cord paralysis. *Arch Otolaryngol* 1969;**90**:98-102.
- Politano VA, Small MP, Harper JM, Lynn CM. Periurethral Teflon injection for urinary incontinence. *J Urol* 1974;**111**:180-3.
- Politano VA. Periurethral polytetrafluorethylene injection for urinary incontinence. *J Urol* 1982;**127**:439-42.
- Schulman CC, Simon J, Wespes E, Germeau F. Endoscopic injection of Teflon to treat urinary incontinence in women. *Br Med J* 1984;**288**:192.
- Stone JW, Arnold GE. Human larynx injected with Teflon paste. Histologic study of innervation and tissue reaction. *Arch Otolaryngol* 1967;**86**:550-61.
- Hodson CJ, Maling TMJ, McManamon LM. The pathogenesis of reflux nephropathy. *Br J Radiol* 1975;suppl 13:1-26.
- Ransley PG, Risdon A. Renal papillary morphology and intrarenal reflux in young pigs. *Urol Res* 1975;**3**:105-9.

(Accepted 29 May 1984)

Treatment of vesicoureteric reflux by endoscopic injection of Teflon

BARRY O'DONNELL, P PURI

Abstract

Thirteen girls with grade III-V vesicoureteric reflux were treated by endoscopic injection of Teflon paste behind the intravesical ureter. Fourteen of the 18 treated ureters showed complete absence of reflux after one injection of Teflon. Three ureters required a second injection of Teflon for successful treatment of the reflux. One ureter with grade IV reflux was converted to grade II reflux.

Properly carried out, this procedure corrects reflux. It takes less than 15 minutes, may be done as a day procedure, and avoids open surgery. There have been no complications.

Introduction

Vesicoureteric reflux has been a controversial subject since 1952, when Hutch highlighted its association with renal damage.¹ Its role in the development and progression of chronic pyelonephritis is now widely recognised. The indications for antireflux surgery have been widely debated. There is general

agreement that patients with the more severe grades of reflux (grades IV and V of the international classification²) and those who develop "breakthrough" bacteriuria while having antimicrobial chemotherapy should have antireflux surgery.

Several antireflux operations have been described. All entail opening the bladder and performing a wide variety of procedures on the ureter. The two most popular operations are the Politano-Leadbetter technique³ of transvesical reimplantation of the ureters and Cohen's transtrigonal advancement.⁴ The principle behind antireflux operations is to lengthen the intravesical ureter against a solid detrusor support to allow its compression against the detrusor. Most patients who have these procedures spend a week or more in hospital. The antireflux operations are effective but not free from complications even in the best hands. Surgery in children with high grade reflux with dilated ureters carries a higher rate of failure and morbidity than in children with low grade reflux and non-dilated ureters.⁵

We have shown in the preceding paper that it is technically feasible to correct successfully experimentally produced vesicoureteric reflux in the piglet by intravesical injection of Teflon paste—a relatively inert material.⁶ This paper describes our experience of treating vesicoureteric reflux in 13 children by endoscopic injection of Teflon.

Patients and methods

Thirteen girls, 12 with primary vesicoureteric reflux and one with secondary reflux due to neuropathic bladder, were included in the study. Their ages ranged from 6 months to 12 years (mean 6.8 years). Five patients had bilateral and eight unilateral reflux; of these, nine

Children's Research Centre, Our Lady's Hospital for Sick Children, Dublin 12, Ireland

BARRY O'DONNELL, MCH, FRCS, consultant paediatric surgeon
P PURI, MS, associate paediatric surgeon

Correspondence to: Mr O'Donnell.

ureters had grade III reflux, seven had grade IV reflux, and two had grade V reflux.

A specially designed 5F polyethylene catheter ending in an 18 gauge needle was guided through a 14 cystoscope. The bladder was filled with irrigating saline through the cystoscope. The needle was inserted 2-3 mm below the ureteric orifice. The needle was advanced 0.5 cm into the space behind the intravesical ureter and 0.2 to 0.5 ml polytef paste (Ethicon) injected with 1 ml syringe with a Storz metallic sheet and piston.

Postoperatively a micturating cystogram was obtained on the same day. Patients were discharged from the hospital after 24 hours, a

course of co-trimoxazole being given for one week. An intravenous pyelogram was obtained in each patient one week after discharge from the hospital to determine whether there was any evidence of obstruction at the vesicoureteric junction.

Results

Cystography after the endoscopic injection of Teflon paste showed complete absence of reflux in 14 out of 18 ureters (figs 1 and 2). Reflux in one ureter was converted from grade IV to grade II.

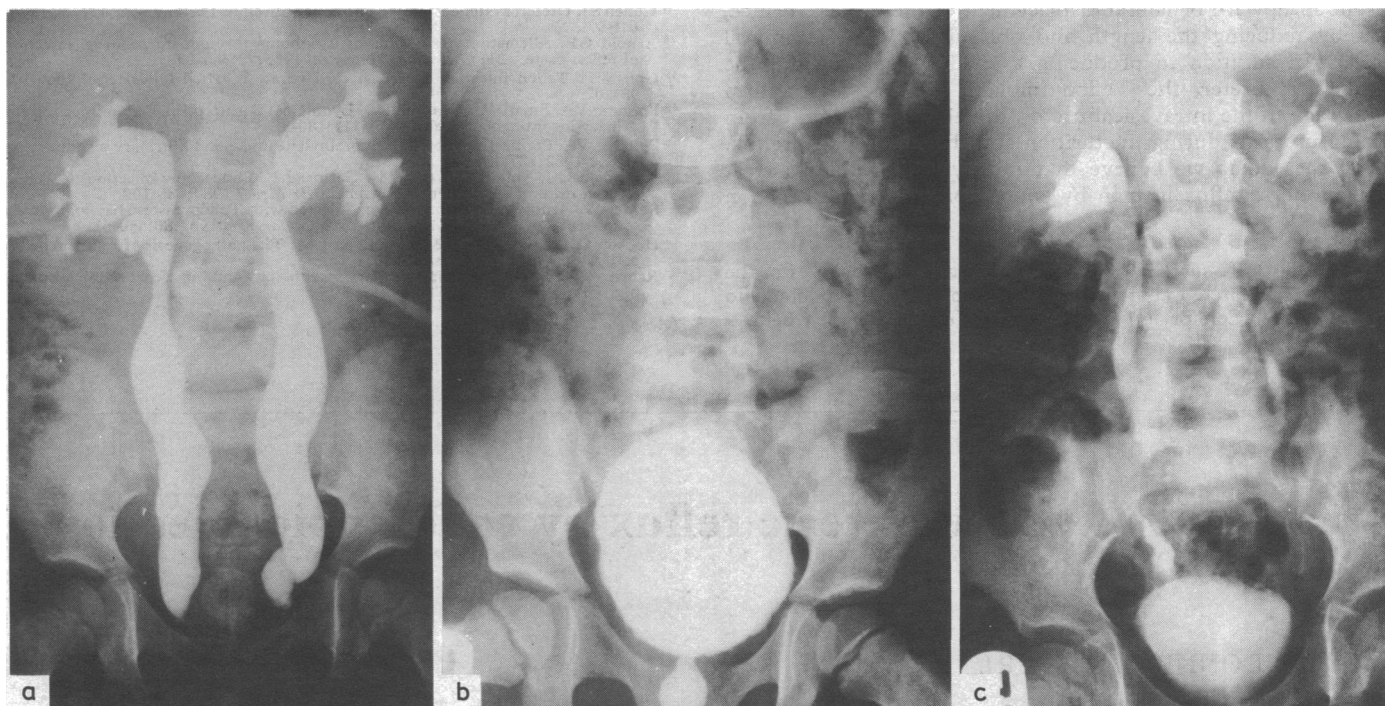


FIG 1—(a) Micturating cystogram in a 5 year old girl showing grade IV bilateral vesicoureteric reflux. (b) Micturating cystogram in the same patient after endoscopic injection of Teflon showing no evidence of reflux. (c) Intravenous pyelogram in the same patient showing no evidence of ureteric obstruction.

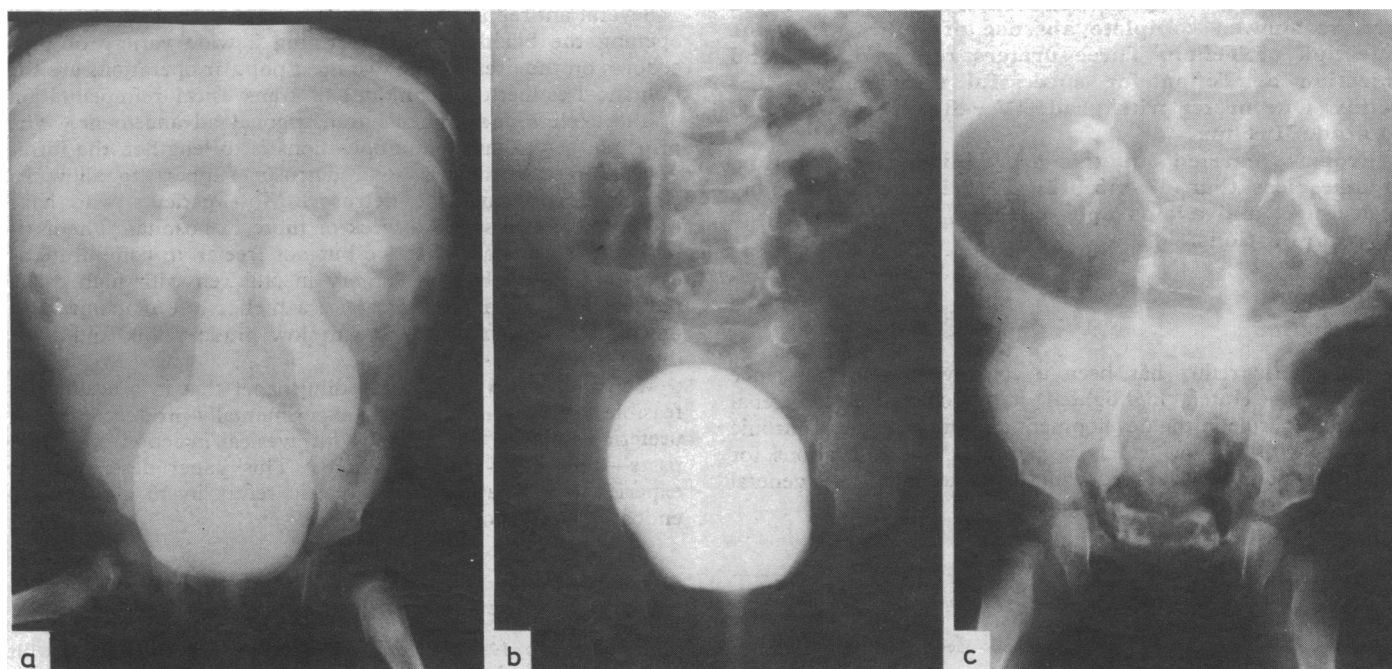


FIG 2—(a) Micturating cystogram in a 6 month old child showing grade V bilateral reflux. (b) Micturating cystogram in the same child after endoscopic subureteric injection of Teflon showing no evidence of reflux. (c) Intravenous pyelogram in the same child showing no evidence of ureteric obstruction.

Failure to correct reflux was seen in three ureters, but in all of these reflux was successfully corrected after a second injection of Teflon. Postoperative intravenous pyelography showed no evidence of ureteral obstruction in 18 treated ureters.

Discussion

This study confirms in man our previous experimental findings in the pig that subureteric injection of Teflon eliminates vesicoureteric reflux. Our patients achieved an excellent cure rate after simple endoscopic injection of Teflon paste behind the intravesical ureter. There was no ureteral obstruction in 18 treated ureters.

Polytef paste for injection is a sterile, injectable paste, containing polytef, glycerine, and polysorbate. Polytef is polytetrafluorethylene or Teflon that has been pyrolysed; it is not absorbed but the particles are encapsulated by fibrous tissue with a minimal lymphocytic reaction.^{6 7} The implant achieves a firm consistency and retains its shape and position at the injection site.⁶

This procedure is well tolerated, avoids open operation, and shortens hospital stay. It might be of particular value in small infants with gross reflux, in whom antireflux surgery has been considered to be too hazardous. Similarly, the results of re-

implantation of the ureters into the neuropathic bladder have been unrewarding. The ureters in our one patient with reflux secondary to a neuropathic bladder were cured of reflux after a single injection of Teflon.

Properly carried out, the procedure corrects vesicoureteric reflux. It takes about 15 minutes, may be done as a day procedure, and avoids open surgery. We call the procedure "The Sting"—that is, subureteric Teflon *injection*.

References

- ¹ Hutch JA. Vesico-ureteral reflux in the paraplegic; cause and correction. *J Urol* 1952;68:457-67.
- ² International Reflux Study Committee. Medical versus surgical treatment of primary vesico-ureteral reflux. *Pediatrics* 1981;67:392-400.
- ³ Politano VA, Leadbetter WF. An operative technique for the correction of vesico-ureteral reflux. *J Urol* 1958;79:932-41.
- ⁴ Cohen SJ. Ureterozystoneostomie: eine neue antireflux Technik. *Aktuel Urol* 1975;6:1-9.
- ⁵ Coleman JW, McGovern JH. A 20 year experience with pediatric ureteral re-implantation: surgical results in 701 children. In: Hodson J, Kincaid-Smith P, eds. *Reflux nephropathy*. New York: Mason Publishing, 1979:299-305.
- ⁶ Puri P, O'Donnell B. Correction of experimentally produced vesicoureteric reflux in the piglet by intravesical injection of Teflon. *Br Med J* 1984;289:5-7.
- ⁷ Stone JW, Arnold GE. Human larynx injected with Teflon paste. Histologic study of innervation and tissue reaction. *Arch Otolaryngol* 1967;86:550-61.

(Accepted 29 May 1984)

Violence and psychosis

II—Effect of psychiatric diagnosis on conviction and sentencing of offenders

PAMELA J TAYLOR, JOHN GUNN

Abstract

An examination of the records of all sick and violent men remanded to a large English prison suggested a tendency among police to consider men to be exceptionally dangerous simply because of their mental illness. On further study, however, there was no evidence that the mentally ill were more vulnerable to detention without subsequent conviction than their normal peers. Remand was rarely followed by help for the mentally abnormal men studied; this is disturbing as requests for psychiatric help constitute an important reason for custodial remand. Less than a third of the men with active symptoms went to hospital, although some of the less disturbed received supervision (including probation) orders, occasionally with treatment.

As there is evidence that most of the few mentally abnormal offenders who subsequently receive treatment benefit from it, psychiatrists should do more for offender patients.

Introduction

Many men held on custodial remand have committed relatively trivial offences, and a substantial minority are never convicted of the offence with which they have been charged. Some, furthermore, are remanded in custody for alleged offences that, if established, cannot lead to a sentence of imprisonment (for example, minor thefts). The high prevalence of psychiatric disorder in a large male remand prison was described in last week's issue (30 June, p 1945-9).¹ How does this arise? Are mentally ill people particularly vulnerable to being detained for offences that are subsequently not proven? Is there something about their behaviour that leads them to be seen as potentially threatening and results in their imprisonment, even though they may not have behaved dangerously? There appear to be some substantial differences in the prevalence of psychiatric disorder between remanded and convicted prisoners; the prevalence of psychosis, in particular, among convicted prisoners is relatively low.^{2 3} Are the mentally ill subsequently excused for their behaviour or are they placed in settings more appropriate to their need for treatment?

Method

A sample of 1241 men who were sick or charged with a violent offence, or both, and entering Brixton prison for the first time were studied by means of a review of case notes, as described in last week's issue (30 June, p 1945-9).¹ They constituted 45% of the total new intake of 2743 men for the four months studied. Information was recorded on a specially developed check list that covered such information as age, current charges, convictions, and sentences, criminal history, psychia-

Institute of Psychiatry, London SE5

PAMELA J TAYLOR, MRCP, MRCPsych, senior lecturer
JOHN GUNN, MD, FRCPsych, professor

Correspondence to: Dr Pamela J Taylor.