

- ² Gunn A. Intestinal perforation due to swallowed fish or meat bone. *Lancet* 1966;i:125-8.
- ³ Ward-McQuaid JN. Perforation of the intestine by swallowed foreign bodies. *Br J Surg* 1952;39:349-51.
- ⁴ McManus JE. Perforations of the intestine by ingested foreign bodies. *Am J Surg* 1941;53:393-402.
- ⁵ Snodgrass TJ. Foreign bodies in the intestinal tract. *Arch Surg* 1947;55:441-56.

(Accepted 11 November 1982)

Stepping Hill Hospital, Stockport, Cheshire

E S KIFF, FRCS, senior surgical registrar
N HULTON, FRCS, surgical registrar

Correspondence to: Mr E S Kiff, St Mark's Hospital, City Road, London EC1V 2PS.

Mercurialis perennis (dog's mercury) poisoning: a case of mistaken identity

The increasing popularity of natural foods and herbal remedies and their associations with the "alternative society" suggest that the incidence of accidental plant poisoning may increase. We report two cases of poisoning with *Mercurialis perennis* (dog's mercury), a common woodland plant found throughout Britain.

Case report

A 40 year old schoolmaster and his 39 year old wife ate a large quantity of a herb which they had mistakenly identified as the edible plant brooklime (*Veronica beccabunga*). Several bunches of the plant had been gathered from the banks of a stream in a north Wales forest. Before eating the plant they had washed and boiled it. Identification of the species had been made by comparison with a small illustration in a popular publication.¹

Four hours later they both presented to hospital seriously ill and complaining of nausea, vomiting, and severe bilateral colicky loin pains. Both patients were flushed and sweating and had a curious malar erythema. There was no abnormality of the cardiovascular or respiratory system. In both patients abdominal palpation elicited pronounced bilateral tenderness in the renal angles. Initial urine testing with Ames Multistix yielded a haemolysed trace of blood in the husband. Full blood count on admission showed haemoglobin concentrations of 15.2 g/dl (husband) and 12.8 g/dl (wife) with normal platelet and white cell counts in both patients.

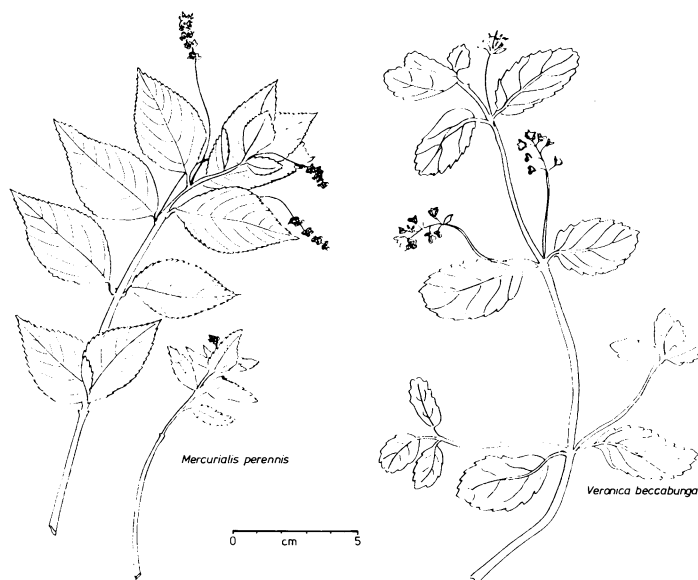
In view of the severity of vomiting supportive treatment was instituted with intravenous 5% dextrose and 0.9% saline, 1 litre over eight hours. Since the general appearance of the patients suggested a possible allergic reaction they were treated empirically with intravenous hydrocortisone sodium succinate 200 mg eight hourly and intramuscular chlorpheniramine maleate 20 mg.

Two leaves only of the original specimen were available, and these were identified by a botanical taxonomist. From the stomatal pattern and microscopic leaf characteristics the species was *M perennis* (figure).

The recommended empirical treatment² of high dosage oral sodium bicarbonate 25 g four times daily was begun in an attempt to neutralise organic acids and induce alkaline diuresis. Twelve hours after admission both blood films showed pronounced anisocytosis but there was no measurable fall in haemoglobin concentration. Repeated urine testing showed immediate resolution of haemoglobinuria in the man. Serial liver function values, including serum bilirubin concentration, alanine aminotransferase activity, and prothrombin times, remained within normal limits. There was no abnormality in serum urea or electrolyte concentrations. Faecal occult blood testing remained negative and urine microscopy clear. Forty eight hours later both blood films were normal; the patients made a complete recovery.

Comment

Dog's mercury is a common woodland plant, a member of the spurge family Euphorbiaceae, and is known to be very poisonous. The ground may be covered with extensive patches in spring, and it is generally found throughout Britain, especially on clay, basic, or neutral soils. The volatile basic oil mercurialine is thought to be one of the active principles partly responsible for the toxicity of the herb and induces haemorrhagic inflammation of the gastrointestinal tract and kidneys. There is apparently some narcotic action, which may induce drowsiness and mild muscular spasm. Symptoms are gastroenteritis, constipation followed by bloody diarrhoea, haematuria or



Illustrations of *M perennis* (dog's mercury) and *V beccabunga* (brooklime) derived from shadowgraphs of actual specimens.

haemoglobinuria, fever, and coma leading to death.² This toxicity was recognised by Nicholas Culpeper in the seventeenth century, when he wrote: "There is not a more fatal plant, native of our country than this species of mercury" (Nicholas Culpeper (1616-54), *Culpeper's complete herbal and English physician*; 1826 edition).

The poisoning of ruminant animals is not uncommon.³ A well documented outbreak of fatal mercurialis poisoning in Welsh mountain ewes⁴ included haemolytic anaemia without marrow suppression and acute oedematous gastroenteritis with hepatic centrilobular necrosis. Experimentally induced toxicity with dog's mercury, frozen at different stages of growth and fed to sheep, indicated that these effects may be due to different toxic principles developing at varying stages of plant growth. Another possibility is that one toxin is the culprit and, provided the victim survives the enteric upset, prolonged ingestion produces haemolytic anaemia.

Cases in man have been reported⁵ but the clinical signs not fully recorded. In particular, there appears to be no report of the malar erythema noted in both of our patients, but the abdominal symptoms, haemoglobinuria, and anisocytosis are consistent with the clinical signs and haemolysis observed in poisoned animals. Fortunately, our patients had boiled the plant before ingestion. This presumably removed some of the thermolabile and toxic oils, thus reducing the severity of poisoning. Hence there was evidence of only very mild haemolysis in one patient.

Publications which fail to give accurate and detailed colour illustrations of plants should be treated with caution. Moreover, the appearance of a species varies with habitat, and this remains a trap for the unwary.

We are grateful for the help of Miss Denise Lamb, poisons unit, Guy's Hospital, London, and Mrs Elizabeth Rugman for the illustrations.

¹ Mabey R. *Food for free—a guide to the edible wild plants of Britain*. London: Fontana Paperback, 1975.

² Ministry of Agriculture. *British poisonous plants*. London: HMSO, 1982:68-9.

³ Jordan M. *A guide to the wild plants; the edible and poisonous species of the northern hemisphere*. London: Millington Press, 1976:194-5.

⁴ Baker JR, Faull WB. Dog's mercury poisoning in sheep. *Vet Rec* 1968; April 27:485-9.

⁵ Forsyth AA. *British poisonous plants*. London, HMSO, 1954.

(Accepted 1 February 1983)

Arrowe Park Hospital, Wirral, Merseyside L49 5BE

F RUGMAN, MB, MRCP, registrar
J MEECHAM, MD, FRCP, consultant

Merseyside County Museums, Liverpool L3 8EN

J EDMONDSON, PHD, keeper of botany

Correspondence to: Dr F Rugman, Royal Liverpool Hospital, Liverpool L7 8XP.