

SHORT REPORTS

The dangers of plastic "champagne" corks

With the rising cost of cork there are now many types of sparkling wines, such as hock and Moselle, which have a ribbed plastic cork which is securely fastened by a metal band and twisted wire in the conventional way. When these corks are released, however, they are often projected with an extremely high velocity in spite of caution and care on the part of the person opening the bottle.

Problems at parties

On New Year's Eve last year I had the unfortunate experience of one of these corks shooting from the bottle at high speed and hitting a glass lamp bowl, which completely shattered. The falling glass caused a laceration on my left lower lid. Fortunately no one else in the room was injured by this shower of glass.

A similar sparkling Moselle was the favoured drink at our Christmas Eve practice party, and although I insisted on opening all the bottles myself in view of my previous experience, two of the corks shot out of the bottle with the same high speed. Fortunately the bottles were pointing to a part of the ceiling where they could do no damage.

Comment

I am sure that many people buying these wines are not fully aware of the potential danger of these new plastic corks, and I hope that organisations like the Royal Society for the Prevention of Accidents and the appropriate association of wine and spirit merchants may be induced to produce a warning notice about the dangers of such plastic corks.

Bromsgrove, Worcestershire B60 2PG

H M WHITE, MB, MRCP, general practitioner

Breast disease associated with tassel dancing

Striptease dancing is an art form that has been practised for hundreds of years. A refinement of it, tassel dancing, in which various tassel adornments are suspended from the breasts, has been popular in the Middle East also for a considerable time. Recently, in order to keep the tassel in place some dancers have had their nipples pierced, much in the same way that ears are pierced, to accommodate a ring from which can be suspended appropriate adornments. This practice, however, may result in pathological changes in the breast, such as described here.

Case report

A 33-year-old professional striptease dancer presented with a lump in the right breast. She had had one baby when aged 14, whom she had not breast-fed, and had recently been taking norethisterone to improve her libido. Nine months before she had had her nipples pierced transversely by a professional tattooist, who had used a technique closely similar to that for piercing ears. An ethyl chloride spray is used as local anaesthetic, and after the nipple has been pierced a rod is left in place (a sleeper) to allow the tract to epithelialise.

Two months before she attended a lump had appeared in the right breast; there was no discharge from the nipple, and the lump was not tender. On examination the left breast was found to be normal apart from a transverse tract across the nipple where it had been pierced. A similar tract was seen in the right breast; in addition a lump consistent with a distended and engorged major duct and extending 0.5 cm beyond the boundary of the areola radiated from the nipple. Surgical exploration was performed.

Through a circumareola incision the major ducts were inspected, and one was found to be grossly dilated with some periductal fibrosis. The affected duct system was excised and the skin repaired with polyglycolic acid sutures. An O'Donaghue bodkin was placed through the previously created tract to maintain a pierced nipple during healing. The patient was discharged the

next day. A nipple transfer (which may be obtained commercially) was applied to the breast to give a more natural appearance, and she returned to striptease dancing within three days. She subsequently made a full recovery. Histologically the lump comprised fibrous breast tissue with a dilated duct containing eosinophilic and amorphous material and some mononuclear cells. The appearances were consistent with duct ectasia; there was no evidence of malignancy.

Comment

As yet piercing the nipples is not widespread in Western cultures, and even in professional striptease dancers it is apparently rare. The only other report so far is a description of the associated radiological artefacts.¹

Any form of piercing that crosses the nipple theoretically may occlude the opening of one or more of the major duct systems of the breast, so that the duct will be distended behind and a prominent lump will form. Though on this occasion there was no evidence of active inflammation, such an eventuality seems probable.

Thanks are due to Dr Malcolm Farley for the histological report.

¹ Healey T. Nipple-piercings—unusual artefacts. *Radiography* 1979;536:164-5.

(Accepted 8 September 1981)

Kent and Canterbury Hospital, Canterbury CT1 3NG

R E C COLLINS, FRCS, FACS, consultant surgeon

Factitious pheochromocytoma: a case for Sherlock Holmes

We report a singular case of pheochromocytoma in which the diagnosis was made by the patient himself.

Case report

A 37-year-old man who sold mineral water and other drinks and had previously been in excellent health presented with severe systolic hypertensive attacks, bradycardia, and headache followed by hypotension and sweating; the attacks lasted for one to two hours and occurred once or twice daily. Mild hyperglycaemia (7.8-8.9 mmol/l (140-160 mg/100 ml)) was present during the attacks. Treatment with phentolamine 5 mg intravenously reduced arterial blood pressure from 240/140 to 120/70 mm Hg.

Clinical features strongly suggested the presence of a noradrenaline-secreting pheochromocytoma. Urinary concentrations of vanillylmandelic acid, metadrenalines, and catecholamines were, however, normal; concentrations of noradrenaline and adrenaline in blood drawn from suprarenal veins were low; and renal and suprarenal angiography showed no abnormality. A search for other possible diseases (intermittent hydrocephalus, acute intermittent porphyria, multiple endocrine adenomatosis) and further tests (cerebral scinti scanning, computed tomography, pneumoencephalography, carotidography, cisternography) and hormonal studies were performed but were unhelpful. Meanwhile he continued to have many severe hypertensive attacks and episodes of acute pulmonary oedema, which usually subsided with phentolamine treatment.

Five months later the patient (still alive in spite of all this) realised that the hypertensive attacks always occurred after ingestion of mineral water. Chemical tests disclosed large quantities (400 mg/l) of metaraminol in water in the bottles from which he had drunk; these bottles had been taken to him regularly from his own store by his wife, a nurse. When he stopped drinking the water all his symptoms disappeared.

Comment

This pheochromocytoma-like syndrome was caused by massive ingestion of metaraminol, a drug with well-known noradrenaline-like effects. The patient is now in perfect health. His wife, however, was found guilty of attempted murder.

We conclude that surreptitious ingestion of sympathetically acting drugs should be considered in the differential diagnosis of hypertensive attacks.

2nd Department of Internal Medicine, Endocrine Metabolic Unit,
S Maria Nuova Hospital, 42100 Reggio Emilia, Italy

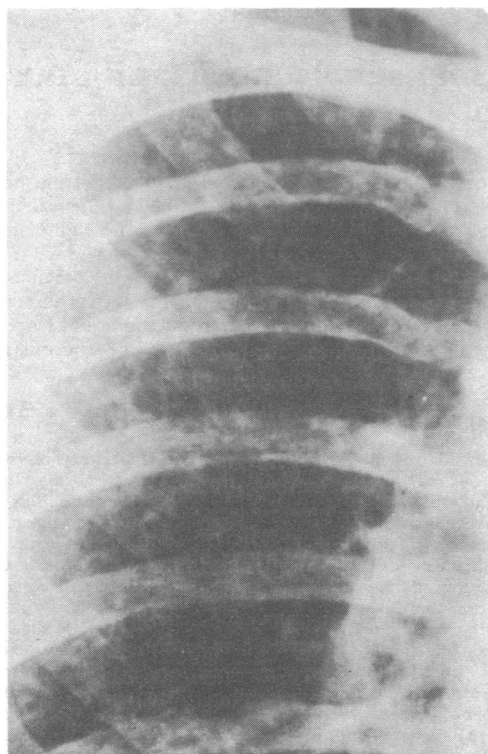
ITALO PORTIOLI, MD, professor
ROBERTO VALCAVI, MD, assistant

Punk rocker's lung: pulmonary fibrosis in a drug snorting fire-eater

While pulmonary damage secondary to intravenous self-administration of drugs is well recognised, disease due to deliberate inhalation of drugs other than for therapeutic purposes is not. We report on a patient who developed pulmonary fibrosis secondary to "snorting" of drugs and inhalation of turpentine or paraffin.

Case report

A 21-year-old builder's labourer with a two-week history of diffuse chest pain, cough, and purulent sputum was referred for chest radiography. Until three months earlier he had been a full-time drummer in a punk-rock band and had led an irregular existence which ended when he ignited his flat with a cigarette; since then he had been living with his parents. He smoked



Detail of chest radiograph showing small nodular and irregular infiltrates through the lung.

about 60 cigarettes daily and had regular morning cough and sputum. As part of his act he used to fill his mouth with turpentine or paraffin which he would blow out and ignite. He had taken drugs since he was 16-years-old, often swallowing them with beer. He recalled taking, among others, Mandrax, Tuinal, Dexedrine, DF118, diazepam, and cannabis. He occasionally inhaled powdered drugs—particularly Tuinal, nitrazepam, and cocaine—through a rolled-up pound note (snorting). He had never injected himself. He denied dyspnoea and when seen in the clinic was symptom free.

His chest was wheezy but there were no marks on his arms. Chest radiography showed bilateral small nodular and irregular infiltrates throughout

both lungs with no hilar node enlargement (figure). Lung function was completely normal (forced expiratory volume, 4.5 litre, forced vital capacity 5.0 litre, and transfer factor 100% predicted). Haemoglobin concentration, erythrocyte sedimentation rate, and blood film gave normal results, as did all blood tests, including for rheumatoid factor, avian precipitins, and viral titres. Tubercle bacilli were not cultured from sputum. Mantoux 1:100 and Kveim tests were negative. Electrocardiography showed no abnormality. Arterial blood showed mild hypoxia with an arterial oxygen pressure of 9.6 kPa.

A drill biopsy of the lung was performed to make a diagnosis. The specimen showed foci of fibrosis containing clumps of macrophages and clefts lined by bronchiolar epithelium. Some macrophages contained large intracytoplasmic vacuoles compatible with exogenous lipid. There were no granulomas. Several small spicules of material that transmitted polarised light were seen both in alveolar macrophages and in scarred areas but not in vessels.

Two months later he was well with no treatment and chest radiograph and lung function were unchanged. He defaulted from further follow-up.

Comment

The needle biopsy specimen showed florid pulmonary scarring and intra-alveolar fibrosis with acicular refractile material, probably talc, though the specimen was too small for further analyses. Within the fibrous tissue were macrophages containing empty coalescent vacuoles representing oils removed by organic solvents during the processing, and presumed to be either paraffin or turpentine. There was no intravascular foreign material and it was clear that in our patient inhalation was the only means of administration.

The fibrosis was probably due to the combination of inhalation of paraffin or turpentine in "fire-eating," and of talc, a lubricant and filler in tablets. Although talc is known to cause a pulmonary reaction when inhaled in an occupational setting¹ and cosmetically,² we have been unable to find any report of diffuse pulmonary fibrosis in a drug-snorter or solely due to the inhalation of the lighter hydrocarbons such as turpentine. Severe lung scarring has, however, been reported in association with the accidental inhalation of liquid paraffin and with the smoking of tobacco containing mineral oils in Guyana.³⁻⁵

As the habit of snorting drugs appears to be prevalent in the lunatic fringe of our society, more cases of this syndrome will probably be recognised, and physicians should be aware of it as a radiological mimic of sarcoidosis in young people.

¹ Morgan WKC, Seaton A. *Occupational lung diseases*. Philadelphia: W B Saunders, 1979:112.

² Wells IP, Dubbins PA, Whimster WF. Pulmonary disease caused by inhalation of cosmetic talcum powder. *Br J Radiol* 1979;52:586-8.

³ Pinkerton H. The reaction to oils and fats in the lung. *Archives of Pathology* 1928;5:380-401.

⁴ Salm R, Hughes EW. A case of chronic paraffin pneumonitis. *Thorax* 1970;25:762-8.

⁵ Miller GJ, Ashcroft MT, Beadnell HMSG, Wagner JC, Pepys J. The lipoid pneumonia of blackfat tobacco smokers in Guyana. *Q J Med* 1971;40:457-70.

(Accepted 27 May 1981)

City Hospital, Edinburgh EH10 5SB

D R BUCHANAN, MB, MRCP, medical registrar

Department of Pathology, Edinburgh University

D LAMB, MB, MRCPATH, senior lecturer

Institute of Occupational Medicine, Edinburgh EH8 9SU

A SEATON, MD, FRCP, director

Britain's biggest ovarian cyst?

Removal of a giant ovarian cyst may be followed by life-threatening complications. We report the largest ovarian cyst removed in Great Britain with survival of the patient.

Case report

A 44-year-old nulliparous housewife presented with abdominal swelling that had gradually increased over five years and recently been associated with breathlessness and pain in the legs. She had been housebound for one year and could not get into bed, but she and her husband had concealed her