

- ⁷ Barchha, R, Stewart, M A, and Guze, S B, *American Journal of Psychiatry*, 1968, **125**, 681.
- ⁸ Moore, R A, *American Journal of Psychiatry*, 1971, **128**, 130.
- ⁹ McCusker, J, Cherubin, C, and Zimberg, S, *New York State Journal of Medicine*, 1971, **71**, 751.
- ¹⁰ Gomberg, E S, *Journal of Studies on Alcohol*, 1975, **36**, 1458.
- ¹¹ Edwards, G, Chandler, J, and Hensman, C, *Quarterly Journal of Studies on Alcohol*, 1972, suppl No 6, pp 94, 120.
- ¹² Hilton, M R, and Lokare, V G, *British Journal of Psychiatry*, 1978, **132**, 42.
- ¹³ Plant, M A, and Miller, T I, *Social Psychiatry*, 1977, **12**, 21.
- ¹⁴ Kearney, T R, *American Journal of Psychiatry*, 1969, **125**, 157.
- ¹⁵ Morgan, A W, *et al*, *Canadian Medical Association Journal*, 1974, **111**, 1067.
- ¹⁶ Morgan, H G, *et al*, *British Journal of Psychiatry*, 1975, **127**, 564.

(Accepted 13 July 1979)

Cimetidine in treatment of reflux oesophagitis with peptic stricture

ROGER FERGUSON, M W DRONFIELD, MICHAEL ATKINSON

British Medical Journal, 1979, **2**, 472-474

Summary and conclusions

Twenty patients with reflux oesophagitis causing a tight peptic oesophageal stricture entered a randomised double-blind crossover trial in which they received cimetidine, 1.6 g daily, and matching placebo each for six months. The gross endoscopic appearances of oesophagitis, though not the grades of histopathological changes, showed significant improvement during treatment with cimetidine. The need for dilatation of the strictures, however, was not reduced.

Introduction

Peptic oesophageal stricture is caused by reflux oesophagitis, whose severity is related to the acidity of the oesophageal contents.¹ Cimetidine, a potent inhibitor of the secretion of gastric acid and pepsin, reduces oesophageal acidity,² relieves symptoms,^{3, 4} and promotes healing of oesophagitis^{5, 6} in patients with gastro-oesophageal reflux. To determine whether cimetidine is of benefit in the treatment of peptic oesophageal stricture we have studied its effect on symptoms, oesophagitis, and the need for dilatation in 20 patients with peptic oesophageal stricture resistant to conventional medical management of gastro-oesophageal reflux.

Patients and methods

Twenty patients, 10 men and 10 women aged 52-82 years (mean 70 years), entered the study. All had tight oesophageal strictures that, despite conventional medical measures to control reflux, had required at least two dilatations in the preceding six months or three in the preceding year. One patient suffered from systemic sclerosis, three had previously undergone vagotomy and pyloroplasty or a gastric resection for peptic ulcer, and one had undergone a Nissen fundoplication.

University Hospital, Nottingham NG7 2UH

ROGER FERGUSON, MD, MRCP, senior medical registrar
MICHAEL ATKINSON, MD, FRCP, consultant physician
M W DRONFIELD, MB, MRCP, senior medical registrar

Trial design—Cimetidine (400 mg four times daily) was compared with a placebo on a double-blind crossover basis, the preparations being given for six months each in random order. Symptoms, endoscopic and histopathological appearances, and the need for dilatation were recorded.

Symptoms—The occurrence of pain and the severity of dysphagia were recorded daily by the patients on a diary card, which they brought to the clinic on each monthly visit. Dysphagia was graded as the ability to swallow a normal diet (grade 0), a diet avoiding only certain solids such as steak or raw fruit (grade 1), a soft diet (grade 2), and a liquid diet (grade 3); those with grade 4 dysphagia had difficulty in taking even liquids in adequate amounts. All patients were weighed monthly in the clinic and throughout the trial took an antacid (Asilone Gel) as required for pain and were asked to sleep with the bed-head raised.

Endoscopy—The upper alimentary tract was examined using the Olympus GIFK fiberoptic endoscope at the beginning, after two months, and at the end of each six-month treatment period and whenever dysphagia became severe. The diameter of the stricture was measured and the degree of oesophagitis in the stricture assessed using a grading scale of 0 for normal mucosa, 1 for reddening, 2 for reddening and friability to touch, and 3 for ulceration.

Histopathology—Biopsy specimens from within the stricture were taken at endoscopy, and the degree of oesophagitis was graded histopathologically as normal (grade 0), mild inflammatory cell infiltration (grade 1), severe inflammatory cell infiltration (grade 2), and ulceration (grade 3).

Dilatation—Dilatation of the stricture using the Eder Puestow metal olive dilators was done only when the stricture failed to admit the Olympus GIFK endoscope (external diameter 12.5 mm).

Results

Fourteen of the 20 patients completed the full trial: five died during the trial (of whom three had completed at least six months) and one was withdrawn after six months. In all, 16 treatments with cimetidine and 16 with placebo were completed.

Symptomatic response—The average number of days and nights per month during which pain occurred was 6.8 for the six months of placebo treatment and 4.1 for the six months of cimetidine treatment. This difference was not significant, but since the maximum score possible was 56 pain was apparently not a troublesome symptom. The grade of dysphagia at the end of each month averaged 0.45 for placebo and 0.76 for cimetidine. This difference was not significant.

Endoscopic appearances—On entering the trial all patients had intense oesophagitis with ulceration in the stricture (grade 3). To assess the change in the gross endoscopic appearances the grade of oesophagitis at the beginning was subtracted from that at the end of each treatment period (fig 1). The degree of oesophagitis improved significantly during cimetidine treatment compared with placebo treatment ($P < 0.05$). During cimetidine treatment 10 of the 16 patients improved and one deteriorated, while during placebo treatment five improved and five deteriorated.

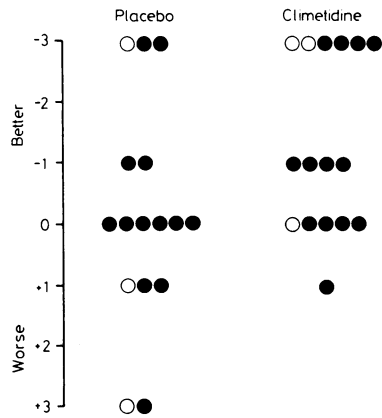


FIG 1—Change in grade of oesophagitis as assessed from gross endoscopic appearances during 16 cimetine and 16 placebo treatment periods. (Open circles represent those patients who had undergone vagotomy and drainage or gastric resection for peptic ulcer.)

Histopathology—Subtracting the histopathological grade of oesophagitis seen in the endoscopic biopsy specimen at the beginning from that at the end of each treatment period showed no significant improvement in oesophagitis during treatment with cimetine compared with placebo treatment (fig 2). Some difficulty was encountered in this procedure, however, since at times gastric-type epithelium was obtained on biopsy within the stricture and it was difficult to compare this with previous biopsy specimens in which squamous epithelium had been present.

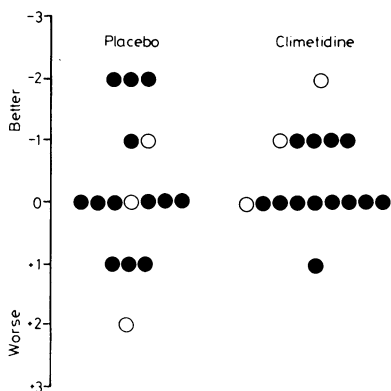


FIG 2—Change in grade of oesophagitis as assessed from histological appearances of oesophageal biopsy specimens taken during 16 cimetine and 16 placebo treatment periods. (Open circles represent those patients who had undergone vagotomy and drainage or gastric resection for peptic ulcer.)

Dilatation—During the six months before entry into the trial the average number of dilatations required in each patient was 2.0. This fell during the trial to an average of 1.25 with placebo treatment and 1.12 with cimetine treatment. Dilatation was not necessary during nine of the 16 cimetine and five of the 16 placebo treatment periods. When the number of dilatations in each period in individual patients are compared (fig 3) five required fewer and two required more dilatations during cimetine treatment. The three patients who had undergone a vagotomy and drainage procedure or gastric resection all required frequent dilatations during both treatment periods, even though the oesophagitis improved in two. Thus we were unable to show any significant reduction in the need for dilatation of peptic stricture during the trial in spite of the improvement in oesophagitis.

Side effects and deaths—No patient reported any side effects from cimetine, and routine blood samples taken at monthly intervals showed a slight rise in serum creatinine concentration during

cimetine treatment but no change in liver function tests nor any haematological abnormality. Of the five deaths during the trial, two resulted from cardiac infarction: one occurred four months after the patient had completed the six-month course of cimetine and one on initial placebo treatment. Both patients had had pre-existent angina. One patient died of a cerebral haemorrhage after completing six months' cimetine treatment, one of bronchopneumonia and inanition during an initial placebo period, and the fifth, a woman with systemic sclerosis affecting most of the gut, died of peritonitis after perforation of a stercoral ulcer of the colon after six months' cimetine treatment. It seemed improbable that any of these deaths were attributable to cimetine.

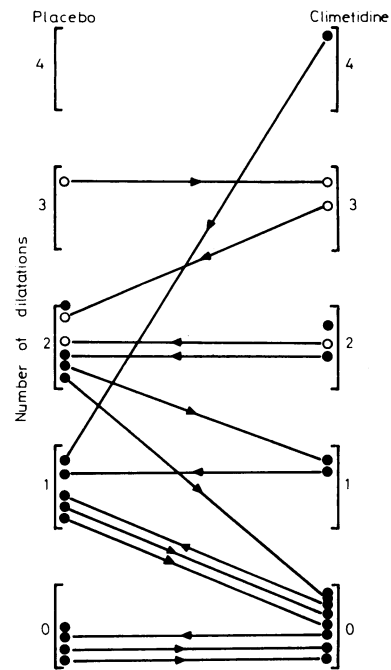


FIG 3—Numbers of dilatations needed during cimetine and placebo treatment periods in individual patients. The arrows indicate the order in which treatment was received. (Open circles represent those patients who had undergone vagotomy and drainage or gastric resection for peptic ulcer.)

Discussion

The value of cimetine in relieving symptoms of gastro-oesophageal reflux is now generally accepted, but whether it promotes healing of oesophagitis is less certain. With treatment periods of six to eight months neither Behar *et al*³ nor Powell-Jackson *et al*⁴ could show any improvement in oesophagitis, although, after giving 1.6 g of cimetine daily for eight-week periods, Wesdorp *et al*⁵ found a significant improvement in the gross endoscopic and histopathological evidence of oesophagitis. We used a much longer period of treatment and found clear evidence of improvement in oesophagitis as judged by gross appearance but not by histopathology. This suggests that, although symptomatic relief is rapid, improvement in oesophagitis takes much longer.

In contrast with the improvement in oesophagitis we found no reduction in the need for dilatation of peptic oesophageal stricture. The explanation for this apparent discrepancy may be that the six-month treatment periods were too short for any reduction in the rate of stricture formation to become apparent, and certainly several of our patients who continued to take cimetine after the trial was over needed fewer dilatations. Alternatively, agents other than gastric acid may be responsible for stricture formation. Reflux of bile and duodenal or small-intestinal contents is a recognised complication of operations

for peptic ulcer, and the three patients in our study who had undergone vagotomy and drainage or gastric resection all needed frequent dilatations during both placebo and cimetidine treatment periods. Since our results show that cimetidine benefits oesophagitis, however, it seems reasonable to hope that a longer period of treatment might lessen the need for dilatation.

We are indebted to Dr P D James for the histopathological reports, and to Smith Kline and French Laboratories Ltd for the placebo and cimetidine tablets.

SHORT REPORTS

Babesiosis in man: a case from Scotland

Babesiosis, a world-wide tick-borne protozoal disease of wild and domestic animals, has occasionally infected man, and cases have been reported from both Europe and America.¹ The Old World cases, often associated with cattle babesiosis, have generally affected patients who have had splenectomy and the outcome has often been fatal; the American cases, in patients with intact spleens, have been centred on the Island of Nantucket and appear to be a less serious form of the disease associated with a rodent babesia. We summarise here the details of the first recorded case of babesiosis in the United Kingdom; the case will be reported fully elsewhere.²

Case report

A 34-year-old accountant who lived near Inverness contracted Hodgkin's disease in December 1974. A splenectomy was performed and treatment with telecobalt radiation undertaken. He remained well until August 1977, when a recurrence of Hodgkin's disease again required treatment by irradiation.

In August 1978 he was admitted to Raigmore Hospital, Inverness, with a three-day history of tiredness, malaise, vomiting, diarrhoea, and a diminishing output of dark red urine. On admission his skin was dusky red, the conjunctivae icteric, the pulse rate 120/minute, and the blood pressure 130/80 mm Hg. There was a normochromic anaemia—Hb 8.9 g/dl, which fell to 7.3 g/dl within the first day. The total white cell count was 19.4×10^9 ($19\,400/\text{mm}^3$) with 80% polymorphs. ESR was unreadable owing to intense haemolysis. Serum concentrations were: bilirubin 95 micromol/l (5.7 mg/100 ml); potassium 4.8 mmol/l (mEq/l); and creatinine 501 $\mu\text{mol/l}$ (5.5 mg/100 ml). Blood film showed heavy infestation of erythrocytes by an intracellular parasite.

The patient was transfused with concentrated red cells and his renal function closely monitored. The possible use of antibabesial drugs available in veterinary medicine was considered and a supply of diminazene (Berenil) arranged. In the interim intensive antimalarial therapy, initially with quinine intravenously followed by chloroquine intravenously and pyrimethamine, 50 mg orally, was started. He appeared to improve and there was an appreciable fall in the degree of parasitaemia. Nevertheless, renal function progressively deteriorated and he was transferred to Aberdeen for haemodialysis. By then his blood urea concentration was 64 mmol/l (384 mg/100 ml). Two haemodialyses were successfully completed but cardiac embarrassment developed owing to a pericardial effusion and, although 500 ml of blood-stained fluid was aspirated, his condition rapidly deteriorated and he died. Death was attributable to cardiac tamponade; at necropsy, the pericardial cavity contained blood clot and serosanguinous fluid. Uraemic pneumonitis and pleurisy were present. There was a para-aortic lymphadenopathy and splenunculus at the tail of the pancreas. Histological examination showed Hodgkin's disease in the lymph nodes and the splenunculus; the kidney presented acute tubular necrosis with extensive haemoglobin cast formation in distal tubular and collecting ducts.

Four ml of heparinised/EDTA blood sent to the Agriculture Research Institute at Compton, Berks, was inoculated, intravenously and subcutaneously, into a splenectomised bovine and produced a *Babesia divergens* parasitaemia at its maximum (9/1000 infected cells) seven days later. The parasite was also successfully isolated in gerbils (*Meriones unguiculatus*). Subsequent serological tests carried out at the Central Veterinary Laboratory at Weybridge, Surrey, confirmed that the parasite was *B. divergens*.²

Comment

The patient who has had a splenectomy appears to have lost his most effective protection against these parasites³ and now that

References

- Atkinson, M, and van Gelder, A, *American Journal of Digestive Diseases*, 1977, **22**, 365.
- Bennett, J R, Martin, H D, and Buckton, G, *Cimetidine*, conference proceedings, Westminster Medical School, p 147. Edinburgh, Churchill Livingstone, 1978.
- Behar, J, et al, *Gastroenterology*, 1978, **74**, 441.
- Powell-Jackson, P, Barkley, H, and Northfield, T C, *Lancet*, 1978, **2**, 1068.
- Wesdorp, E, et al, *Gastroenterology*, 1978, **74**, 821.
- Petrokubi, R J, and Jeffries, G H, *Gastroenterology*, 1978, **74**, 1077.

(Accepted 20 July 1979)

splenectomy is commonly performed a considerable number of people must at times be at risk—for example, on outdoor holidays. In blood films it is easy to confuse babesia with malaria parasites, and antimalarial treatment has been used in several of the cases recorded. A trial of diminazene and pentamidine, which are effective in animals,⁴ would appear to merit consideration in severe cases of human babesiosis. The extent to which *B. divergens* may give rise to subclinical infections is unknown but the possibility may be worth considering in patients with fever where exposure to ticks has, or could have occurred.

- Dammin, G J, *Seminars in Infectious Disease*, 1978, **1**, 169.
- Entrican, J H, et al, *Journal of Infection*, 1979, in press.
- Garnham, P C C and Voller, A, *Acta Protozoologica*, 1965, **3**, 183.
- Miller, L H, et al, *Annals of Internal Medicine*, 1978, **88**, 200.

(Accepted 13 July 1979)

Raigmore Hospital, Inverness IV2 3UJ

J H ENTRICAN, BMEBBIOL, MRCP, senior registrar
H WILLIAMS, MD, consultant microbiologist
I A COOK, MD, FRCPATH, consultant haematologist
W M LANCASTER, MB, FRCP, consultant physician
J C CLARK, MB, CHB, lecturer in pathology

Ministry of Agriculture, Fisheries and Food, Central Veterinary Laboratory, Weybridge, Surrey

L P JOYNER, DSC, FIBIOL, senior research officer

ARC Institute for Research on Animal Diseases, Compton, Near Newbury, Berks

D LEWIS, BSC, senior scientific officer

ONE HUNDRED YEARS AGO An application of a very singular nature came before the Bridgnorth Town Council at a recent meeting. The Medical Officer of Health (Mr Mathias), commenting on the health of the district during the first quarter of this year, said that he had no report to make and no sanitary defects to bring under their notice. The only complaint he had was, that he was receiving too much money for the work he did. He therefore proposed that his salary should be reduced by £10, thus making it £20 instead of £30 per annum. Mr Mathias can, we think, hardly be serious; £30 is by no means an exorbitant salary for looking after the public health of a community of six thousand persons, even if, which is by no means the case at Bridgnorth, the vital statistics of the place showed it to be exceptionally healthy. Mr Mathias has himself said that he does not believe it is right for him to take public money that he does not earn; and we trust that, on reconsideration, he will see that the truest economy to the district would be, not to accept less remuneration, but really to earn, by more vigorous supervision of the district, his present salary. (*British Medical Journal*, 1879.)

Correction

Herpetic proctitis and sacral radiculomyelopathy

We regret that a printer's error occurred in the title of the short report by Mr Samarasinghe and his colleagues (11 August, p 365). "Sacral radiomyelopathy" should have read "sacral radiculomyelopathy."