

that is, high-speed—sawing, drilling, and sandpapering. The hardwoods would provide greater frictional resistance and consequently more breakdown products. The analogy here is with tobacco or with coal. Tobacco is not *per se* carcinogenic, nor is coal, whereas tobacco smoke and coal tar distillates are. If this alternative suggestion holds true the recommendation by Dr. E. D. Acheson for workers to use masks to protect from sawdust would be inadequate unless these masks also absorb smoke particles in the range 1μ down to $10^{-2} \mu$.—I am, etc.,

HENRY BRUNNER,
Division Toxicological Liaison Officer,
Imperial Chemical Industries Ltd.
Slough, Bucks.

REFERENCE

- ¹ Weil, C. S., Smyth, H. F., and Nale, T. W., *Arch. industr. Hyg.*, 1952, 5, 535.

Idiopathic Facial Palsy

SIR,—My attention has been drawn to the letter by Dr. E. D. R. Campbell (1 June, p. 561). I have previously replied to Mr. J. Groves (24 February, p. 508) privately. The evidence on which our views about the management of idiopathic facial palsy are based has been fully described and discussed in a series of publications since 1955.¹ A properly controlled and statistically significant trial of the use of A.C.T.H. gel in the treatment of idiopathic facial palsy has been reported in detail in another previous paper.²

Since then active work has continued, but our present trial has not yet been completed. I have recently analysed the incidence of denervation in an earlier, unpublished series of 110 successive untreated cases of idiopathic facial palsy, first seen within five days of the onset of paralysis, using the strict criteria laid down in our various publications. In 110 consecutive cases complete recovery was found in 63 (57%). Some degree of denervation, however slight, was found in the remaining 47 (43%). It should be noted that the recognition of minimal degrees of denervation requires considerable clinical experience and meticulous observation.—I am, etc.,

D. TAVERNER.

Leeds.

REFERENCES

- ¹ Taverner, D., Fearnley, M. E., Kemble, F., Miles, D. W., and Peiris, O. A., *Brit. med. J.*, 1966, 1, 391.
² Taverner, D., Kemble, F., and Cohen, S. B., *Brit. med. J.*, 1967, 4, 581.

Gall Bladder Displacement

SIR,—Dr. G. G. M. Woods (13 April, p. 100) states in his interesting memorandum that so far as he is aware no previous case has been reported of a gall bladder being displaced to the left upper quadrant by a right-sided abdominal mass. His case, however, is not unique.

In a paper entitled "Dislocation of the Liver"¹ Mr. E. Cope and I described a young male African patient whose liver had been shifted bodily into the left upper abdominal quadrant by the apex of an excessively long sigmoid loop which had become enormously

inflated after undergoing torsion, and had insinuated itself between the right lobe of the liver and the right lateral abdominal wall. At operation it was not possible to restore the liver, other than temporarily, to its normal position and it remained in its extreme position of lateral dislocation for at least eight days after the causative factor had been removed by Paul-Mikulicz resection of the sigmoid colon. The left-sided position of the liver and gall bladder was confirmed by cholecystography, which demonstrated a normal gall bladder overlying the left twelfth rib. Subsequent postoperative radiography showed that the liver had spontaneously reduced itself and returned to its normal situation.—I am, etc.,

J. I. LEVY.

Department of Radiology,
University of the Witwatersrand,
Johannesburg, South Africa.

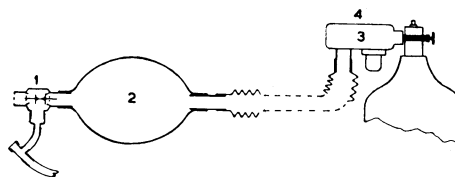
REFERENCE

- ¹ Cope, E., and Levy, J. I., *S. Afr. med. J.*, 1966, 40, 366.

Pain Relief for Crushed Chests

SIR,—Intensive physiotherapy is an essential part of the treatment of patients receiving intermittent positive-pressure respiration (I.P.P.R.) for crushed-chest injuries. Hyperinflation of the lungs followed by vibration of the chest wall in expiration, with subsequent removal of the secretions by tracheal suction, is the preferred technique. Clearly this must be extremely uncomfortable for the patient, and in the past many methods of pain relief have been suggested, ranging from thoracic epidural analgesia to inhalation of nitrous oxide and oxygen mixtures.

A simple, convenient, and practical solution to the problem of combining the advantages of hyperinflation and analgesia occurred to us (see diagram). An Entonox apparatus (3) is attached to the inlet port of a self-filling bag (2), in our case an Ambu resuscitator, after removing the inlet valve to facilitate the connexion. The suction exerted by the expansion of the Ambu bag is sufficient



to draw gas from the Entonox valve, the activating pressure of which is not more than 2.5 cm. H₂O. (This suction was as much as 70 cm. H₂O in one bag which was tested.) If necessary, supplementary flow can be obtained by manual operation of the flow-demand valve (4) of the Entonox apparatus. The inflating valve (1) of the self-filling resuscitator is attached to the tracheostomy tube, and manual controlled ventilation with 50% N₂O:O₂ is performed for a few minutes before commencing vibration physiotherapy and is continued throughout the treatment. Unconsciousness does not occur, but sufficient analgesia results to render the compression of the chest tolerable to the patient.

Overdistension of the self-filling bag does not occur, because flow from the cylinder is stopped as soon as any rise in pressure occurs

in the bag, unless of course manual operation of the flow-demand valve is continued. If a higher concentration of oxygen is required this particular technique would be inappropriate.—We are, etc.,

J. N. LUNN.

B. R. KENNEDY.

Department of Anaesthetics,
Welsh National School of Medicine,
Royal Infirmary,
Cardiff.

Accidental Vaccinia

SIR,—I was most interested in Dr. D. D. Cowen's case report (8 June, p. 627) of vaccinia in a professional boxer caused accidentally and initially confused as a case of herpes zoster. Accidental vaccination of the genitalia is also seen occasionally in the venereal diseases department, and cases of vaccinal vulvitis have previously been described.¹⁻³

A 19-year-old patient attended a venereal diseases department with a bilateral vesicular eruption on her vulva which extended into the groins and backwards on to the perineum as far as the anus. From there it spread outwards radially on to the medial side of each buttock. On speculum examination the cervix was found to be grossly ulcerated. There was no evidence of venereal disease, and serological tests for syphilis were negative. A provisional diagnosis of herpes genitalis with involvement of the cervix was made, although the vesicles were larger than normal. Specimens for virus culture were sent to the Public Health Bacteriological Laboratory at County Hall, where Dr. Joan Davies later reported that vaccinia virus had been isolated in tissue culture from the lesions on the vulva and the cervix. A history of recent vaccination in the husband, who was in the Army, was obtained, and digital transference of the virus seemed likely, since he had no penile lesions. The patient was treated with a 0.1% lotion of idoxuridine to be applied four times daily, and the lesions soon healed.

Since this was the first case report of vaccinal cervicitis from which the virus was isolated, our findings were published jointly.⁴ The case illustrates, moreover, the limitations of clinical observations alone in the accurate diagnosis of a virus disease, conclusive evidence for which often remains with the virology laboratory.—I am, etc.,

DAVID C. HUTFIELD.

Department of Venereal Diseases,
Manchester Royal Infirmary,
Manchester.

REFERENCES

- ¹ Eminson, T. B. F., *Brit. med. J.*, 1888, 2, 1216.
² Morison, A., *Brit. med. J.*, 1888, 2, 1369.
³ Sloan, A. B., *Brit. med. J.*, 1903, 1, 425.
⁴ Hutfield, D. C., and Davies, J. R., *J. Obstet. Gynaec. Brit. Cweth*, 1967, 74, 445.

SIR,—The case described by Dr. D. D. Cowen (8 June, p. 627), where a boxer was vaccinated during the course of close mauling by an opponent who had been recently vaccinated on the shoulder, indicates the unsuitability of the shoulder as a site for vaccination.

I am reminded of a young woman whose husband came home from the Army with a single vaccination vesicle on his left shoulder. During sleep she rested her right cheek against his left shoulder and came up a few days later with a large vaccination vesicle in the middle of her right cheek. This was of