

The two patients presented here had grossly enlarged bilharzial spleens. Both showed an initial high uptake of ^{51}Cr radioactivity over the spleen and both had evidence of hypervolaemia. In both patients, therefore, pooling of red cells had occurred in the spleen, with a markedly increased plasma volume. In the first patient, however, there was in addition to hypervolaemia evidence of intrasplenic red-cell destruction (hypersplenism)— ^{51}Cr red-cell half-life shortened to 14.5 days, a rising accumulation of radioactivity over the spleen, and an increase in spleen:liver ratio.

The studies of Holzbach *et al.* (1964) support the concept that increased spleen size in itself can result in hyperfunction. This does not appear to occur in the enlarged bilharzial spleen, since both in our past work (Farid *et al.*, 1964) and in the two patients presented here intrasplenic red-cell destruction was not related to the size of the spleen. We suggest that, rather than the size of the spleen, a deranged spleen circulation with slowing of passage of blood in the fibrotic and congested bilharzial spleen determines the occurrence of intrasplenic red-cell destruction.

Pranker (1963) stressed the importance of hypervolaemia as a cause of refractory dilution anaemia in patients with enlarged spleens in leukaemias, Gaucher's disease, and thalassaemia. We suggest that this phenomenon of hypervolaemia plays an important part in the production of the chronic anaemia of bilharzial splenomegaly regardless of the occurrence of red-cell destruction by the spleen.

Splenectomy in Case 1 resulted in an immediate haematological improvement; this was probably due to removal of the

site of red-cell destruction, as well as to a reduction in the plasma volume (hence the immediate improvement without relapse). In our opinion splenectomy would also have benefited the second patient, simply by reducing the hypervolaemia and thus raising the haemoglobin. He refused operation.

We wish to thank Dr. Said Razekki, Cairo University, for referring Case 1 to us. We are grateful to Drs. L. F. Miller, J. J. Dempsey, and W. J. Darby for reviewing the manuscript. This work was supported in part by grant AM 08317-01, Contract Nonr 2149 and PL-480 funds.

Z. FARID, M.D., D.T.M.&H.
A. R. SCHULERT, PH.D.
S. BASSILY, M.B.
J. H. NICHOLS, HM₂ U.S.N.
S. GUINDY, B.SC.
M. SHERIF, M.S.
F. RAASCH, M.D.

U.S. Naval Medical Research Unit No. 3, Cairo, Egypt,
and Kasr-el-Aini Hospital, Cairo University.

REFERENCES

- Ebaugh, F. G., jun., Emerson, C. P., and Ross, J. F. (1953). *J. clin. Invest.*, **32**, 1260.
Farid, Z., Prasad, A. S., Schulert, A. R., Sandstead, H. H., and El Rooby, A. S. (1964). *Arch. intern. Med.*, **113**, 37.
Holzbach, R. T., Shipley, R. A., Clark, R. E., and Chudzik, E. B. (1964). *J. clin. Invest.*, **43**, 1125.
Jandl, J. H., Greenberg, M. S., Yonemoto, R. H., and Castle, W. B. (1956). *Ibid.*, **35**, 842.
Pranker, T. A. J. (1963). *Brit. med. J.*, **2**, 517.

Post-decompression Shock Due to Extravasation of Plasma

Brit. med. J., 1966, **2**, 154-155

Although it has for some time been recognized that extravasation of plasma may play an important part in decompression shock (Masland, 1948; Cotes, 1953), very few cases have been reported in which this has been confirmed by successful treatment with plasma or plasma expanders. Moreover, those which have been reported (Cotes, 1953; Brunner *et al.*, 1964; Cockett and Nakamura, 1964) occurred under conditions which are very different from those encountered by industrial workers in compressed air, and may have been thought to be irrelevant to the medical care of such workers. We therefore report a case which followed a normal industrial shift in compressed air (Work in Compressed Air, Special Regulations, 1958).

CASE REPORT

A healthy 26-year-old civil engineer developed a pain in his legs ("bends") after working for his first full shift in compressed air. This recurred after each of two periods of therapeutic recompression; and while the pressure was being reduced following the second of these he also began to vomit and to complain of distension and pain in the abdomen. Small areas of blue discoloration were noticed on his abdomen, chest, and back.

He was transferred for further treatment to the Royal Naval Instructional Diving Section, H.M.S. *Vernon*, Portsmouth. During transfer his condition deteriorated, and on arrival he was deeply cyanosed and shocked. His trunks and limbs were bloated and covered with discrete purple patches that slowly became confluent. Though he was almost pulseless, he was conscious and complained of severe pain in the abdomen and joints, tightness of the chest, and difficulty in breathing.

A third therapeutic compression, this time to a much higher level of pressure, led to some relief of pain and cyanosis, but the blood-pressure remained unrecordable and the urinary output was very small. He was therefore given an intravenous infusion of three bottles of plasma and 1 litre of normal saline. This relieved his symptoms further and raised his blood-pressure to 90/50, but did not result in a diuresis. Because of the oliguria and prolonged hypotension he was transferred to the Royal Portsmouth Hospital. The time schedule of the successive recompressions is shown in Fig. 1.

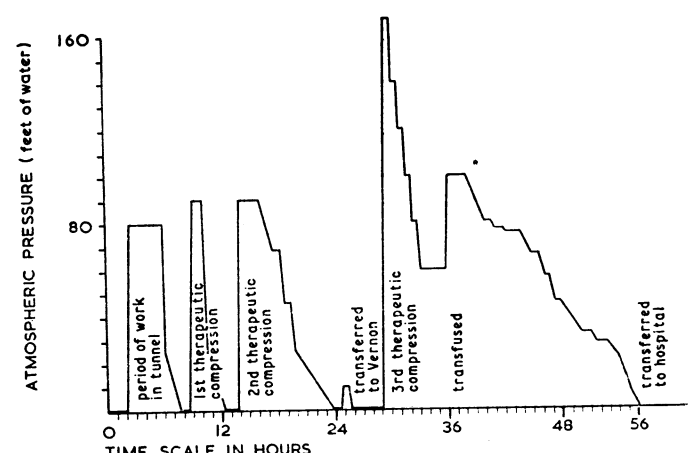


FIG. 1.—Exposure to compressed air.

In hospital he was found to have non-pitting swelling of the limbs and trunk, with extreme tenderness of the muscles. There was severe peripheral vasoconstriction, the pulse was 120, and the blood-pressure 95/60. He was intensely thirsty. His haemoglobin was 126%, blood urea 150 mg./100 ml., and total plasma protein 6.2 g./100 ml. A scanty urine specimen was loaded with albumin and casts; it contained urea 2.3 g./100 ml. and sodium 2 mEq/l.; tests for haemoglobin and myoglobin were negative.

These clinical and laboratory findings suggested a reduction in his blood-volume due to extravasation of plasma and made renal tubular necrosis unlikely. The transfusion of a further three bottles of plasma restored the pulse and blood-pressure to normal and reversed the peripheral vasoconstriction. Shortly afterwards there was a marked diuresis, with a corresponding fall in body weight and reduction in the circumference of his swollen limbs (see Fig. 2). His haemoglobin fell to 92% while his plasma protein concentration remained unchanged. Serial electrocardiograms showed transient ST and T-wave changes, but there was at no time evidence of jugular or pulmonary congestion.

Four weeks after admission to hospital he was discharged, having apparently made a complete recovery.

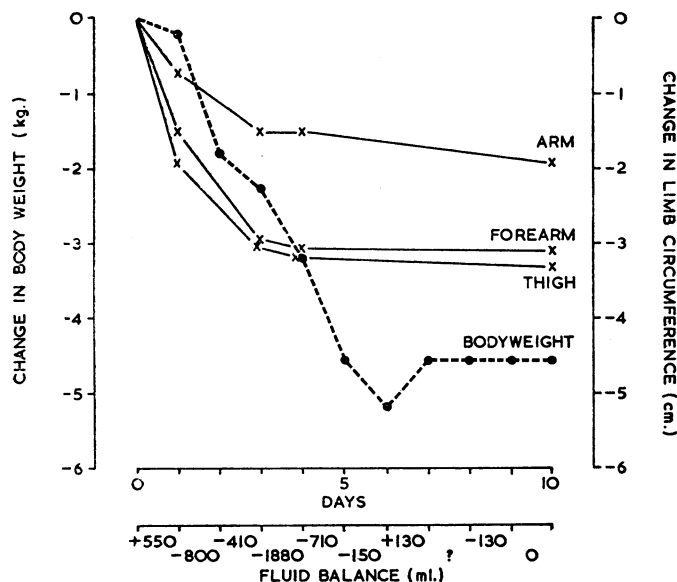


FIG. 2.—Changes in body weight and circumference during recovery.

COMMENT

The compression and decompression routine followed in this patient before his collapse was in accordance with normal industrial practice, and it cannot be established when extravasation

of plasma began. In retrospect it seems possible that the clinical course might have been more favourable if the third decompression had been halted at 25 ft. (7.6 m.) (11 lb./sq. in.—0.77 kg./sq. cm.) when symptoms recurred.

While it is clear that plasma infusion was life-saving in this patient, the part played by recompression in enabling him to recover from the hypovolaemic shock is uncertain. In the cases described by Brunner *et al.* (1964) recompression was probably unimportant. Nevertheless if similar cases are encountered it will probably be wise to treat them with simultaneous recompression and plasma transfusion. It should be pointed out that the most suitable air inlet for the transfusion bottles is a needle or glass tube long enough to project above the surface of the plasma when the bottle is inverted, and this must be inserted before compression.

If the above recommendations are adopted, it will be necessary to provide transfusion equipment and a supply of plasma or a plasma expander wherever work is carried out in compressed air. A liberal supply should be available, since in our case no fewer than six bottles of plasma were required to reverse the hypovolaemia.

We should like to acknowledge the help of the nursing staff of the Royal Portsmouth Hospital, and to thank the Medical Director-General, Royal Navy, for permission to publish information in this article.

E. E. P. BARNARD, M.B., B.S.,
Surgeon Lieutenant-Commander, R.N.
J. M. HANSON, L.M.S.S.A.,
Surgeon Commander, R.N.
M. A. ROWTON-LEE, M.A., B.M., B.CH.,
Surgeon Lieutenant, R.N.
A. G. MORGAN, M.B., CH.B.
A. POLAK, M.D., M.R.C.P.
D. R. TIDY, L.R.C.P., M.R.C.S.

REFERENCES

- Brunner, F. P., Frick, P. G., and Bühlmann, A. A. (1964). *Lancet*, 1, 1071.
Cockett, A. T. K., and Nakamura, R. M. (1964). *Ibid.*, 1, 1102.
Cotes, J. E. (1953). Flying Personnel Research Committee Report No. 825; R.A.F. Institute of Aviation Medicine. Cited by W. G. Malette, J. B. Fitzgerald, and A. T. K. Cockett, *U.S. Aviat. med. Rev.*, 1961, 3, 1.
Masland, R. L. (1948). *Arch. Neurol. Psychiat. (Chic.)*, 59, 445.

Unusual Case of Multiple Spontaneous Perforation of Small Bowel

Brit. med. J., 1966, 2, 155-156

Spontaneous perforation of the small bowel is a rare occurrence. Though the diagnosis has on occasion been made before operation (Funderburk and White, 1962), a presumptive diagnosis of gastro-duodenal perforation or ruptured appendix is made in most cases. This is due to the lack of specific distinguishing features of this much rarer form of alimentary-tract perforation, and to its protean aetiology. The following is yet another case with its own unique and interesting features.

CASE HISTORY

A man aged 50 developed sudden severe central and upper abdominal pain while walking. He vomited, and as severe pain persisted he was admitted to hospital six hours later.

He had a 12-year history suggestive of peptic ulceration of increasing severity, but a barium-meal examination repeated four weeks before admission had shown no ulceration. Apart from his

dyspepsia he regarded himself as a fit man, well able to pursue his occupation as a bricklayer. There had been no history of drug therapy other than antacids, and at no time had there been diarrhoea.

Examination on admission revealed generalized abdominal tenderness and muscle-guarding. The abdomen was scaphoid and silent, and there was loss of liver dullness. A diagnosis of gastro-duodenal perforation was made and laparotomy performed.

Operative Findings.—No lesion was found in the stomach or duodenum, but there was a series of six lesions of the jejunum and ileum beginning about 3 ft. (91 cm.) from the duodeno-jejunal flexure. These lesions appeared as discrete haemorrhagic areas $\frac{1}{2}$ in. (1.25 cm.) in diameter and situated 2 to 4 in. (5 to 10 cm.) apart. One of the lesions had perforated, causing a round punched-out perforation $\frac{1}{2}$ in. (1.25 cm.) in diameter. The wall of the jejunum was thickened but otherwise appeared normal. A considerable amount of fibrinous exudate was present. There was no enlargement of the mesenteric lymph nodes. The spleen was of normal size, but showed purple mottling. At the site of the highest lesion the lumen of the jejunum was reduced by thickening of the wall; this short segment was resected. The perforation was closed and the other lesions were oversewn with seromuscular catgut sutures.

Histological examination revealed oedema, congestion, and marked eosinophilic infiltration of the submucosa, with sloughing of the mucosa (Fig. 1). The appearances suggested a non-specific enteritis.