

## Medical Memoranda

### Skin Grafting in Casualty Departments

*Brit. med. J.*, 1965, 2, 1352

The commonest injury requiring grafting in a casualty department is a partial amputation of the finger-tip without bone exposure. Where bone exposure is slight, free grafting may still be the method of choice after trimming of the bone end (Barclay, 1955).

The split skin graft is usually secured by suturing it to the surrounding skin (Moynihan, 1961). This method inevitably requires the use of a local anaesthetic. There would be a considerable saving of time and trauma if suturing could be avoided, both in the initial treatment and when sutures were removed later.

Fifty cases of skin loss of the finger-tips have been grafted without suturing, and the method and results are discussed. Fourteen of the injuries included skin loss with bone involvement. Thirty-six had skin loss and subcutaneous loss but no bone involvement.

#### TECHNIQUE

The split skin graft is taken from the donor site by the usual methods, and backed on to a tulle dressing. A tulle impregnated

finger, and it should be applied to produce even pressure to the graft at the finger-tip.

The hand and arm are placed in a sling, and the dressing left for ten days, when it is taken down.

#### RESULTS

Forty-five grafts had taken satisfactorily when the dressings were taken down on the tenth day. The other five had partially taken, with up to a third of the graft area not consolidated and moist. Two of these five were amongst the 14 cases with bone involvement, and in three there was no bone involvement. There were no complete failures, and the five partial takes were healed-in without further grafting within a further 21 days. A graft is described as "taken" when the whole of the graft is intact, attached, dry, and stable. A partial take is when a portion of the edge of the graft is moist, broken down, or unstable.

#### COMMENT

The results compare favourably with other reported results. Moynihan (1961) discussed the causes of a 17% failure rate in 100 cases, and suggested that bleeding and haematoma formation beneath the graft probably accounted for most failures.

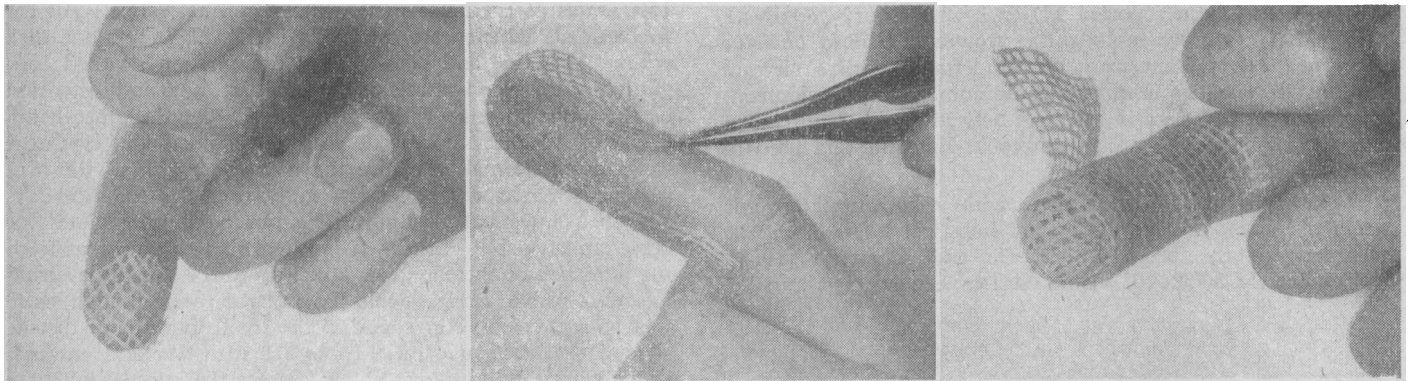


FIG. 1.—Graft applied to recipient area.

FIG. 2.—Graft secured by strip of tulle.

FIG. 3.—Circumferential tulle strip applied.

with framycetin, Sofra-Tulle, has proved extremely satisfactory. This is a white paraffin gauze dressing containing 10% of lanolin in its anhydrous form, and impregnated with framycetin sulphate. The physical properties of this dressing are excellent, and there is a marked absence of tissue maceration. The hydrophilic properties of the anhydrous lanolin may partly account for this.

The graft is cut to the appropriate size and applied to the recipient area (Fig. 1). Whereas a local anaesthetic can be avoided in clean injuries, it may be indicated where debridement is necessary. The graft is then secured by a strip of tulle firmly applied over the finger-tip as shown in Fig. 2, and this in turn secured by a circumferential tulle strip (Fig. 3). When firmly and adequately applied in this fashion, the graft is completely secured and no movement takes place. Any depression in the grafted area will require "filling in" by an additional fold or two of tulle over the depression. Gauze is applied firmly over the finger, and a tube gauze dressing applied over this. Particular attention must be paid to applying this to avoid constrictive turns at the base of the

The absence of complete failures in this series and a complete take of 90% may well be due to the absence of any haematoma formation beneath the grafts. In the absence of sutures it appeared easy for blood or exudate to pass from beneath the graft without any build-up. At least two cases bled after the dressing was applied, with blood coming freely through the dressing. These grafts, however, were not amongst the five partial failures, and undoubtedly the blood flowed freely from beneath the graft without haematoma formation.

J. A. LUNN, M.B., B.S., D.I.H.,  
Slough Industrial Health Service.

#### REFERENCES

- Barclay, T. L. (1955). *Brit. J. plast. Surg.*, 8, 38.  
Moynihan, F. J. (1961). *Brit. med. J.*, 2, 802.