

previous week, when he had developed severe retching after ingesting ibuprofen tablets. On the day of admission he had suddenly collapsed with severe epigastric pain radiating to the chest and both shoulders. Repeated questioning of the patient and his relatives elicited no history of trauma.

On examination his chest was clear and his abdomen soft with normal bowel sounds, but there was slight tenderness in the right hypochondrium. There was no mass or bruit, and rectal examination showed nothing abnormal. Haemoglobin was 8.4 g/dl, with a normochromic, normocytic picture; erythrocyte sedimentation rate 3 mm in first hour; white cell count $13.1 \times 10^9/l$ ($13\ 100/mm^3$); and serum amylase concentration 170 U/l. Urine analysis, electrocardiography, and chest and abdominal x-ray films gave normal results. Nasogastric-tube aspirate contained no blood. At laparotomy about two litres of blood was found in the peritoneal cavity, and there was a large subcapsular haematoma of the spleen, which had ruptured the splenic capsule. The spleen was small and appeared normal apart from two small tears. After splenectomy the patient made an uneventful recovery.

Histologically the spleen showed disruption of the capsule and underlying pulp by recent haemorrhage but there was evidence of early organisation, which suggested delayed rupture. There was no evidence of any other disease.

Comment

When considering the aetiology of a ruptured spleen Orloff and Peskin⁴ specified four criteria that must be fulfilled before the condition can be classed as a spontaneous rupture of the normal spleen—namely, no history of trauma after close questioning; no evidence of any disease that may adversely affect the spleen; no evidence of perisplenic adhesions or scarring of the spleen to suggest previous trauma; and the spleen should be normal on macroscopic and histological examination.

The present case fulfils these criteria and could therefore be classed as a spontaneous rupture, but the retching and vomiting themselves may have led to the rupture. After a prolonged or excessive bout of vomiting a longitudinal tear of the gastric mucosa may develop, as described by Mallory and Weiss.⁵ Possibly after the violent contractions of the diaphragm the patient developed a traction tear of the spleen where the peritoneal reflections meet the splenic capsule. The large subcapsular haematoma, with only two small tears, is compatible with initial subcapsular haemorrhage and secondary capsular rupture. This would account for the interval between retching and collapse and would explain the history and findings at laparotomy.

I am indebted to Professor R Y Calne for advice and guidance and for permission to report this case.

¹ Atkinson, E, *British Medical Journal*, 1874, **2**, 403.

² Wright, L T, and Prigot, A, *Archives of Surgery*, 1939, **39**, 551.

³ Johnson, N, *Australian and New Zealand Journal of Surgery*, 1954, **24**, 112.

⁴ Orloff, M J, and Peskin, G W, *Surgery, Gynecology and Obstetrics*, 1958, **106**, 1.

⁵ Mallory, G K, and Weiss, S, *American Journal of the Medical Sciences*, 1929, **178**, 506.

(Accepted 10 November 1977)

Department of Surgery, Addenbrooke's Hospital, Cambridge CB2 2QQ

W E G THOMAS, MB, FRCS, surgical registrar

Unilateral lumbar sympathectomy due to retroperitoneal tumour

Interruption of the cervical sympathetic pathway caused by invasion by bronchial carcinoma arising in the lung apex has been recognised since the description by Pancoast in 1932.¹ An analogous syndrome of lumbar sympathetic chain interruption by malignant retroperitoneal tumour is not well recognised.

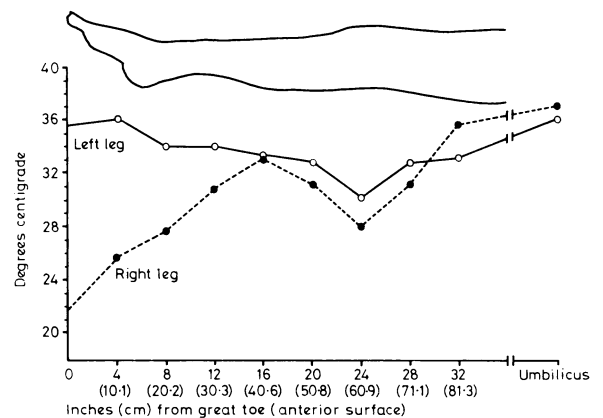
Case report

The patient, a 26-year-old man, developed left loin pain in January 1974. In April 1974 he was admitted to hospital because of continuing pain, anorexia, weight loss of 12.7 kg, intermittent fever, and night sweats. Examination showed a normal abdomen. All movements of the lumbar spine were slightly restricted, and hip flexion on the left side was restricted by pain.

Neurological examination showed the legs were normal. Results of investigations including radiography of the abdomen and lumbar spine and intravenous pycelography were all normal other than an erythrocyte sedimentation rate of 50 mm in the first hour and a cerebrospinal fluid protein of 0.8 g/l (80 mg/100 ml).

The patient was readmitted in June 1974. He was now found to have severe restriction of movement of his lumbar spine with scoliosis to the left, and weakness of hip flexion and knee extension on the left. There was a 2 cm wasting of the left quadriceps compared with the right, but otherwise neurological examination of the legs gave normal results. There was a pronounced difference in the appearance of the two legs. Whereas the right leg was cold and cyanosed peripherally, the left leg was warm and flushed. All pulses were present in both legs, and it appeared that the abnormality lay in the warm left leg rather than the cool right leg. Measurements of skin temperature after the legs had been exposed to room temperature for one hour showed the clinical difference (see figure). On heating the patient's trunk by immersion in a hot bath for 30 minutes the temperatures of the two legs became equal, and there was profuse sweating from the right leg but no sweating from the left. This was shown by the colour change of starch and iodine powder in response to the sweating on the right leg but not on the left. Repeat radiography showed a soft tissue mass in the paraspinal region adjacent to L 1-3, which displaced the lower pole of the left kidney laterally. Exploratory operation to clarify the nature of the mass was advised.

At operation a tumour was found affecting the left psoas muscle. The tumour was fixed and could only be partially removed. The sympathetic chain was not seen. The histology was of a secondary tumour, probably from a teratoma of the testis, although no tumour ever became palpable in the scrotum. Postoperative irradiation and chemotherapy were given, but the tumour continued to invade locally with progressive collapse of lumbar vertebrae. The patient died at home 12 months later and no necropsy was performed.



Skin temperatures of legs after exposure to room temperature for one hour.

Comment

We consider that the development of lumbar sympathectomy in this patient was caused by invasion of the sympathetic chain by malignant tumour. We have been unable to find reference to sympathectomy of this type in reviewing the symptoms of retroperitoneal tumours, although other neurological complications caused by compression of lumbar and sacral nerve routes or compression of the spinal cord are well recognised.^{2,3} Although the changes seen in our patient's leg were obvious, possibly less pronounced changes may easily be overlooked. It may be worth making a deliberate search for these changes in cases of suspected retroperitoneal tumour, as such abnormalities may help to distinguish a malignant from a benign process.

¹ Pancoast, H K, *Journal of the American Medical Association*, 1932, **99**, 1391.

² Pack, G T, and Tabah, E J, *Surgery, Gynecology and Obstetrics*, 1954, **99**, pp 209 and 313.

³ Braasch, J W, and Mon, A B, *Surgical Clinics of North America*, 1967, **47**, 663.

(Accepted 12 October 1977)

Anglesea Road Hospital, Ipswich, Suffolk

R C BROWN, MB, MRCP, registrar (Present address: Department of Medicine, St James's Hospital, Leeds LS9 7TF)

D N MAISEY, MB, MRCP, registrar

J L DAY, MD, MRCP, consultant physician