

At the beginning of 1964 he noticed he was passing more blood per rectum than he felt he could attribute to his haemorrhoids and when the latter were removed the bleeding continued. At a second operation in September 1964 "something the size of a golfball" was removed from his rectum and he was discharged from gaol on account of this. He returned to civilian life and has since then never engaged in his previous practice, although he was sent back to prison in September 1968; prisoners are now permitted to have tobacco. He did, however, continue to pass blood per rectum at intervals.

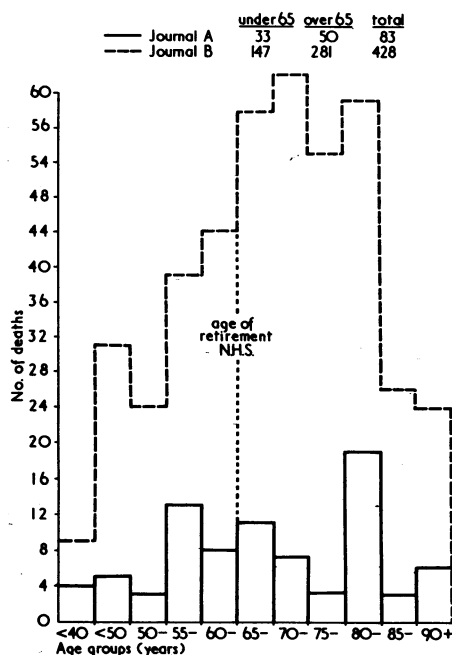
The clinical and histological features are so out of the ordinary that we feel that there may be a relationship between the carcinoma and his eight-year habit of hiding tobacco in his rectum. The tobacco was probably not the cause of the carcinoma, because he was adamant that the quality of the tobacco was in no way altered by its storage in the rectum. Whether the lesion is a consequence of the grease, and whether the cement-bag paper contributed to its development, cannot be determined with certainty.—We are, etc.,

O. A. A. BOCK.
J. S. MARAIS.
J. P. PRICE.

Departments of Medicine, Surgery and Pathology,
University of Stellenbosch,
Karl Bremer Hospital,
Bellville, Cape, South Africa.

Death of Doctors

SIR,—Prognosis is an art that can be applied to one's patients, oneself, or to one's profession. The obituary notices of doctors as reported in the two main medical journals in Britain pose interesting prognostic problems. The first journal, reporting 83 deaths, had a definite bias towards consultants, academics, and doctors working in the Government Services. The second journal



reported a very much larger series but it was obviously more comprehensive in as

much as the majority of the deaths reported were general practitioners.

Three points of interest arose from this survey. The first point (and for those who are contributing to a pension scheme possibly the most important observation) was that one-third of the doctors died before the age of 65. The second point was that there appeared to be a small peak in the under-50 age group in both series. In the first series reported, however, there also appeared to be a second peak at the 80-85 range and this, on a somewhat superficial examination owing to small numbers of reports, appeared to consist very largely of academic and Service personnel. The third point of interest is that the difference between the two series suggests that the majority of deaths occurring among general practitioners is in fact occurring in a slightly later age group than among the consultant staff. The relative figures corresponding with the histogram are as follows:

Journal A: under 65: 33; over 65: 50
Journal B: under 65: 147; over 65: 281

It is hoped that next year a more detailed breakdown will be available of deaths that will occur in this subsequent year, since it is obvious that there are points of clinical importance concerning the method of living and the mode of dying of the members of our profession.—I am, etc.,

DAVID WALLACE.

London S.W.1.

Management of Deep Vein Thrombosis

SIR,—In his article on the medical management of deep vein thrombosis (13 December, p. 678) Dr. P. T. Flute states that continuous intravenous infusion of heparin causes bleeding more frequently than comparable intermittent doses.

As a protagonist of continuous intravenous heparin therapy¹ I was naturally interested in this statement and sought the reference given. The paper quoted² describes a study on patients treated with heparin for various conditions and concludes that the incidence of bleeding is significantly higher in older females. All patients were given heparin intermittently, either by intravenous or by subcutaneous injections. There is no mention at all of continuous infusion.

It is obviously possible that the reference was misquoted. If so, I should be most interested to hear of any study which does show an increased incidence of complications with continuous heparin infusion. Meanwhile I hope that no one has been deterred from using this method.—I am, etc.,

ANTHONY J. HANDLEY.

Medical Unit,
Westminster Hospital Medical School,
London S.W.1.

REFERENCES

- 1 Handley, A. J., *British Medical Journal*, 1967, 2, 482.
- 2 Jick, H., Sloane, D., Borda, I. T., and Shapiro, S., *New England Journal of Medicine*, 1968, 279, 284.

Intraocular Lenses

SIR,—I apologize to Mr. D. P. Choyce (13 December, p. 686) if I seemed rather summary in my reference to his intraocular lenticuli. It is indeed true that they are being inserted with enthusiasm in certain centres, principally in the treatment of monocular aphakia in childhood. But, as an alternative to ordinary spectacles (which were the subject of my article), even Mr. Choyce admits that "they have no place." He accepts that my conclusion—that the operation has generally been abandoned—would probably have been justified ten years ago; and those figures from our major ophthalmic clinics which were available to me showed that there has been a steady and marked decline in the use of these lenses ever since that date, in spite of Mr. Choyce's able advocacy and his many spirited innovations.—I am, etc.,

P. D. TREVOR-ROPER.

London N.W.1.

Respiratory Failure in Chest Wall Injuries

SIR,—The following cases illustrate the difficulty of treating major chest wall injuries in the elderly. These can occur from minor accidents and other injuries are rare. Sputum retention and lung collapse are the most common complication.

A man aged 64 years, known to be a heavy smoker and chronic bronchitic, fell off his bicycle and sustained fractures of his left clavicle and of his second to eighth left ribs. Chest x ray showed no lung or pleural injury. Two days later, x ray showed collapse of the left lung (Fig. 1). In spite of intensive physiotherapy,

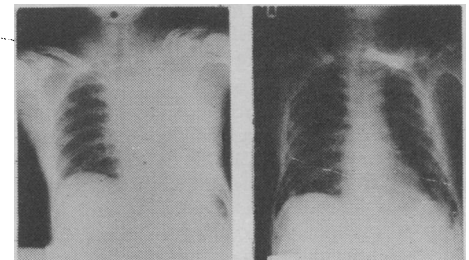


FIG. 1.—Case 1. Collapse of Lung. FIG. 2.—Case 1. On Ventilator.

analgesics, antibiotics, and bronchoscopy, the lung continued collapsed although his general condition remained good. Two weeks later he was intubated and put on intermittent positive pressure ventilation and his lung re-expanded (Fig. 2). However, the lung persistently collapsed whenever the ventilation was stopped and eventually he developed massive pneumonia and died a month later.

A male bronchitic aged 75 years fell off a ladder and sustained fractures of his left clavicle and of his second to eighth left ribs on 12 August 1969. Chest x ray showed surgical emphysema and a haemothorax on the left side. A left intercostal drain was inserted and 400 ml. of blood were drained. Analgesics, antibiotics, and physiotherapy were instituted and he was well enough to sit out of bed. On 16 August x ray (Fig. 3) showed a total collapse of his left lung. A tracheotomy was performed under general anaesthesia and a routine of bronchial suction followed by deep breaths produced by squeezing an Ambu bag in time with inspiration was instituted. The lung expanded and he made an uneventful recovery, the tracheotomy tube