

CPD/CME

Link to this article online  
for CPD/CME credits

# The diagnosis and management of hiatus hernia

Sabine Roman,<sup>1</sup> Peter J Kahrilas<sup>2</sup>

<sup>1</sup>Digestive Physiology, Hospices Civils de Lyon, Lyon I University, and Labtau, INSERM 1032, Lyon, France

<sup>2</sup>Department of Medicine, Division of Gastroenterology, Northwestern University, Chicago, IL 60611-2951, USA

Correspondence to: P J Kahrilas  
p-kahrilas@northwestern.edu

Cite this as: *BMJ* 2014;**349**:g6154  
doi: 10.1136/bmj.g6154

Hiatus hernia is a condition involving herniation of the contents of the abdominal cavity, most commonly the stomach, through the diaphragm into the mediastinum. In the United States, hiatus hernia was listed as a primary or secondary cause of hospital admissions in 142 of 10 000 inpatients between 2003 and 2006.<sup>1</sup> However, the exact prevalence of hiatus hernia is difficult to determine because of the inherent subjectivity in diagnostic criteria. Consequently, estimates vary widely—for example, from 10% to 80% of the adult population in North America.<sup>2</sup> It is, however, accepted that the prevalence of hiatus hernia parallels that of obesity and that it increases with age. The typical symptom of hiatus hernia is gastroesophageal reflux (heartburn, regurgitation). Less common symptoms are dysphagia, epigastric or chest pain, and chronic iron deficiency anaemia. This clinical review summarises the current evidence for the diagnosis and management of hiatus hernia.

## What is hiatus hernia and how is it classified?

The esophagus enters the abdomen through the diaphragmatic hiatus, anchored at the level of the esophagogastric junction by the phrenoesophageal membrane, which also fills the potential space within the hiatus. The hiatus is vulnerable to visceral herniation because it is directly subject to pressure stress between the abdomen and the chest. The diaphragmatic margin of the hiatus is formed by the right diaphragmatic crus. The right crus and lower esophageal sphincter together form the esophagogastric junction, which acts as a barrier against the reflux of gastric content into the esophagus.

Hiatus hernias are subdivided into sliding hernias (85-95%) and paraesophageal hernias (5-15% overall). In cases of sliding hiatus hernia, the diaphragmatic hiatus dilates allowing the cardia of the stomach to herniate upward (fig 1). Paraesophageal hernias are less common (5-15% of all hiatus hernias, fig 1). The defining characteristic of a paraesophageal hernia is asymmetry, such that the herniated viscera, be that stomach, colon, spleen, pancreas, or small intestine, herniates adjacent to the native

## SOURCES AND SELECTION CRITERIA

We based this review on articles identified through a search of PubMed using the term “hiatal hernia” on 12 August 2014. Largely because of the extensive literature on reflux disease and the overlap between reflux disease and hiatus hernia, the search returned over 4500 citations, even when limited to publications in the English language. We favoured what we judged to be topics of interest in primary care.

course of the esophagus. Most paraesophageal hernias also have a sliding component, making them “mixed.”

## What are the risk factors?

Age and obesity are the major risk factors for the development of hiatus hernia.<sup>3-5</sup> People who are overweight or obese compared with people of normal body mass index experience a progressive increase in intra-abdominal pressure, which promotes herniation.<sup>6</sup> In a recent meta-analysis, the odds ratio for hiatus hernia in people with a body mass index greater than 25 was 1.93 (95% confidence interval 1.10 to 3.39), with risk increasing in parallel with body mass index.<sup>7</sup> In a case-control study of patients who underwent upper gastrointestinal endoscopy, the controls had a body mass index of less than 20; the relative risk of hiatus hernia in participants of a healthy weight (body mass index 20-25) was 1.9 (95% confidence interval 1.1 to 3.2), in those who were overweight (25-30) was 2.5 (1.5 to 4.3), and in those who were obese (30-35) was 4.2 (2.4 to 7.6). Recently, researchers found that even a tightened belt around the abdomen of healthy participants induced herniation of the esophagogastric junction within the diaphragmatic hiatus and increased exposure of the distal esophagus to acid.<sup>8</sup> The same phenomenon was observed in those with central obesity. Laxity of the phrenoesophageal membrane, which increases with age, also plays an important role in this susceptibility to hernia.<sup>7</sup>

Paraesophageal hernias are associated with previous gastroesophageal surgery (antireflux procedures, esophagomyotomy, partial gastrectomy). Thoracoabdominal trauma (for example, motor vehicle incidents or falls from a height<sup>9</sup>) might also lead to paraesophageal hernias, with some patients presenting with symptoms months to years after the injury. Skeletal deformities and congenital conditions such as scoliosis, kyphosis, and pectus excavatum, predispose people to hernias. Scoliosis and kyphosis can distort the anatomy of the diaphragm; scoliosis is present in almost a third of patients with giant paraesophageal hernia.<sup>10</sup> Congenital defects are the most common cause of paraesophageal hernia in children, sometimes associated with other malformations, such as intestinal malrotation.<sup>11</sup>

## SUMMARY POINTS

Hiatus hernia refers to herniation of the contents of the abdominal cavity, most commonly the stomach, through the esophageal hiatus of the diaphragm into the mediastinum

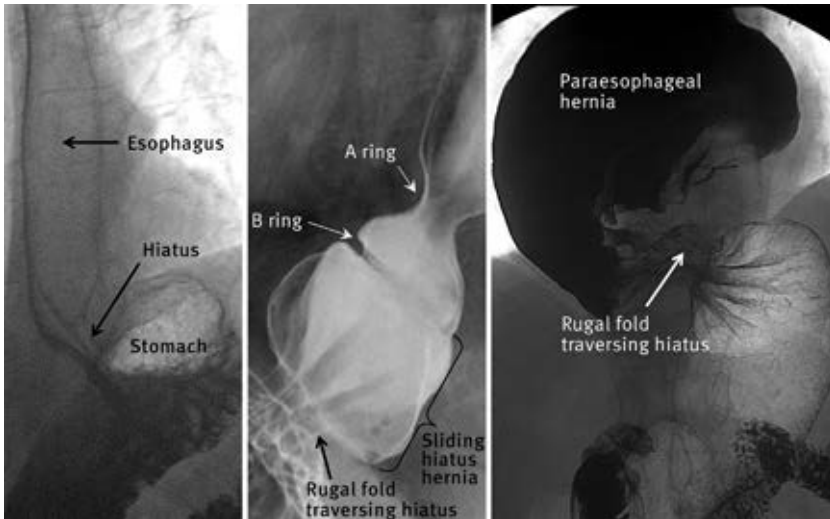
The prevalence of hiatus hernia increases with age and body mass index

In the absence of symptoms, there is no indication to diagnose or treat hiatus hernia

Gastroesophageal reflux disease is the main clinical manifestation of hiatus hernia

Endoscopy, radiology with barium swallow, or high resolution manometry can detect most cases of hiatus hernia

Surgical treatment of hiatus hernia, usually coupled with an antireflux procedure, can be complicated, making a critical risk-benefit assessment mandatory



**Fig 1 | Barium swallow examination. (Left) Normal esophagogastric junction. (Middle) Sliding hiatus hernia with luminal distension distorting the native anatomy. A muscular ring at the proximal margin of the lower esophageal sphincter called the A ring may be visible during swallowing, as well as a second ring, the B ring, that corresponds to the squamocolumnar junction. A hiatus hernia is a  $\geq 2$  cm separation between the B ring and the hiatus (distance indicated by black bracket). The B ring is variably present; in its absence the demonstration of rugal folds traversing the diaphragm is used as the defining criterion for hiatus hernia. In paraesophageal hernia (right) the leading edge is the gastric fundus, and the squamocolumnar junction maintains its native position unless it is a mixed type, in which case there are both sliding and paraesophageal elements. Note the rugal folds traversing the hiatus and that the herniated stomach is asymmetrical and is twisted**

**thebmj.com**

- Previous articles in this series
- ▶ The management of teenage pregnancy (*BMJ* 2014;349:g5887)
  - ▶ Laryngitis (*BMJ* 2014;349:g5827)
  - ▶ Managing the care of adults with Down’s syndrome (*BMJ* 2014;349:g5596)
  - ▶ Managing common symptoms of cerebral palsy in children (*BMJ* 2014;349:g5474)
  - ▶ Bariatric surgery for obesity and metabolic conditions in adults (*BMJ* 2014;349:g3961)
  - ▶ Diagnosis and management of prolactinomas and non-functioning pituitary adenomas (*BMJ* 2014;349:g5390)

**What are the symptoms?**

Hiatus hernia can exacerbate gastroesophageal reflux by several mechanisms. Separation between the lower esophageal sphincter and crus can lead to an impaired antireflux barrier,<sup>12</sup> particularly in circumstances of acute intra-abdominal pressure, as occurs with bending or coughing. Acidic gastric juice layered on top of recently ingested food and extending into the hernia, the “acid pocket,” may then reflux into the esophagus.<sup>13</sup> Once reflux has occurred, hiatus hernia impairs the mechanism of esophageal acid clearance. Hence, increasing size of the hernia is associated with greater exposure to esophageal acid both by increasing the occurrence of reflux and by impairing the process of esophageal acid clearance.<sup>14</sup>

No symptom is specific for hiatus hernia. However, the presence of hernia might be suspected with symptoms of gastroesophageal reflux, including heartburn, regurgitation, or dysphagia. In cases of paraesophageal hernia, dysphagia may be caused by the herniated stomach compressing the distal esophagus, resulting in an extrinsic mechanical obstruction. Sliding hiatus hernia may also promote dysphagia secondary to stasis in the herniated stomach, or functional obstruction at the level of the crural diaphragm, or both.<sup>15</sup>

Though the major importance of sliding hernias is their association with gastroesophageal reflux disease (GERD), the main clinical importance of paraesophageal hernias lies in their potential for obstruction, ischemia, or volvulus.<sup>2</sup> Paraesophageal hernias either cause no symptoms or are associated with non-specific, intermittent symptoms such as chest pain, epigastric pain, postprandial fullness, nausea, and retching; symptoms potentially related to ischemia or obstruction.

Sliding hiatus hernias may also lead to bleeding and chronic iron deficiency anemia as a consequence of Cameron erosions.<sup>16 17</sup> These linear gastric erosions can occur on the rugae where they cross the hiatal constriction, especially with large hernias.

**When should patients with suspected hiatus hernia be referred?**

In the absence of symptoms potentially related to hiatus hernia there is no indication to pursue a diagnosis of hiatus hernia. Even with typical symptoms of GERD (heartburn, regurgitation), but no alarm signs (dysphagia, weight loss, bleeding, anemia), empiric treatment with proton pump inhibitors without diagnostic testing is standard practice.<sup>18</sup> Specialist referral is necessary if symptomatic treatment is ineffective or there are alarm signs that might be experienced by patients with hiatus hernia but could be related to ulcers, tumours, or strictures. Hence affected patients should be evaluated using upper endoscopy. Indications for non-urgent upper endoscopy include age greater than 50 years with longstanding symptoms of reflux and atypical symptoms of GERD (chest pain, epigastric pain, postprandial fullness, nausea, or retching).

**How is hiatus hernia diagnosed?**

Typically, hiatus hernia is intermittent, especially when small. Intermittency coupled with an element of subjectivity in distinguishing a small hernia from normal with all investigational techniques results in a circumstance in which no investigational technique has a definable sensitivity or specificity for the detection of hiatus hernia. The main indication for these investigations is to rule out potential complications of hiatus hernia and to detect other possible diagnoses such as ulcers, strictures, or tumours.

**Endoscopy**

The clinical indications for endoscopy of the upper gastrointestinal tract include symptoms typical of GERD but that are refractory to treatment, alarm signs (dysphagia, bleeding, weight loss, anemia), or symptoms in patients older than 50 years.<sup>18</sup> In the absence of symptoms, there is no clinical indication to systematically search for hiatus hernia. There is no absolute contraindication for upper gastrointestinal endoscopy. Major complications such as perforation or aspiration are rare, occurring in less than 1 per 1000 cases.

Sliding hiatus hernia is diagnosed when the apparent separation between the squamocolumnar junction (the transition from esophageal to gastric epithelium) and the constriction formed as the stomach traverses the hiatus is greater than 2 cm. Asking patients to inspire while the proximal stomach is observed might help to localize the hiatus. Dilation of the hiatus can also be seen from a retroflexed view. However, the endoscopic diagnosis of hiatus hernia has limitations: the esophagogastric junction is mobile (for example, with swallowing, breathing, and straining), which may lead to intermittent hernia; metaplasia (Barrett’s esophagus) or inflammation can make it difficult to localize the native squamocolumnar junction; and excess air insufflation of the stomach might exaggerate the size of the hernia.

**QUESTIONS FOR FUTURE RESEARCH**

Should surgery be routinely advised for paraesophageal hernia in patients without symptoms?  
When should bariatric surgery be used instead of a fundoplication to treat gastroesophageal reflux disease?

Upper gastrointestinal endoscopy is essential in the evaluation of potential complications from hiatus hernia that may explain symptoms (bleeding, dysphagia, pain). The size of the hiatus hernia is the main determinant of the presence and severity of esophagitis.<sup>19</sup> Cameron erosions should be considered in cases of chronic anemia or bleeding, or both. Even without visualization of these, the finding of a large hiatus hernia in association with a normal colonoscopy result, otherwise normal upper gastrointestinal endoscopy result, and normal capsule endoscopy (small bowel endoscopy using the ingestion of a capsule) result might be considered an adequate explanation for iron deficiency anemia, with intermittent Cameron erosions being a diagnosis of exclusion.

**Radiologic imaging**

Hiatus hernia can be diagnosed by radiology of the upper gastrointestinal tract (fig 1), albeit with poor sensitivity for mucosal complications. Radiology is usually indicated in the presurgical evaluation. Risks are related to radiation exposure and allergy to barium or iodine. Pregnancy is a contraindication. Computed tomography is not a standard procedure in patients with hiatus hernia. It might be useful in the assessment of gastric volvulus in cases of paraesophageal hernia and the detection of other herniated organs. Hiatus hernia might also be found by chance during computed tomography for another indication.

**High resolution manometry and reflux monitoring**

Functional esophageal testing using manometry (assessment of esophageal contractile function using an esophageal catheter) and reflux monitoring (assessment of reflux of gastric content into the esophagus using an esophageal catheter) is indicated when surgery is being considered to control symptoms of gastroesophageal reflux related to

a hiatus hernia. Risks of functional testing are minimal. High resolution manometry with topographic pressure plotting depicts the pressure profile across the esophagogastric junction (fig 2), helping to locate the crural diaphragm and the lower esophageal sphincter<sup>20</sup> in real time, potentially making it a more accurate depiction of the relation between these structures; a separation greater than 2 cm between these defines hiatus hernia. However, separation between lower esophageal sphincter and the crural diaphragm might also be intermittent. Hence, as with endoscopy and radiology, the accuracy of high resolution manometry in the diagnosis of hiatus hernia is not perfect. Manometry also verifies the integrity of esophageal peristalsis, which is considered essential before undergoing fundoplication surgery. Reflux monitoring is not useful in diagnosing hiatus hernia, but it is indicated to verify the presence of pathological GERD in the absence of high grade reflux esophagitis.

**What are the treatment options?**

Not all hiatus hernias cause symptoms and in the absence of symptoms, treatment is rarely indicated. Paraesophageal hernias might be considered for treatment because of potential catastrophic complications.<sup>21</sup> Otherwise, drug treatment of hiatus hernia aims to limit the consequences of GERD. The surgical approach consists of restoring the stomach into the abdominal cavity and compensating for anatomic abnormalities to approximate normal physiology of the esophagogastric junction.

**Medical approach**

Alleviation of the symptoms of GERD is the cornerstone for treatment of hiatus hernia. This is usually achieved indirectly with drugs that inhibit gastric acid secretion, thereby preventing symptoms or complications related to the reflux of gastric acid into the esophagus. Proton pump inhibitors (PPIs) are the most potent inhibitors of gastric acid secretion and the most effective drugs to treat reflux esophagitis and typical symptoms of GERD.<sup>22-24</sup> Histamine 2 receptor antagonists and antacids are alternatives to PPIs, though they are substantially less effective.<sup>22-24</sup> As reflux is usually a chronic problem and the treatment approach of inhibiting acid secretion is compensatory rather than curative, long term PPI treatment of GERD is more the rule than the exception. The usual recommendation is to use the minimal PPI dose that is sufficient to control symptoms. Some patients even prefer on-demand treatment for intermittent symptoms, a practice common in the United States, where PPIs are now available without prescription. Adverse effects of PPIs include headache (<5%), diarrhea (<5%), and an increased susceptibility to gastrointestinal pathogens, including infectious gastroenteritis, and colitis caused by *Clostridium difficile*.<sup>25</sup> Severe adverse events include rare cases of acute interstitial nephritis and reversible severe hypomagnesemia. Long term treatment may predispose to osteopenia and small intestinal bacterial overgrowth, although supportive evidence for this is weak.

Histamine 2 receptor antagonists, antacids, and alginate-antacid combinations can reduce postprandial exposure of the esophagus to acid<sup>26</sup> and thus decrease the




Fig 2 | High resolution manometry showing pressure variations recorded along the esophagus (represented as pressure topography plots). Three high pressure zones are identified: upper esophageal sphincter, lower esophageal sphincter, and crural diaphragm. Swallow is followed by a propagated contraction along the esophagus. Lower esophageal sphincter and crural diaphragm are separated by more than 2 cm, defining hiatus hernia

ADDITIONAL EDUCATIONAL RESOURCES

Information for healthcare professionals

Roman S, Kahrilas PJ. Hiatal hernia. In: Principles of deglutition: a multidisciplinary text for swallowing and its disorders. Springer, 2013:753-68—Provides details of physiopathology and diagnosis of hiatus hernia

Information for patients

The following resources explain the causes and symptoms of hiatus hernia and provide an overview of tests and treatment

National Institutes of Health. Hiatal hernia ([www.ncbi.nlm.nih.gov/pubmedhealth/PMH0002122/](http://www.ncbi.nlm.nih.gov/pubmedhealth/PMH0002122/))

Mayo Clinic. Hiatus hernia ([www.mayoclinic.org/diseases-conditions/hiatal-hernia/basics/definition/con-20030640](http://www.mayoclinic.org/diseases-conditions/hiatal-hernia/basics/definition/con-20030640))

UpToDate: patient information. Hiatus hernia ([www.uptodate.com/contents/hiatal-hernia-the-basics?source=search\\_result&search=hiatus+hernia&selectedTitle=2~75](http://www.uptodate.com/contents/hiatal-hernia-the-basics?source=search_result&search=hiatus+hernia&selectedTitle=2~75))

symptoms of GERD.<sup>22</sup> These treatments might be utilized in an on-demand fashion by patients with moderate symptoms or as add-on treatment if symptoms occur despite PPI treatment.

Minimal evidence supports the efficacy of prokinetic drugs as monotherapy or as add-on treatment in patients with GERD. Guidelines do not recommend the use of metoclopramide or domperidone in uncomplicated GERD and even advise against metoclopramide because of potential neurologic side effects, including tardive dyskinesia.<sup>23</sup> QT prolongation possibly leading to lethal cardiac arrhythmias is another potentially dangerous side effect limiting the usefulness of dopaminergic or serotonergic prokinetics (domperidone, cisapride) in the treatment of GERD.<sup>24</sup>

Though modifications to lifestyle are routinely advocated, evidence supporting their effectiveness is generally weak.<sup>22</sup> Nonetheless, they should be selectively advised according to patients' circumstances. Lifestyle modifications entail weight loss, avoidance of specific "trigger" foods, smaller meals, not eating late in the evening, and postural adjustments such as remaining upright after eating and elevating the head of the bed for sleep. Raising the head of the bed by 6-8 inches (15-20 cm) and avoidance of food three hours before bedtime are especially pertinent for patients who are prone to symptoms at night.

**Surgical approach**

Surgery is the only way to restore herniated organs into the abdominal cavity and to compensate for the functional abnormalities associated with hiatus hernia. The standard procedure is currently laparoscopic fundoplication. The essential components of this technique are mobilization of the distal esophagus, reduction of the associated hiatus hernia, and either partial (Toupet 270°) or complete (Nissen 360°) fundoplication around the esophagus (fig 3).<sup>27</sup> Recent guidelines emphasize that surgical repair of a sliding hernia is not necessary in the absence of GERD.<sup>28</sup> When symptoms of GERD and sliding hiatus hernia are present, surgical treatment might be considered for patients with persistent regurgitation despite medical treatment, symptoms such as chronic cough that prove refractory to PPI treatment, intolerance to PPIs, or (rarely) refractory esophagitis. The main side effects of fundoplication are dysphagia and bloating, which vary in severity from mild

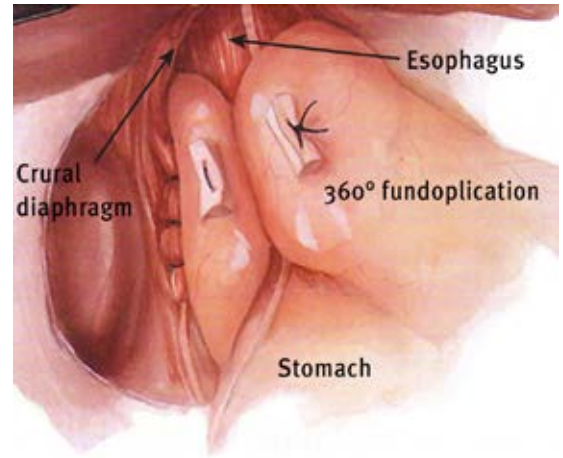


Fig 3 | Nissen fundoplication. The essential features of fundoplication are to mobilize the lower esophagus, reduce the hiatus hernia, and wrap the gastric fundus around the esophagus. During the procedure the proximal stomach is wrapped 360° around the gastroesophageal junction. Adapted from Peters and DeMeester<sup>22</sup>

to severe. The risk of major complications or death is about 1-2%. Importantly, efficacy data from community practice report that up to 30% of patients resume treatment with PPIs within five years of antireflux surgery,<sup>29</sup> and accumulating evidence suggests that the risk of recurrence is much greater in the presence of abdominal obesity.<sup>30</sup> Redo fundoplication is also common, accounting for up to 50% of operations performed at some referral centres.<sup>31</sup>

Laparoscopic repair of paraesophageal hernia is a complex operation because in many cases the associated anatomic distortion is severe.<sup>33</sup> Surgery includes complete resection of the hernia sac from the mediastinum, mobilization of the esophagus, closure of the hiatus (sometimes using mesh), and fundoplication. Given this complexity, the risk of surgery must be balanced against the underlying risk of complications from paraesophageal hernia,<sup>28</sup> currently a topic of considerable controversy. Few data are available on the risk of progression from asymptomatic to symptomatic paraesophageal hernia: it might be around 14% per year.<sup>28</sup> However, the risk of developing acute symptoms that require emergency surgery is less than 2%. Finally, the mortality rate associated with repair of paraesophageal hiatus hernia might be up to 5% when surgery is performed in an emergency situation. The recurrence rate for paraesophageal hernia after repair is up to 50% at five years.

**TIPS FOR NON-SPECIALISTS**

- Hiatus hernia is prevalent in the general population
- Hiatus hernia can be asymptomatic
- Hiatus hernia should be investigated in patients with gastroesophageal reflux disease incompletely controlled by medical treatment, bleeding, weight loss, dysphagia, or chronic iron deficiency anaemia
- Paraesophageal hernia should be considered in patients with non-specific and troublesome dyspeptic symptoms
- Medical treatment for gastroesophageal reflux symptoms is the preferred management strategy, irrespective of hiatus hernia

**Competing interests:** We have read and understood the BMJ policy on declaration of interests and declare the following interests: SR carries out consultancy work for Given Imaging, sits on its advisory board, and has received a grant from the company for a study entitled “Normal values for 3D ano-rectal high resolution manometry.”

**Provenance and peer review:** Commissioned; externally peer reviewed.

- 1 Thukkani N, Sonnenberg A. The influence of environmental risk factors in hospitalization for gastro-oesophageal reflux disease-related diagnoses in the United States. *Aliment Pharmacol Ther* 2010;31:852-61.
- 2 Skinner DB, ed. Hernia (hiatal, traumatic, and congenital). 4th ed. Saunders, 1985.
- 3 Sakaguchi M, Oka H, Hashimoto T, Asakuma Y, Takao M, Gon G, et al. Obesity as a risk factor for GERD in Japan. *J Gastroenterol* 2008;43:57-62.
- 4 Wilson LJ, Ma W, Hirschowitz BI. Association of obesity with hiatal hernia and esophagitis. *Am J Gastroenterol* 1999;94:2840-4.
- 5 Stene-Larsen G, Weberg R, Froyshov Larsen I, Bjortuft O, Hoel B, Berstad A. Relationship of overweight to hiatus hernia and reflux oesophagitis. *Scand J Gastroenterol* 1988;23:427-32.
- 6 Pandolfino JE, El-Serag HB, Zhang Q, Shah N, Ghosh SK, Kahrilas PJ. Obesity: a challenge to esophagogastric junction integrity. *Gastroenterology* 2006;130:639-49.
- 7 Menon S, Trudgill N. Risk factors in the aetiology of hiatus hernia: a meta-analysis. *Eur J Gastroenterol Hepatol* 2011;23:133-8.
- 8 Lee YY, Wirz AA, Whiting JG, Robertson EV, Smith D, Weir A, et al. Waist belt and central obesity cause partial hiatus hernia and short-segment acid reflux in asymptomatic volunteers. *Gut* 2014;63:1053-60.
- 9 Eren S, Ciris F. Diaphragmatic hernia: diagnostic approaches with review of the literature. *Eur J Radiol* 2005;54:448-59.
- 10 Schuchert MJ, Adusumilli PS, Cook CC, Colovos C, Kilic A, Nason KS, et al. The impact of scoliosis among patients with giant paraesophageal hernia. *J Gastrointest Surg* 2011;15:23-8.
- 11 Karpelowsky JS, Wieselthaler N, Rode H. Primary paraesophageal hernia in children. *J Pediatr Surg* 2006;41:1588-93.
- 12 Kahrilas PJ, Lin S, Chen J, Manka M. The effect of hiatus hernia on gastro-oesophageal junction pressure. *Gut* 1999;44:476-82.
- 13 Beaumont H, Bennink RJ, de Jong J, Boeckxstaens GE. The position of the acid pocket as a major risk factor for acidic reflux in healthy subjects and patients with GORD. *Gut* 2010;59:441-51.
- 14 Jones MP, Sloan SS, Jovanovic B, Kahrilas PJ. Impaired egress rather than increased access: an important independent predictor of erosive oesophagitis. *Neurogastroenterol Motil* 2002;14:625-31.
- 15 Pandolfino JE, Kwiatek MA, Ho K, Scherer JR, Kahrilas PJ. Unique features of esophagogastric junction pressure topography in hiatus hernia patients with dysphagia. *Surgery* 2010;147:57-64.
- 16 Annibale B, Capurso G, Chistolini A, D'Ambra G, DiGiulio E, Monarca B, et al. Gastrointestinal causes of refractory iron deficiency anemia in patients without gastrointestinal symptoms. *Am J Med* 2001;111:439-45.
- 17 Maganty K, Smith RL. Cameron lesions: unusual cause of gastrointestinal bleeding and anemia. *Digestion* 2008;77:214-7.
- 18 Shaheen NJ, Weinberg DS, Denberg TD, Chou R, Qaseem A, Shekelle P. Upper endoscopy for gastroesophageal reflux disease: best practice advice from the clinical guidelines committee of the American College of Physicians. *Ann Intern Med* 2012;157:808-16.
- 19 Jones MP, Sloan SS, Rabine JC, Ebert CC, Huang CF, Kahrilas PJ. Hiatal hernia size is the dominant determinant of esophagitis presence and severity in gastroesophageal reflux disease. *Am J Gastroenterol* 2001;96:1711-7.
- 20 Pandolfino JE, Kim H, Ghosh SK, Clarke JO, Zhang Q, Kahrilas PJ. High-resolution manometry of the EG: an analysis of crural diaphragm function in GERD. *Am J Gastroenterol* 2007;102:1056-63.
- 21 Poulouse BK, Gosen C, Marks JM, Khaitan L, Rosen MJ, Onders RP, et al. Inpatient mortality analysis of paraesophageal hernia repair in octogenarians. *J Gastrointest Surg* 2008;12:1888-92.
- 22 Kahrilas PJ, Shaheen NJ, Vaezi MF, Hiltz SW, Black E, Modlin IM, et al. American Gastroenterological Association medical position statement on the management of gastroesophageal reflux disease. *Gastroenterology* 2008;135:1383-91, 91 e1-5.
- 23 Katz PO, Gerson LB, Vela MF. Guidelines for the diagnosis and management of gastroesophageal reflux disease. *Am J Gastroenterol* 2013;108:308-28; quiz 29.
- 24 Fuchs KH, Babic B, Breithaupt W, Dallemagne B, Fingerhut A, Furnee E, et al. EAES recommendations for the management of gastroesophageal reflux disease. *Surg Endosc* 2014;28:1753-73.
- 25 Yang YX, Metz DC. Safety of proton pump inhibitor exposure. *Gastroenterology* 2010;139:1115-27.
- 26 Rohof WO, Bennink RJ, Smout AJ, Thomas E, Boeckxstaens GE. An alginate-antacid formulation localizes to the acid pocket to reduce acid reflux in patients with gastroesophageal reflux disease. *Clin Gastroenterol Hepatol* 2013;11:1585-91; quiz e90.
- 27 Rydberg L, Ruth M, Lundell L. Mechanism of action of antireflux procedures. *Br J Surg* 1999;86:405-10.
- 28 Kohn GP, Price RR, DeMeester SR, Zehetner J, Muensterer OJ, Awad Z, et al. Guidelines for the management of hiatal hernia. *Surg Endosc* 2013;27:4409-28.
- 29 Vakil N, Shaw M, Kirby R. Clinical effectiveness of laparoscopic fundoplication in a US community. *Am J Med* 2003;114:1-5.
- 30 Morgenthal CB, Lin E, Shane MD, Hunter JG, Smith CD. Who will fail laparoscopic Nissen fundoplication? Preoperative prediction of long-term outcomes. *Surg Endosc* 2007;21:1978-84.
- 31 Hunter JG, Smith CD, Branum GD, Waring JP, Trus TL, Cornwell M, et al. Laparoscopic fundoplication failures: patterns of failure and response to fundoplication revision. *Ann Surg* 1999;230:595-604; discussion 04-6.
- 32 Peters JH, DeMeester TR, eds. Minimally invasive surgery of the foregut. Quality Medical Publishing, 1994.
- 33 Morrow EH, Oelschlager BK. Laparoscopic paraesophageal hernia repair. *Surg Laparosc Endosc Percutan Tech* 2013;23:446-8.

**ANSWERS TO ENDGAMES, p 36**

For long answers go to the Education channel on [thebmj.com](http://thebmj.com)

**STATISTICAL QUESTION**

**Multiple hypothesis testing and Bonferroni’s correction**

Statements *a*, *c*, and *d* are true, whereas *b* is false.

**ANATOMY QUIZ**

**Lateral view from a barium enema study**

- A: Lumbar vertebra (L5)
- B: Sacrum
- C: Sigmoid colon
- D: Femoral head
- E: Rectum

**PICTURE QUIZ**

**Disseminated papular lesions in an HIV infected patient**

- 1 The differential diagnosis of disseminated papular skin lesions in an HIV positive patient with a low CD4 count includes disseminated viral, bacterial, and fungal infections; neoplastic disorders; and drug reactions.
- 2 On the basis of the systemic symptoms (weight loss, fever, hepatomegaly, and lymphadenopathy) and the geographical location, the most likely diagnosis is disseminated *Penicillium marneffe* infection.
- 3 Microbiological isolation of *P marneffe* is the gold standard for diagnosis, although serological and molecular rapid diagnostic tools are under investigation.
- 4 Intravenous amphotericin B followed by oral itraconazole is the preferred regimen for the treatment of disseminated penicilliosis.