

Gestational trophoblastic disease: current management of hydatidiform mole

N J Sebire, M J Seckl

Trophoblastic Disease Centre,
Department of Medical Oncology,
Charing Cross Hospital, London
W6 8RF

Correspondence to: M J Seckl
m.seckl@imperial.ac.uk

Cite this as: *BMJ* 2008;337:a1193
doi:10.1136/bmj.a1193

Gestational trophoblastic disease consists of a pregnancy related group of disorders that were often fatal in the past. Much has been learnt in the past 50 years, however, and most women can now be cured. The United Kingdom has a highly centralised system for registering, monitoring, and treating women with this disease that requires close collaboration with non-specialist units and general practitioners. We review the important features for detection and successful management of the most common form of this disease, hydatidiform mole. The evidence is based on published studies—mostly retrospective case series—and expert opinion.

How common is gestational trophoblastic disease?

Hydatidiform mole affects 1-3 in every 1000 pregnancies. About 10% of hydatidiform moles transform into one of the malignant forms of gestational trophoblastic disease, known as gestational trophoblastic neoplasia (box 1).

What is hydatidiform mole and who gets it?

Hydatidiform moles are abnormal conceptions with excessive placental, and little or no fetal, development. The two major types—complete and partial—have distinctive histological and genetic features (boxes 2 and 3).¹⁻⁷ Hydatidiform moles affect women throughout the reproductive age range but are more common at the extremes of the range.⁸ Women under 16 have a six times higher risk of developing the disease than those aged 16-40, and women who conceive aged 50 or more have a one in three chance of having a molar pregnancy. The previously noted higher incidence in women of Far Eastern origin, although still greater than for white women, now more closely matches that seen in the UK and other Western countries. The reasons for this are not clear but might reflect dietary changes.⁹ Hydatidiform moles can also rarely develop (1/100 000 pregnancies) as part of twin or multiple gestations.¹⁰

How does gestational trophoblastic disease present clinically?

In the UK, most women with hydatidiform mole present with vaginal bleeding or suspected miscarriage in early pregnancy, which prompts pelvic

Box 1 Classification of gestational trophoblastic disease

Benign forms

- Partial hydatidiform mole
- Complete hydatidiform mole

Malignant forms

- Invasive hydatidiform mole
- Choriocarcinoma
- Placental site trophoblastic tumour
- Epithelioid trophoblastic tumour

ultrasonography, although in one observational study of 41 women with confirmed hydatidiform mole, 40% were asymptomatic, and the disorder was detected after routine ultrasonography in early pregnancy. Most presented with vaginal bleeding; only 2% reported hyperemesis, and no other systemic symptoms were reported (box 4).¹¹ Vaginal bleeding is common in early pregnancy and often not important, but it should prompt an early ultrasound examination.

How is a diagnosis of gestational trophoblastic disease made?

The grape-like or hydropic change most commonly found (box 3) occurs mainly in the second trimester, and ultrasonography shows a classic snowstorm-like appearance. However, most women develop vaginal bleeding in the first trimester and undergo uterine evacuation around 10 weeks' gestation in the UK.¹² At this time, minimal hydropic change is present, which makes early sonographic diagnosis less reliable. Two recent retrospective studies identified molar pregnancy by ultrasonography in the first and early second trimester in only 40-60% of cases.^{12 13} In the largest study of 1000 patients, 40% of cases (80% of complete moles and 30% of partial moles) had a sonographic diagnosis suggesting molar pregnancy. The sonographic diagnosis was mostly simple miscarriage, with the diagnosis of hydatidiform mole being dependent on subsequent routine histological examination of the products of conception.¹²

SOURCES AND SELECTION CRITERIA

We based this review on current Royal College of Obstetricians and Gynaecologists' guidelines and a search of PubMed to identify the best available evidence using the search words "hydatidiform", "trophoblastic disease", and "trophoblastic neoplasia".

Box 2 Genetics of hydatidiform mole

Complete and partial hydatidiform moles are genetically distinct, but both overexpress paternal genes. Complete hydatidiform moles are almost always diploid, as a result of endoreduplication (duplication without mitosis) after monospermic fertilisation or, more rarely, dispermic fertilisation of an anucleate oocyte. Partial hydatidiform moles are almost always triploid, as a result of dispermic fertilisation. Clues to the causative genes in gestational trophoblastic disease have come from linkage studies in families with repetitive molar pregnancies in which the mole is biparental in origin but pathologically indistinguishable from androgenetic complete hydatidiform mole. In these unusual cases, mutations of a gene (NALP7/NLRP7) on chromosome 19 are thought to cause the disease. However, other genes are probably involved, because not all familial cases map to this chromosome.

The lung is the most common site of metastatic disease, and this may be associated with dyspnoea, cough, haemoptysis, and chest pain, but any site can be affected. Consequently, gestational trophoblastic disease should be considered in the differential diagnosis in women of child bearing age who present with possible metastatic disease. A positive serum or urine test for human chorionic gonadotrophin will suggest the diagnosis and should prompt referral to a gestational trophoblastic disease centre.¹⁴

How are hydatidiform moles initially managed?

Because the diagnosis of hydatidiform mole is often unsuspected until histological examination, all products of conception from non-viable pregnancies must be submitted for routine pathological evaluation. If a diagnosis is not made, malignant change will not be subsequently monitored and women will have a significantly increased risk of life threatening complications, such as uterine perforation and severe haemorrhage. In a recent study of 51 women with hydatidiform mole, those without a diagnosis at the time of termination were significantly more likely to have subsequent life threatening complications and to need surgical intervention and chemotherapy.¹⁴

Suspected cases are initially managed with suction uterine evacuation (sharp curettage is avoided to minimise the risk of uterine perforation).¹⁵ The use of prostanoids to ripen the cervix in nulliparous women is discouraged in case it induces uterine contractions and leads to trophoblastic embolisation to the pulmonary

vasculature and disseminated disease. Usually, initial evacuation removes most molar material and residual tissue involutes. Sometimes the first evacuation is incomplete, with molar material left behind in the uterine cavity; further evacuation within the next few days may help reduce symptoms and prevent the need for chemotherapy. However, if little residual material is left after the initial procedure, the Royal College of Obstetricians and Gynaecologists' (RCOG) guidelines do not recommend further evacuation for persistent disease—continued vaginal bleeding, regrowth of molar material, or rising or persistently high human chorionic gonadotrophin—at least until after consultation with a specialist centre.^{15 16}

What is the risk of malignancy and should women be screened?

In benign disease, human chorionic gonadotrophin concentrations spontaneously return to normal, but in women who develop neoplasia the concentration plateaus or rises (fig 2). The risk of malignancy after a complete or partial hydatidiform mole is 15% and 0.5%, respectively.¹⁷ This is identified in almost all cases by regularly measuring human chorionic gonadotrophin with an assay that detects all the different forms of the hormone seen in cancer¹⁸ with a sensitivity and specificity of virtually 100%.¹⁹ In malignant gestational trophoblastic disease, which is highly

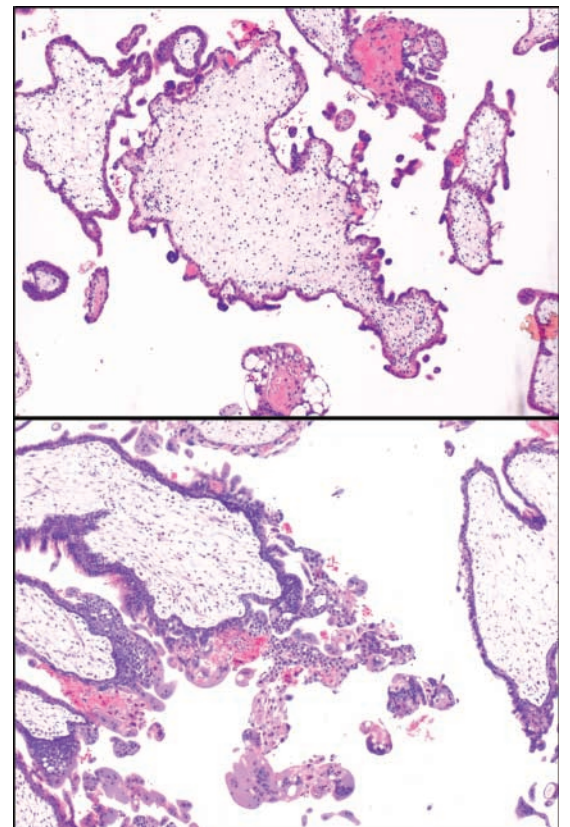


Fig 1 | Photomicrographs of a complete (top) and partial (bottom) hydatidiform mole, with characteristic abnormal hyperplasia of the trophoblast

Box 3 Pathology of hydatidiform mole

Diagnosis and subtyping of hydatidiform mole are usually based on histopathological examination of products of conception, with complete and partial forms having distinctive histological characteristics even in the first trimester. Both types show varying degrees of villous architectural abnormalities, with hydrops with abnormal circumferential villus trophoblast hyperplasia (fig 1). In some cases, definite diagnosis requires ancillary investigations such as immunostaining for the imprinted gene p57^{KIP2}, assessment of ploidy, or genetic microsatellite polymorphism analysis.

A PATIENT'S STORY

I became pregnant in August 2006 with what I thought would be my second child. All was well until nine weeks' gestation, when I started bleeding. A scan indicated that I was miscarrying. I went home to let nature take its course but nothing happened; a repeat scan showed that I had a molar pregnancy. I had a dilatation and curettage, but my human chorionic gonadotrophin concentrations increased. Despite two more dilatation and curettage procedures, the hormone concentration continued to rise, so I was admitted to Charing Cross Hospital on 20 December to start a course of low risk chemotherapy (see fig 2). The treatment lasted 13 weeks, and I spent only the first week in hospital. I didn't lose my hair or need antisickness tablets. Waiting for my hormone results to see if the treatment was working was hard, but the staff and other patients were very supportive. It helped to speak to people undergoing the same experience. I finished treatment in March 2007. It was only then that I thought about how things had gone so wrong. At times I felt broody and at other times I swore I would never want another baby. However, I am now 14 weeks pregnant and everything is going to plan.

Marie Gavin, Coventry

vascular, biopsy is contraindicated, because it may cause life threatening haemorrhage.

To ensure reliable monitoring of human chorionic gonadotrophin concentrations after a molar pregnancy, all patients in the UK are registered with one of three centres: Ninewells Hospital (Dundee), Weston Park Hospital (Sheffield), and Charing Cross Hospital (London). Most other countries have no centralised screening programme, but many have designated regional centres that manage gestational trophoblastic neoplasia. In the UK, the treating gynaecologist usually registers the patient, using paper or internet based registration. The patient and managing doctors are then sent an information pack and the referring hospital is asked to provide histological material for central pathological review. Patients then receive automated requests to submit samples for monitoring of human chorionic gonadotrophin. At Charing Cross Hospital, the hormone is measured in serum and urine

Table 2 | Chemotherapy regimen for low risk and intermediate risk patients with gestational trophoblastic disease²⁷

Drug	Dose
Methotrexate	50 mg intramuscularly; repeated every 48 h (total of 4 doses)
Calcium folinate (folinic acid)	15 mg orally 30 h after each injection of methotrexate

Courses repeated every two weeks—that is, days 1, 15, 29, etc.

then in urine only for several months once values are normal. If patients follow this protocol, the risk of missing treatable disease is about 1:2000 (box 5).¹⁹ Other centres in the world have advocated using shorter follow-up protocols, particularly for partial mole,²⁰ where the risk of malignancy is lower. This increases the risk of undetected malignant disease, however, and because such testing is cheap and prevents life threatening complications, we do not advocate shortening follow-up.

Molar disease may occasionally be reactivated after a subsequent pregnancy, even several years later, so hormone concentrations should be monitored at six and 10 weeks after any further pregnancy ends. Following a molar pregnancy, the risk of the next gestation being a hydatidiform mole rises to one in 80. Thus most women can expect to have a normal pregnancy.²¹

What factors increase the risk of malignant progression of hydatidiform mole?

Two studies, one of twin pregnancies comprising a mole and healthy co-twin and the other in singleton molar pregnancies, indicate that gestational timing of molar evacuation does not affect the risk of developing malignant disease.^{10,22} However, the method of evacuation may be important because procedures that induce uterine contractions could increase the risk of persistent disease and systemic spread. Evidence from retrospective series of patients in the UK suggests that the combined oral contraceptive pill may increase the risk of malignancy in a subset of women whose human chorionic gonadotrophin concentrations remain high.²³ UK centres therefore recommend women not to take the pill until their hormone concentrations have returned to normal,²³ although data from other countries suggest that the pill may be safe.²⁴

Who needs chemotherapy after hydatidiform mole?

Women with human chorionic gonadotrophin concentrations greater than 20 000 IU/l one month after

Table 1 | World Health Organization and International Federation of Gynecology and Obstetrics risk scoring system for gestational trophoblastic tumours and treatment protocols

Risk factor	Risk score			
	0	1	2	4
Age (years)	<40	≥40	—	—
Antecedent pregnancy	Mole	Abortion	Term	—
Interval (end of antecedent pregnancy to chemotherapy in months)	<4	4-6	7-13	>13
Human chorionic gonadotrophin (IU/l)	<10 ³	10 ³ to 10 ⁴	10 ⁴ to 10 ⁵	>10 ⁵
Number of metastases	0	1-4	5-8	>8
Site of metastases	Lung	Spleen, kidney	Gastrointestinal tract	Brain, liver
Largest tumour mass	—	3.5 cm	>5 cm	—
Previous chemotherapy	—	—	Single drug	≥2 drugs

The total score is obtained by adding the individual scores for each prognostic factor. Low risk 0-6; high risk ≥7.

Box 4 Clinical features of gestational trophoblastic disease

- Vaginal bleeding during early pregnancy
- Persistent vaginal bleeding after a miscarriage or pregnancy
- Any unusual clinical symptom in a woman of childbearing age
- Rarely, abnormally enlarged uterus, ovarian cysts, or hyperemesis

Box 5 UK (Charing Cross) protocol for surveillance after hydatidiform mole

Two weekly serum and urine samples until human chorionic gonadotrophin concentrations are normal

Then when hormone concentrations are normal:

If 56 or fewer days after evacuation, measure urine concentrations monthly for six months from evacuation date

If more than 56 days after evacuation, measure urine concentrations monthly for six months after values become normal

molar evacuation are at risk of uterine perforation, and chemotherapy is needed to help preserve fertility.²⁵ Persistently raised or rising hormone concentrations, with or without vaginal bleeding, indicate neoplasia (usually invasive mole or choriocarcinoma) (box 6). Severe bleeding is an indication for chemotherapy to reduce haemorrhage, even if the hormone concentration is falling.

What happens to patients referred for specialist treatment?

In the UK, treatment is provided at two specialist centres (Sheffield and London). Women are first assessed to estimate their risk of becoming resistant to single drug therapy with methotrexate (table 1). Risk is usually determined on the basis of history, examination, serum human chorionic gonadotrophin concentration, and the results of Doppler pelvic ultrasonography and chest radiography. About two thirds of women with low risk (score 0-6) disease will be cured with methotrexate alone, whereas women at high risk (score >7) require combination drug chemotherapy.²³ Most women in the UK have low risk disease,²⁶ because their gonadotrophin concentrations are monitored and malignancy is detected early and treated immediately (tables 2 and 3). Chemotherapy is

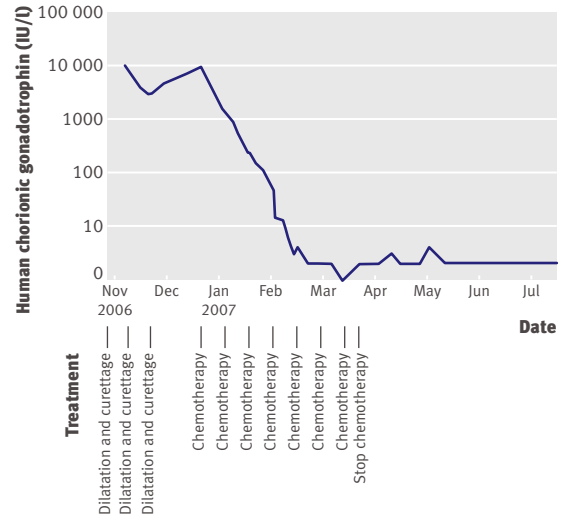


Fig 2 | Human chorionic gonadotrophin concentrations after evacuation of a molar pregnancy. Hormone concentrations are high as gestational trophoblastic neoplasia develops but drop as neoplasia is cured by chemotherapy with methotrexate and folinic acid

continued until hormone values have been normal (<5 IU/l on the Charing Cross assay) for six weeks. This regimen is well tolerated—only 2% of women have side effects such as mouth ulcers and sore eyes,²⁶ which are managed with mouthwashes and hypromellose eye-drops, and sometimes by increasing folinic acid. Patients are admitted for the first one to three weeks because of the potential risk of bleeding. Additional courses of treatment are usually given by a practice nurse, general practitioner, or local hospital.

Response to treatment is assessed by measuring serum concentrations of human chorionic gonadotrophin twice weekly. In a third of women, treatment is changed because of drug resistance or, occasionally, severe toxicity (mouth ulcers or serositis).²⁶ Women who develop methotrexate resistance at relatively low human chorionic gonadotrophin concentrations (<100

Table 3 | Chemotherapy regimen for high risk patients with gestational trophoblastic disease²⁷

Drugs	Dose
Regimen 1	
Day 1:	
Etoposide	100 mg/m ² by intravenous infusion over 30 min
Dactinomycin	0.5 mg intravenous bolus
Methotrexate	300 mg/m ² by intravenous infusion over 12 h
Day 2:	
Etoposide	100 mg/m ² by intravenous infusion over 30 min
Dactinomycin	0.5 mg intravenous bolus
Folinic acid rescue (starting 24 h after beginning the methotrexate infusion)	15 mg intramuscularly or orally every 12 h for 4 doses
Regimen 2	
Day 8:	
Vincristine	1 mg/m ² intravenous bolus (maximum 2 mg)
Cyclophosphamide	600 mg/m ² intravenous infusion over 30 min

The two regimens alternate each week.

Box 6 Indications for chemotherapy in gestational trophoblastic disease

- Histological evidence of choriocarcinoma
- Evidence of metastases in brain, liver, or gastrointestinal tract, or radiological opacities >2 cm on chest radiography
- Pulmonary, vulval, or vaginal metastases unless human chorionic gonadotrophin concentrations are falling
- Heavy vaginal bleeding or evidence of gastrointestinal or intraperitoneal haemorrhage
- Rising human chorionic gonadotrophin concentrations in two consecutive samples or plateaued concentrations in three consecutive samples after evacuation
- Serum human chorionic gonadotrophin greater than 20 000 IU/l more than four weeks after evacuation, because of the risk of uterine perforation
- Raised human chorionic gonadotrophin concentrations six months after evacuation, even if still falling

TIPS FOR NON-SPECIALISTS

Patients with persistent vaginal bleeding or any unusual symptom after miscarriage or delivery should be investigated for gestational trophoblastic disease

Products of conception from non-viable pregnancies and those suspected of molar disease should be submitted for routine histopathological evaluation

After diagnosis of a molar pregnancy, human chorionic gonadotrophin should be monitored—by a regional centre if possible—to ensure early detection of gestational trophoblastic neoplasia

Almost all cases of gestational trophoblastic neoplasia detected by screening are cured by chemotherapy with minimal morbidity

Human chorionic gonadotrophin should be measured in any woman of childbearing age presenting with unexplained tumours to exclude gestational trophoblastic neoplasia

ONGOING RESEARCH QUESTIONS

How can we predict—around the time of uterine evacuation—who will develop gestational trophoblastic neoplasia after a molar pregnancy?

What is the pathophysiological mechanism that leads to development of gestational trophoblastic neoplasia?

What is the minimum appropriate time period for human chorionic gonadotrophin surveillance after a molar pregnancy?

What are the optimal chemotherapeutic regimens for treating persistent gestational trophoblastic neoplasia across clinical settings?

IU/l and since 2005 increased to <300 IU/l) are usually cured with dactinomycin, which is slightly more toxic—causing hair loss, myelosuppression, mouth ulcers, and nausea.²⁶ The remaining resistant patients, and occasional patients not cured by dactinomycin, are salvaged with combination chemotherapy, albeit with a greater side effect profile (tables 2 and 3)²⁶; this treatment also hastens the menopause by about three years²⁸ and increases the risk of a second malignancy about 1.5-fold.²⁹ None of the treatments affects fertility, and the overall outlook is excellent—almost all women who develop neoplasia after a hydatidiform mole are cured. Indeed, no deaths occurred in a retrospective study of 485 patients who developed gestational trophoblastic neoplasia after a hydatidiform mole and who followed the above protocol.²⁶

Follow-up after chemotherapy

After treatment, human chorionic gonadotrophin is measured weekly for six weeks, two weekly for three months, and then with diminishing frequency until just six monthly urine samples are requested. In the UK, follow-up continues indefinitely because it is unclear when it is safe to stop, but the time varies in other countries. Of 1708 patients with gestational trophoblastic neoplasia at Charing Cross Hospital, including women presenting after non-molar pregnancies, the overall relapse rate was 3.5%, and most relapses occurred in the first year after treatment.³⁰ Women are therefore advised not to become pregnant for 12 months because this may interfere with early detection of relapsed disease.³¹

Are cases of hydatidiform mole missed in the UK and should we worry?

RCOG guidelines state that the usual medical management of miscarriage is not sufficient for suspected hydatidiform mole.^{15 32 33} Because tissue is not normally submitted for histological examination after miscarriage, suspected cases must be accurately preselected to minimise the risk of missing a diagnosis of hydatidiform mole, which may progress to gestational trophoblastic neoplasia. Women who present late with clinical gestational trophoblastic neoplasia have significantly more complications and morbidity, and they are more likely to need surgery and combination chemotherapy than women identified by human chorionic gonadotrophin surveillance.¹⁴ Because most hydatidiform moles present as non-viable pregnancies, pretermination ultrasonography should be used to identify non-viable conceptions that need histopathological evaluation. If pathological review is unavailable, human chorionic gonadotrophin should be measured three to four weeks after termination to identify women with persistently raised values who need to be followed up.¹⁴ In all miscarriages managed medically, if no tissue is available for pathological evaluation, human chorionic gonadotrophin should be measured—most cases of gestational trophoblastic neoplasia detectable by screening present with persistently raised human chorionic gonadotrophin concentrations.¹⁹

ADDITIONAL EDUCATIONAL RESOURCES**Educational resources for healthcare professionals**

Royal College of Obstetricians and Gynaecologists. *The management of early pregnancy loss*. Clinical guideline 25. 2006. www.rcog.org.uk/resources/Public/pdf/green_top_25_management_epl.pdf

Tidy JA, Hancock BW, Newlands ES. *The management of gestational trophoblastic neoplasia*. Clinical guideline 38. Royal College of Obstetricians and Gynaecologists. 2004. www.rcog.org.uk/resources/Public/pdf/Gestational_Troph_Neoplasia_No38.pdf

International Society for the Study of Trophoblastic Diseases (ISSTD) (www.isstd.org)—Links to a free copy of the ISSTD book on trophoblastic disease

Charing Cross Hospital Trophoblast Disease Service (www.hmole-chorio.org.uk/)—Information for health professionals and patients on molar pregnancies and gestational trophoblast disease

Educational resources for patients

Hydatidiform Mole and Choriocarcinoma UK Information and Support Service (www.hmole-chorio.org.uk/patients_info.html)—Information for patients with molar pregnancies or choriocarcinoma

Stirrat G. *Hydatidiform mole*. Wakefield: Miscarriage Association. 2004. www.miscarriageassociation.org.uk/ma2006/information/leaflets/hydamol.html

SUMMARY POINTS

Hydatidiform moles are non-viable genetically abnormal conceptions with excess expression of paternal genes and abnormal proliferation of the placental trophoblast

Women diagnosed with hydatidiform mole should be registered with a regional centre for regular monitoring of human chorionic gonadotrophin to check for onset of malignancy

Gestational trophoblastic neoplasia occurs in 10% of women with molar pregnancy

If neoplasia is recognised early it can be cured in nearly every case, often with methotrexate alone

How should gestational trophoblastic disease be screened for and treated in developing countries?

Many factors make the management of gestational trophoblastic disease in developing countries different, including variable access to health care, affordability of drugs, ease of follow-up, and cultural attitudes to health and disease. For these and other reasons it is difficult to be didactic about what will work best for a particular country. Where patients have good access to health care and can comply with surveillance programmes, a centralised system similar to the UK is feasible and effective. However, in rural settings where follow-up is difficult, it may be more appropriate to provide chemotherapy routinely after evacuation of hydatidiform mole, rather than measure serial hormone samples for weeks or months. If folinic acid is not available then methotrexate or dactinomycin can be given alone. No randomised controlled trials have been carried out, so the best regimen to use is unknown.³⁴

Contributors: Both authors searched the literature and contributed to reviewing and writing this review.

Competing interests: None declared.

Provenance and peer review: Commissioned; externally peer reviewed. Patient consent obtained.

- 1 Szulman AE, Surti U. The syndromes of hydatidiform mole. I. Cytogenetic and morphologic correlations. *Am J Obstet Gynecol* 1978;131:665-71.
- 2 Murdoch S, Djuric U, Mazhar B, Seoud M, Khan R, Kuick R, et al. Mutations in NALP7 cause recurrent hydatidiform moles and reproductive wastage in humans. *Nat Genet* 2006;38:300-2.
- 3 Fisher RA, Khatoun R, Paradinas FJ, Roberts AP, Newlands ES. Repetitive complete hydatidiform mole can be biparental in origin and either male or female. *Hum Reprod* 2000;15:594-8.
- 4 Sebire NJ, Fisher RA, Rees HC. Histopathological diagnosis of partial and complete hydatidiform mole in the first trimester of pregnancy. *Pediatr Dev Pathol* 2003;6:69-77.
- 5 Sebire NJ, Rees H. Diagnosis of gestational trophoblastic disease in early pregnancy. *Curr Diagn Pathol* 2003;8:430-40.
- 6 Castrillon DH, Sun D, Weremowicz S, Fisher RA, Crum CP, Genest DR. Discrimination of complete hydatidiform mole from its mimics by immunohistochemistry of the paternally imprinted gene product p57^{kip2}. *Am J Surg Pathol* 2001;25:1225-30.
- 7 Fisher RA, Newlands ES. Gestational trophoblastic disease. Molecular and genetic studies. *J Reprod Med* 1998;43:87-97.
- 8 Sebire NJ, Foscett M, Fisher RA, Rees H, Seckl M, Newlands E. Risk of partial and complete hydatidiform molar pregnancy in relation to maternal age. *Br J Obstet Gynaecol* 2002;109:99-102.
- 9 Smith HO, Kim SJ. Epidemiology. In: Hancock BW, Newlands ES, Berkowitz RS, Cole LA, eds. *Gestational trophoblastic disease*. 2nd ed. 2003:39-76. www.isstd.org/gtd/contents.html.
- 10 Sebire NJ, Foscett M, Paradinas FJ, Fisher RA, Francis RJ, Short D, et al. Outcome of twin pregnancies with complete hydatidiform mole and healthy co-twin. *Lancet* 2002;359:2165-6.
- 11 Gemer O, Segal S, Kopmar A, Sassoon E. The current clinical presentation of complete molar pregnancy. *Arch Gynecol Obstet* 2000;264:33-4.
- 12 Fowler DJ, Lindsay I, Seckl MJ, Sebire NJ. Routine pre-evacuation ultrasound diagnosis of hydatidiform mole: experience of 1000

- cases from a regional referral centre. *Ultrasound Obstet Gynecol* 2006;27:56-60.
- 13 Johns JN, Greenwold S, Buckley E, Jauniaux E. A prospective study of ultrasound screening for molar pregnancies in missed miscarriages. *Ultrasound Obstet Gynecol* 2005;25:493-7.
- 14 Seckl MJ, Gillmore R, Foscett M, Sebire NJ, Rees H, Newlands ES. Routine terminations of pregnancy—should we screen for gestational trophoblastic neoplasia? *Lancet* 2004;364:705-7.
- 15 Tidy JA, Hancock BW, Newlands ES. *The management of gestational trophoblastic neoplasia*. Clinical guideline 38. London: Royal College of Obstetricians and Gynaecologists. 2004. www.rcog.org.uk/resources/Public/pdf/Gestational_Troph_Neoplasia_No38.pdf.
- 16 Savage P, Seckl MJ. The role of repeat uterine evacuation in trophoblast disease. *Gynecol Oncol* 2005;99:251-2.
- 17 Seckl MJ, Fisher RA, Salerno G, Rees H, Paradinas FJ, Foscett M, et al. Choriocarcinoma and partial hydatidiform moles. *Lancet* 2000;356:36-9.
- 18 Mitchell H, Seckl MJ. Discrepancies between commercially available immunoassays in the detection of tumour-derived hCG. *Mol Cell Endocrinol* 2007;262:310-3.
- 19 Sebire NJ, Foscett M, Short D, Savage P, Stewart W, Thomson M, et al. Shortened duration of human chorionic gonadotrophin surveillance following complete or partial hydatidiform mole: evidence for revised protocol of a UK regional trophoblastic disease unit. *Br J Obstet Gynaecol* 2007;114:760-2.
- 20 Wielsma S, Kermeijer L, Bekkers R, Pyman J, Tan J, Quinn M. Persistent trophoblast disease following partial molar pregnancy. *Aust N Z J Obstet Gynaecol* 2006;46:119-21.
- 21 Sebire NJ, Fisher RA, Foscett M, Rees H, Seckl MJ, Newlands ES. Risk of recurrent hydatidiform mole and subsequent pregnancy outcome following complete or partial hydatidiform molar pregnancy. *Br J Obstet Gynaecol* 2003;110:22-6.
- 22 Seckl MJ, Dhillon T, Dancy G, Foscett M, Paradinas FJ, Rees HC, et al. Increased gestational age at evacuation of a complete hydatidiform mole: does it correlate with increased risk of requiring chemotherapy? *J Reprod Med* 2004;49:527-30.
- 23 Stone M, Dent J, Kardana A, Bagshawe KD. Relationship of oral contraception to development of trophoblastic tumour after evacuation of a hydatidiform mole. *Br J Obstet Gynaecol* 1976;83:913-6.
- 24 Costa HL, Doyle P. Influence of oral contraceptives in the development of post-molar trophoblastic neoplasia: a systematic review. *Gynecol Oncol* 2006;100:579-85.
- 25 Seckl MJ, Newlands ES. Presentation and management of persistent gestational trophoblastic disease (GTD) and gestational trophoblastic tumours/neoplasia in the United Kingdom. In: Hancock BW, Seckl MJ, Berkowitz RS, Cole LA, eds. *Gestational trophoblastic disease*. 3rd ed (in press).
- 26 McNeish IA, Strickland S, Holden L, Rustin GJ, Foscett M, Seckl MJ, et al. Low-risk persistent gestational trophoblastic disease: outcome after initial treatment with low-dose methotrexate and folinic acid from 1992 to 2000. *J Clin Oncol* 2002;20:1838-44.
- 27 Ngan H, Wong LC, Ma HK. Staging and classification systems. In: Hancock BW, Newlands ES, Berkowitz RS, Cole LA, eds. *Gestational trophoblastic disease*. 2nd ed. 2003:156-74. www.isstd.org/gtd/contents.html.
- 28 Bower M, Rustin GJ, Newlands ES, Holden L, Short D, Foscett M, et al. Chemotherapy for gestational trophoblastic tumours hastens menopause by 3 years. *Eur J Cancer* 1998;34:1204-7.
- 29 Rustin GJ, Newlands ES, Lutz JM, Holden L, Bagshawe KD, Hiscox JG, et al. Combination but not single-agent methotrexate chemotherapy for gestational trophoblastic tumors increases the incidence of second tumors. *J Clin Oncol* 1996;14:2769-73.
- 30 Powles T, Savage PM, Stebbing J, Short D, Young A, Bower M, et al. A comparison of patients with relapsed and chemo-refractory gestational trophoblastic neoplasia. *Br J Cancer* 2007;96:732-7.
- 31 Blagden SP, Foscett MA, Fisher RA, Short D, Fuller S, Newlands ES, et al. The effect of early pregnancy following chemotherapy on disease relapse and foetal outcome in women treated for gestational trophoblastic tumours. *Br J Cancer* 2002;86:26-30.
- 32 Royal College of Obstetricians and Gynaecologists. *The management of early pregnancy loss*. Clinical guideline 25. 2000. www.rcog.org.uk/resources/Public/pdf/green_top_25_management_epl.pdf.
- 33 Tidy JA, Gillespie AM, Bright N, Radstone CR, Coleman RE, Hancock BW. Gestational trophoblastic disease: a study of mode of evacuation and subsequent need for treatment with chemotherapy. *Gynecol Oncol* 2000;78:309-12.
- 34 Foulmann K, Guastalla JP, Caminet N, Trillet-Lenoir V, Raudrant D, Golfier F, et al. What is the best protocol of single-agent methotrexate chemotherapy in nonmetastatic or low-risk metastatic gestational trophoblastic tumors? A review of the evidence. *Gynecol Oncol* 2006;102:103-10.