

PAEDIATRIC PROBLEMS—II

Caroline M Doig

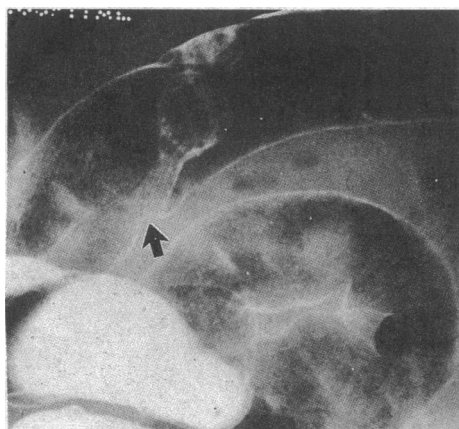
Rectal bleeding

Bright red bleeding through the anus usually indicates one of the following:

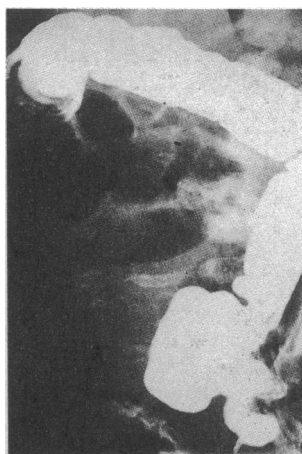
- Anal fissure
- Rectal polyp
- Dysentery
- Inflammatory bowel disease

Polyps

Painless bleeding suggests a solitary rectal polyp. These are almost always not adenomatous. The bleeding, separate from the stool and of moderate quantity, necessitates sigmoidoscopy and snaring of the polyp. Such polyps should be sent for histological examination to check that they are not premalignant. Multiple polyps elsewhere in the colon may require either flexible sigmoidoscopy or colonoscopy to make the diagnosis, to take a biopsy specimen, and for treatment. Contrast barium enema examination can help to pin point the area. If the polyps are adenomatous follow up with repeated endoscopy is necessary. Polyposis coli can occur in children under the age of 15 years, so follow up and treatment, even colectomy, may be necessary early.



Contrast barium enema radiograph showing stalked polyp (arrowed) and more sessile polyp opposite.



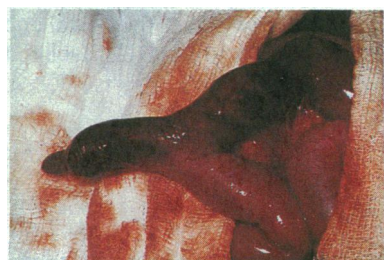Barium enema radiograph showing intussusception in right transverse colon.

Intussusception

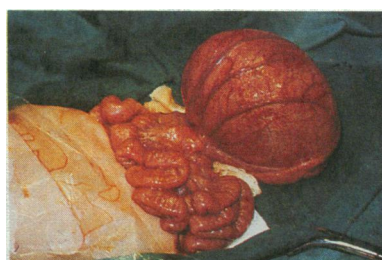Intussusception occurs most commonly in infants 7-12 months old. In older children there is usually an associated polyp, diverticulum, or tumour. Although classically the diagnosis is made on the basis of colicky abdominal pain, a sausage shaped mass, and dark red blood through the rectum, 10% present with diarrhoea and vomiting suggestive of gastroenteritis. Bleeding through the rectum indicates that the bowel is compromised and occurs in about a half of patients.

If the child is not in shock, which is often the case, barium or air enema examination may not only confirm the diagnosis but also treat the intussusception as the hydrostatic pressure can reduce the bowel. More often surgery may have to be performed after resuscitation. If resection of the bowel is necessary the ileocaecal valve and terminal ileum may be lost.

Meckel's diverticulum may present with bleeding because of an intussusception or because of the presence of gastric mucosa.



Meckel's diverticulum which has been involved in an intussusception.

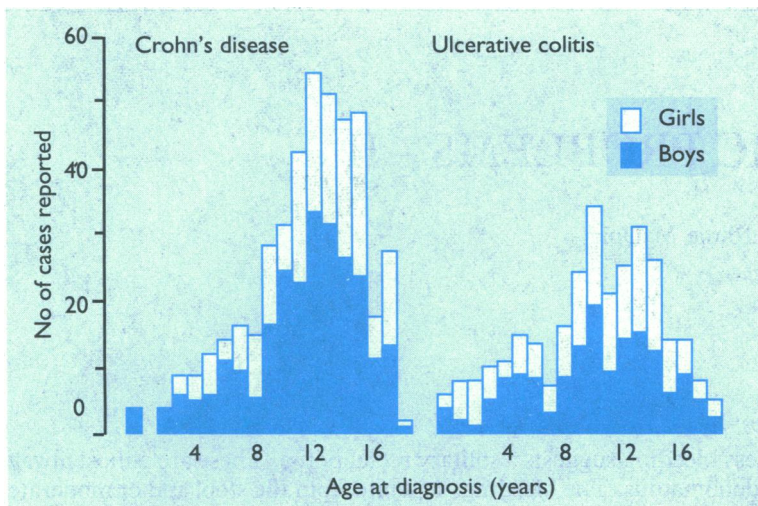


Duplication cyst of small bowel with flattened bowel.

Duplication cyst

Any part of the gastrointestinal tract may be duplicated; the colon is the part least commonly duplicated. The diagnosis is made by using ultrasonography and radiography to show displacement of the bowel. Spinal abnormalities—for example, hemivertebrae can be associated, though not necessarily at the level of the abnormality. When a duplication cyst occurs in a short portion of bowel it is usually possible to excise both the cyst and the segment of bowel affected, with reanastomosis of the colon.

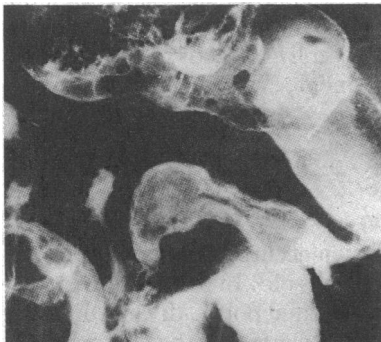
Inflammatory bowel disease



Age at diagnosis of Crohn's disease and ulcerative colitis.¹

Inflammatory bowel disease does occur in childhood. The number of children under the age of 12 years with Crohn's disease is increasing.

The presentation, diagnosis, and treatment of ulcerative colitis and Crohn's disease in children are similar to those in adults. Children may present with extragastrointestinal problems, such as arthritis, skin rashes, and uveitis, many months or years before abdominal pain, weight loss, and mouth ulcers make the diagnosis of Crohn's disease obvious. In addition to endoscopy and biopsy diagnosis has been improved by the use of small bowel enemas and scintigraphy scans to pinpoint active areas.



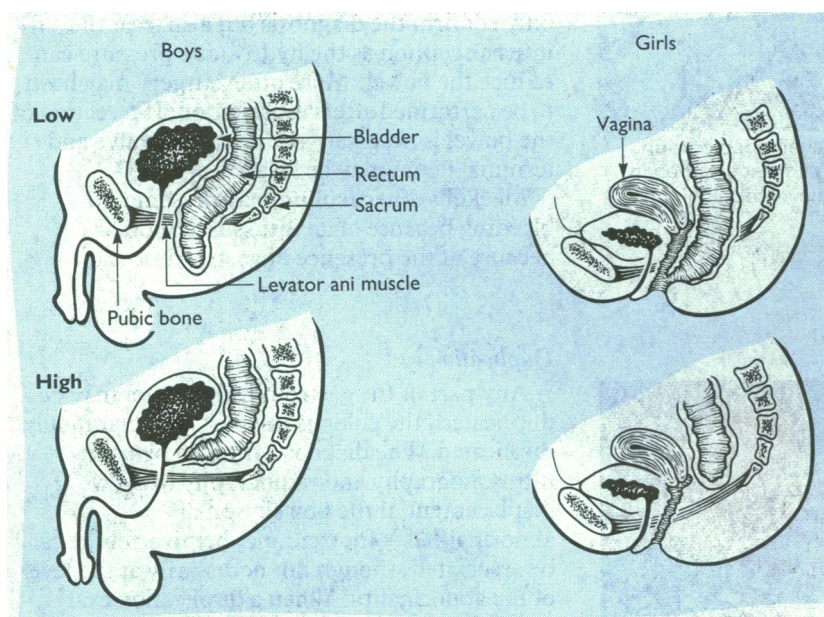
Small bowel barium enema radiograph in a child with Crohn's disease showing narrowed ileum just proximal to ileocaecal valve.

Number of children in Britain with inflammatory bowel disease¹

• Crohn's disease	447
• Ulcerative colitis	305
• Other inflammatory bowel disease	34

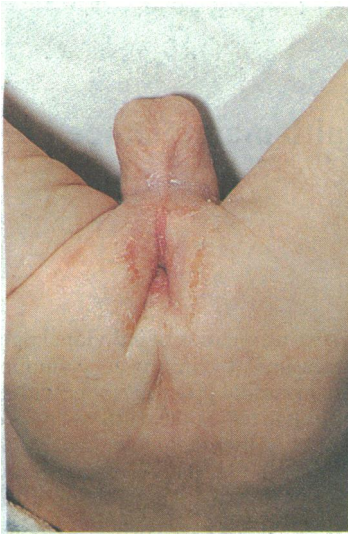Surgery for Crohn's disease in children, when performed early because of stunting of growth and failure of sexual development, has tended to give fewer immediate postoperative problems than in adults and may lead to a growth spurt, though the risk of recurrence is high.

Anorectal anomalies

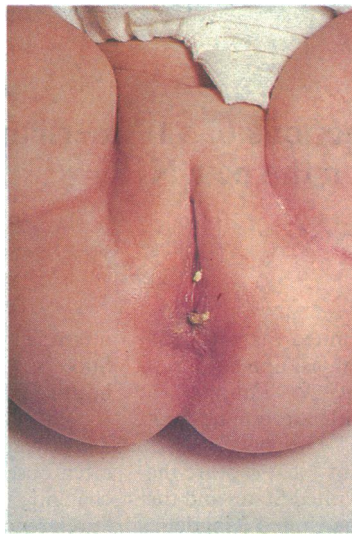

Common anorectal anomalies (a) in boys and (b) in girls showing relation in high and low anorectal abnormalities between bowel, levator ani muscle, skin, urethra, and vagina.

Anorectal anomalies are congenital abnormalities of either the anus or rectum, or both. The anus can be absent, abnormal, or ectopic. There are many different types of anomaly, which may or may not involve fistulous connections to skin, vagina, or urethra. The main distinction, however, is whether the bowel ends above or below the levator ani muscle. Isolated colonic atresia may also occur.

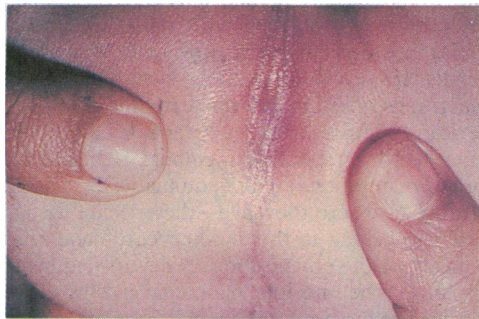


Male infant perineum with pin hole anus showing excoriation due to passage of "toothpaste stools" as a result of delayed diagnosis.



Female perineum showing anterior placed anus just inside the forchette.

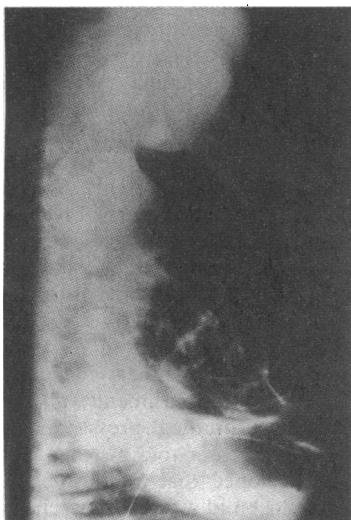The low type of anomaly includes those in which the bowel passes through a normal levator ani muscle to end blindly a few centimetres from the anus (imperforate anus) or enters the perineum in an abnormal position. The diagnosis is made by careful inspection of the perineum for a fistulous connection to skin on the penile shaft or median raphe of the scrotum in a boy or just within the vestibule in a girl. Treatment usually involves the derroofing of such a fistula by cutting back to a normal anus. Long term continence is ensured if the sphincter muscles are normal. Occasionally an anoplasty to place an ectopic anus in a normal position may be necessary. Early inspection of the perineum in babies to pick up an ectopic or stenotic anal opening improves long term outlook.



Perineum with no anus or fistula—probable high type anomaly.

It is important that the high type of anorectal anomaly is not misdiagnosed as a low imperforate anus. In these children the bowel ends above the levator ani, which is often poorly developed. The distinction can be made by inspection and lateral inverted radiography performed 24 hours after birth to find out where the intestinal gas ends. Should gas appear not to reach the pubococcygeal line, a high type of anomaly is probable and perineal exploration should not be done.

Treatment entails performing a colostomy with subsequent "pull through" of the colon through the pelvic muscles and involving the sphincter muscles present to the perineum. It has been suggested that the earlier such reconstruction surgery is carried out the more likely the child will develop normal continence. Various operations have been developed that use abdominal, sacral, and perineal approaches to reconstitute the anatomy. The most recent, a posterior approach dividing the muscles and tapering the colon before bringing it on to the perineum, has had promising early results.



Inverted lateral radiograph showing intestinal gas just at level of coccyx-pubis line (high type anomaly).

As a result of poor or absent musculature children with high anomalies may be slow to gain continence, but by strenuous training to use such muscles as are present, tightening the muscles later by levatorplasty, giving advice about diet, and keeping the "neorectum" empty, improvement may occur. More than a half of children with any type of anorectal anomaly will have at least one other abnormality. In view of the high incidence of renal problems all of these children should have their urinary tract examined at an early age.

The photographs were prepared by the medical illustration department, North Manchester General Hospital.

Miss Caroline M Doig is senior lecturer in paediatric surgery, Booth Hall Children's Hospital, University of Manchester.

The ABC of Colorectal Diseases has been edited by Mr D J Jones, lecturer and honorary senior registrar, and Professor M H Irving, department of general surgery, Hope Hospital, Salford.

1 Ferguson A, Rifkind E, Doig CM. Prevalence of chronic inflammatory bowel disease in British children. In: *Frontiers of gastrointestinal research*. Vol 11. Basle: Karger, 1986:68-72.

Anomalies associated with colorectal problems in children

- | | |
|-----------------------------------|--------|
| • Congenital heart disease | 12-20% |
| • Skeletal problems | 15-20% |
| • Tetralogy of fallot and atresia | 5-10% |
| • Other intestinal problems | 5% |
| • Urological problems | 30-50% |