



Congenital Zika syndrome with arthrogryposis: retrospective case series study

Vanessa van der Linden,^{1,2} Epitacio Leite Rolim Filho,^{1,3} Otavio Gomes Lins,³ Ana van der Linden,⁴ Maria de Fátima Viana Vasco Aragão,^{5,6} Alessandra Mertens Brainer-Lima,^{6,7} Danielle Di Cavalcanti Sousa Cruz,⁴ Maria Angela Wanderley Rocha,⁸ Paula Fabiana Sobral da Silva,⁸ Maria Durce Costa Gomes Carvalho,⁸ Fernando José do Amaral,² Joelma Arruda Gomes,² Igor Colaço Ribeiro de Medeiros,⁹ Camila V Ventura,^{10,11} Regina Coeli Ramos⁸

¹Association for Assistance of Disabled Children, AACD, Recife, Brazil

²Barão de Lucena Hospital, HBL, Recife, Brazil

³Federal University of Pernambuco, UFPE, Recife, Brazil

⁴Prof Fernando Figueira Integral Medicine Institute, IMIP, Recife, Brazil

⁵Centro Diagnóstico Multimagem, Recife, Brazil

⁶Maurício de Nassau University, Recife, Brazil

⁷University of Pernambuco, UPE, Recife, Brazil

⁸Oswaldo Cruz University Hospital, HUOC, Recife, Brazil

⁹Hospital Infantil Jorge de Medeiros Recife, Brazil

¹⁰Altino Ventura Foundation, FAV, Recife, Brazil

¹¹Pernambuco's Eye Hospital, Recife, Brazil

Correspondence to: V van der Linden vanessavdlinden@hotmail.com

Cite this as: *BMJ* 2016;354:i3899 <http://dx.doi.org/10.1136/bmj.i3899>

Accepted: 05 July 2016

ABSTRACT

OBJECTIVE

To describe the clinical, radiological, and electromyographic features in a series of children with joint contractures (arthrogryposis) associated with congenital infection presumably caused by Zika virus.

DESIGN

Retrospective case series study.

SETTING

Association for Assistance of Disabled Children, Pernambuco state, Brazil.

PARTICIPANTS

Seven children with arthrogryposis and a diagnosis of congenital infection presumably caused by Zika virus during the Brazilian microcephaly epidemic.

MAIN OUTCOME MEASURES

Main clinical, radiological, and electromyographic findings, and likely correlation between clinical and primary neurological abnormalities.

RESULTS

The brain images of all seven children were characteristic of congenital infection and arthrogryposis. Two children tested positive for IgM to Zika virus in the cerebrospinal fluid. Arthrogryposis was present in the arms and legs of six children (86%) and the legs of one child (14%). Hip radiographs showed bilateral dislocation in seven children, subluxation of the knee associated with genu valgus in three children (43%), which was bilateral in two (29%). All the children underwent high definition ultrasonography of the joints, and there was no

evidence of abnormalities. Moderate signs of remodeling of the motor units and a reduced recruitment pattern were found on needle electromyography (monopolar). Five of the children underwent brain computed tomography (CT) and magnetic resonance imaging (MRI) and the remaining two CT only. All presented malformations of cortical development, calcifications predominantly in the cortex and subcortical white matter (especially in the junction between the cortex and white matter), reduction in brain volume, ventriculomegaly, and hypoplasia of the brainstem and cerebellum. MRI of the spine in four children showed apparent thinning of the cord and reduced ventral roots.

CONCLUSIONS

Congenital Zika syndrome should be added to the differential diagnosis of congenital infections and arthrogryposis. The arthrogryposis was unrelated to the abnormalities of the joints themselves, but was possibly of neurogenic origin, with chronic involvement of central and peripheral motor neurones leading to deformities as a result of fixed postures in utero. Based on the neurophysiological observations, we suggest two possible mechanisms: tropism of neurones, with involvement of peripheral and central motor neurones, or a relation with vascular disorders.

Introduction

Epidemiological data suggested that cases of microcephaly in Brazil might be associated with the introduction of the Zika virus.¹ One study detected Zika virus genome and anti-Zika virus IgM in the amniotic fluid of pregnant women with microcephalic fetuses.² An autopsy study described the complete recovery of the Zika virus genome from a fetus's brain.³ In April 2016, the US Centers for Disease Control and Prevention concluded that there is a causal relation between prenatal Zika virus infection and microcephaly and other serious brain anomalies.⁴

Brain impairment in the presence of microcephaly is the main characteristic of a congenital Zika virus syndrome. However, little is still known about this condition and its clinical spectrum, which also concerns newborns with a normal head circumference. Two studies have described the association between arthrogryposis and microcephaly in newborns presumed to have congenital Zika virus infection.^{5,6}

Arthrogryposis multiplex congenita is characterised by joint contractures at birth,⁷ which can be divided

WHAT IS ALREADY KNOWN ON THIS TOPIC

Until recently there were no reports of an association between congenital viral infection and arthrogryposis

After the outbreak of microcephaly in Brazil associated with Zika virus, two reports appeared suggesting an association, but they did not describe the deformities in detail

WHAT THIS STUDY ADDS

This case series provides detailed information about the clinical, imaging, and electromyographic findings in babies with arthrogryposis associated with congenital Zika virus infection

Tests to evaluate arthrogryposis were consistent with a neurogenic pattern, with electromyographic findings and spinal magnetic resonance imaging suggesting involvement of the lower motor neurones

The pathophysiology of this condition might be related to the tropism of the virus by the upper and lower motor neurons, or to embryonic vascular change affecting these two segments

into isolated and multiple contractures. Isolated contractures affect only one area of the body, most commonly the foot. The term arthrogryposis is often used as shorthand to describe multiple congenital contractures affecting two or more areas of the body.⁸ Thus, arthrogryposis might be considered more a sign than a specific disease, and it might be associated with several disorders. However, there are no reports in the literature about other congenital infections in humans associated with arthrogryposis.^{9 10}

We describe the clinical, radiological, and electromyographic findings in a series of seven children with arthrogryposis associated with congenital infection presumably caused by Zika virus and try to establish a likely correlation between the clinical and primary neurological abnormalities found.

Methods

We conducted a descriptive, retrospective study by reviewing the medical records of children with arthrogryposis associated with congenital infection presumably caused by Zika virus, during the Brazilian microcephaly epidemic. The children were seen at the rehabilitation centre of the Association for Assistance of Disabled Children (AACD) in Pernambuco, Brazil, which follows up patients with congenital Zika virus infection. Two children were treated by the AACD team in the intensive care unit of other hospitals.

According to the Brazilian Department of Health's protocol, all children with suspected microcephaly are referred to one of two paediatric infectious disease departments and to one of four rehabilitation centres. All investigations described were conducted as part of the clinical protocol or clinical indication; none was conducted for research reasons and therefore neither ethical approval nor informed consent was necessary (other than for the use of photographs in this paper). The first criterion for referral was a head circumference of less than 33 cm; from 2 December the criterion was changed to 32 cm for gestational age 37 weeks or more and two standard deviations below the mean for age and sex in the Fenton curve for preterm babies.

In this series we describe seven patients with a diagnosis of congenital infection presumably caused by Zika virus who had arthrogryposis and met the inclusion criteria of brain imaging suggestive of congenital infection; a negative test result for the five other main infectious causes of microcephaly—toxoplasmosis, cytomegalovirus, rubella, syphilis, and HIV; and presence of arthrogryposis, defined as congenital contractures affecting two or more areas of the body.

A standard form was used to collect personal and clinical data, including maternal reports of a rash during pregnancy.

Cytomegalovirus, toxoplasmosis, rubella, syphilis, and HIV are the main causes of congenital infections that result in brain calcifications and microcephaly. We tested for these viruses using paired serology (IgM and IgG) of both the mother and the newborn. If cytomegalovirus IgG was present in both samples, we carried out polymerase chain reaction on urine specimens.

We excluded patients with known causes of microcephaly other than the Zika virus.

IgM antibody capture enzyme-linked immunosorbent assay was used to test for Zika virus in the cerebrospinal fluid samples of two children, following the CDC protocol.¹¹

Microcephaly is an important sign; however, it is not present in all cases of congenital Zika virus infection. The Fetal International and Newborn Growth Consortium for the 21st Century (Intergrowth-21st) defines microcephaly as a head circumference two standard deviations below the mean for gestational age and sex and severe microcephaly as three standard deviations below this mean.^{12 13} We also used the Intergrowth-21st curve to evaluate birth weight, classified as appropriate, small, or large for gestational age and sex.¹³

All the children underwent neurological and orthopaedic examinations along with several other investigations: radiography, brain computed tomography (CT) or brain magnetic resonance imaging (MRI) without contrast, high definition ultrasonography of the joints (with specific attention to cartilage, synovia, pericapsular structures, and muscular tissue around joints), nerve conduction studies, and needle electromyography. If calcifications were present on brain imaging (CT or MRI), we considered the possibility of congenital infections.

Four children underwent MRI of the spine. MRI was not possible in two children as they were receiving mechanical ventilation on an intensive unit care.

According to Pernambuco state's protocol for microcephaly, all seven children underwent fundoscopic assessment, and six also underwent hearing screening by otoacoustic emissions or brainstem evoked potentials.

One of the children underwent orthopaedic surgery for correction of foot and hip deformities. Assessment of range of motion was carried out under anaesthesia and the muscles evaluated macroscopically.

Patient involvement

No patients were involved in setting the research question or the outcome measures, nor were they involved in developing plans for design or implementation of the study. No patients were asked to advise on interpretation or writing up of results. There are no plans to disseminate the results of the research to study participants or the relevant patient community.

Results

At the time of writing, March 2016, 104 children were under evaluation at AACD for congenital infection presumably caused by Zika virus. Seven (7%) met the inclusion criteria (brain imaging suggestive of congenital infection, a negative test result for congenital infections, and presence of arthrogryposis), two of whom were girls (29%). Two of the seven children tested positive for IgM for Zika virus in the cerebrospinal fluid. All seven children met the protocol criteria for congenital infection presumably caused by Zika virus, even without being tested for IgM for Zika virus, which is not yet available on a routine basis.

Table 1 | Characteristics of the children

Patient No	Sex	Zika IgM status	Birth weight for GA	Maternal rash during pregnancy	Head circumference at birth	Microcephalus	Craniofacial disproportion	Redundant scalp skin
1	Boy	Positive	Appropriate	2nd month	33 cm	No	No	No
2	Girl	Positive	Small	2nd month	30 cm	2 SD*	Yes	No
3	Boy	Not done	Small	3rd month	27 cm	3 SD*	Yes	Yes
4	Girl	Not done	Appropriate	No	29 cm	2 SD*	Yes	No
5	Boy	Not done	Appropriate	No	30 cm	3 SD*	Yes	No
6	Boy	Not done	Small	No	27 cm	3 SD*	Yes	Yes
7	Boy	Not done	Small	4th month	26 cm	3 SD*	Yes	Yes

GA=gestational age.

*Standard deviations below mean for age and sex.

Table 1 summarises the characteristics of the children. All were born at term in Pernambuco state, Brazil during October to November 2015. Four mothers (57%) described having a rash between the second and fourth gestational months. The head circumference was in the normal range in one child (14%), two standard deviations below the mean for gestational age and sex in two (29%), and three standard deviations below this mean for gestational age and sex in four (57%). Three of the children (43%) were of appropriate birth weight for gestational age and four (57.1%) were small for gestational age. Six of the seven (86%) children showed evidence of craniofacial disproportion; three (43%) had redundant skin on the scalp at birth. Dysphagia was present in six children (86%); two underwent gastrostomy and tracheostomy. All five boys had cryptorchidism, which was unilateral in one child.

Arthrogryposis was present in both the arms and the legs of six children (86%) and in the legs of one child (14%). Several leg deformities were observed: congenital clubfoot in six children (86%), which was bilateral in three (43%); knee flexion contracture in five children (71%), which was bilateral in three (43%) and unilateral in two (29%); hyperextension associated with subluxation of the knee in three children (43%), which was bilateral in two (29%); and contractures of hip flexion, adduction, and external rotation associated with irreducible bilateral dislocation that is not reducible to manoeuvre of Ortolani in all seven children. In all seven children, spinal deformities were not identified in either the sagittal or the coronal plane on plain radiography. The chest was barrel-like in four children (57%). Deformities identified in the arms were camptodactyly in six children (86%), which was bilateral in five (71.4%), and deformations of flexion in the second to fifth chirodactylus in all seven children. Adduction of the thumb was present in five children (71%), abduction of the thumb in two (29%), a bilateral simian crease in one (14%); deformities in hyperextension of the elbow in four (57%); flexion contracture in two (29%), which was bilateral; and decreased range of motion of the shoulder with contracture in adduction and internal rotation in two (29%). Figure 1 shows the clinical pictures of children with arthrogryposis.

None of the children had deformities or limitation of motion of the cervical spine.

Other findings were ligamentous laxity in one child (14%) and skin haemangioma in four children (57%)—one frontal, three occipital, and one on the left parathoracic region.

Hip radiographs showed bilateral dislocation in seven children, subluxation of the knee associated with genu valgus in three children (43%), bilateral in two (29%). In all the children, no dysplastic changes were identified on simple radiographs of the appendicular skeleton and spine and none were identified in either the sagittal or coronal plane; dysplastic changes were identified in the dislocated hips, related to dysplastic acetabular (acetabular index >30 degrees). Table 2 shows the main deformities most often found in the children, and figure 2 shows some radiological features.

All seven children underwent high definition ultrasonography of the joints, with specific attention to cartilage, synovia, pericapsular structures, and muscular tissue around the joints. There was no evidence of joint abnormalities.

Nerve conduction studies and needle electromyography was performed in all seven children. Nerves studied were median and ulnar (sensory and motor conduction studies), tibial and fibular (motor conduction studies), and medial plantar (sensory conduction

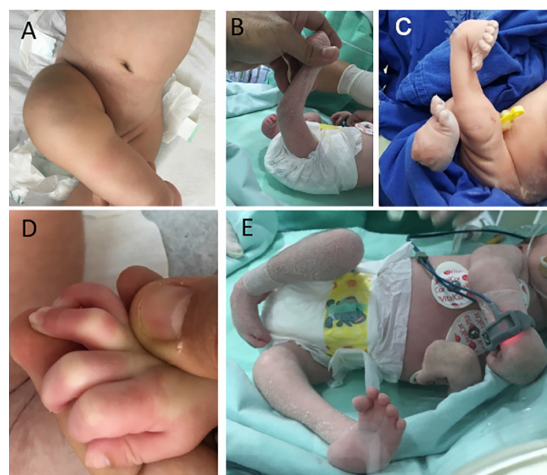

Fig 1 | (A) Contracture in flexion of knee; (B) hyperextension of knee (knee dislocation); (C) clubfeet; (D) deformities in 2nd, 3rd, and 4th fingers; (E) joint contractures in legs and arms, without involvement of trunk

Table 2 | Main orthopaedic abnormalities

Abnormalities	No (%) of patients		No (%) of total population (n=7)
	Unilateral	Bilateral	
Clubfoot	3 (50)	3 (50)	6 (86)
Dislocation or subdislocation of knee	1 (33)	2 (67)	3 (43)
Contracture in flexion of knees	2 (40)	3 (60)	5 (71.4)
Dislocation of hips	—	7 (100)	7 (100)
Contracture in flexion of wrist and fingers	1 (17)	5 (83)	6 (86)
Camptodactyly (hands)	1 (17)	5 (83)	6 (86)
Adducted thumb	—	5 (100)	5 (71)
Flexion contracture in elbow	—	2 (100)	2 (29)
Extension contracture in elbow	2 (50)	2 (50)	4 (57)
Contracture in adduction and internal rotation of shoulders	—	2 (100)	2 (29)

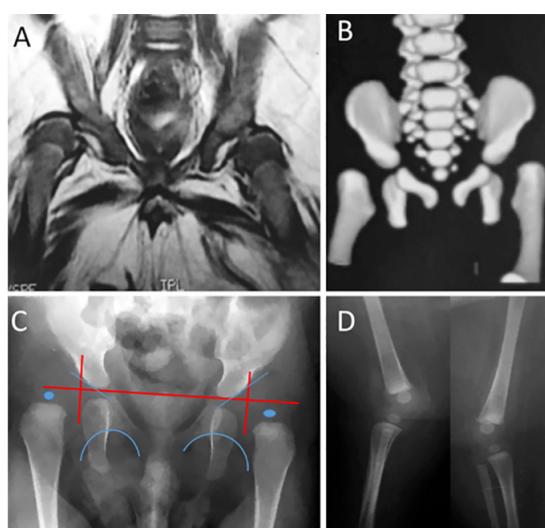


Fig 2 | (A) Magnetic resonance image showing bilateral dislocation of hips, epiphyseal core (small arrow), and dysplastic acetabulum (large arrow); **(B)** 3D computed tomogram showing bilateral dislocation of hips; **(C)** anteroposterior radiographs showing features compatible with dislocation of hips: interruption of Shenton's arc, epiphysis hypoplastic proximal femoral acetabular index of 35 degrees, and right and left proximal femoral epiphysis located laterally on side and bottom quadrant ombredanne; **(D)** radiograph shows subluxation of knee (arrows)

studies). Muscles studied were biceps brachii, extensor digitorum communis, tibialis anterior, and medial gastrocnemius. Not all of these nerves and muscles were studied in all the children. The procedures are technically challenging owing to the presence of anatomical abnormalities and the irritability typical of babies. Table 3 summarises the results of electromyography.

Sensory nerve action potentials of all the children were of normal amplitudes and conduction velocities for age. The sensory nerve action potentials of the medial plantar nerve could not be obtained in one child, possibly because of technical reasons previously described. Compound motor action potentials could be obtained in all the children, most were of moderately low amplitudes and normal distal motor latencies and conduction velocities.

Needle electromyography (monopolar) showed moderate signs of remodeling of the motor units (polyphasic motor unit potentials with increased amplitude and duration) and a reduced recruitment pattern. The children with severe weakness of carpal and finger extension or ankle dorsiflexion also showed reduced activation of motor units.

Five of the children underwent brain CT and MRI and two CT only. All presented malformation of cortical development, calcifications predominantly in the cortex and subcortical white matter (especially in the junction between the cortex and white matter), reduction in brain volume, ventriculomegaly, and hypoplasia of the brainstem and cerebellum. Table 4 summarises the main findings on brain imaging.

In four of the children, spinal MRI showed apparent cord thinning and reduced ventral roots. Figure 3 shows typical images of the brain and spine.

In the child who had anaesthesia, range of motion showed muscle shortening and not just spasticity. The findings of intraoperative macroscopic evaluation of the hip adductors muscles were consistent with fibrofatty degeneration (fig 4).

Of the seven children who underwent fundoscopic examination, five showed alterations in at least one eye (table 5). Of the six children who underwent hearing screening, four had a normal result, one had

Table 3 | Electromyographic findings

Patient No	Action potentials		
	Sensory nerves	Compound motor	Motor unit
1	Right and left median, right ulnar, right medial plantar: normal	Left median, right ulnar: low amplitude	Right and left extensor digitorum, right and left anterior tibial: neurogenic
2	Right median, right medial planar: normal	Right tibial, right and left fibular: low amplitude	Right extensor digitorum, right and left anterior tibial: neurogenic
3	Left ulnar, right medial planar: normal	Left ulnar, right tibial: low amplitude	Left extensor digitorum, left anterior tibial: neurogenic
4	Left medial planar: normal	Right and left tibial, right and left fibular: low amplitudes	Right and left extensor digitorum, left anterior tibial: neurogenic
5	Right median, right medial planar: normal	Left tibial: normal; right and left fibular: low amplitude	Right and left extensor digitorum, right and left anterior tibial: neurogenic
6	Right and left median, right ulnar: normal	Left median, right ulnar: normal	Right biceps brachii, right and left extensor digitorum: neurogenic; right and left anterior tibial: normal
7	Right and left median, right and left ulnar, right and left medial plantar: normal	Left median and tibial, right ulnar and fibular: low amplitude	Right and left extensor digitorum, right and left anterior tibial, left medial gastrocnemius: neurogenic

Table 4 | Brain imaging findings

Patient No	Decreased brain volume	Symmetry of findings	Cerebellum or brainstem hypoplasia	Ventriculomegaly	Large extraxial CSF space	Malformations of cortical development	Simplified gyral pattern	Corpus callosum	Calcifications			Brainstem	Predominance (>20)	Enlarged cisterna magna
									Cortical and subcortical white matter	Basal ganglia	Cerebellum			
1	Mild	Yes	Yes	Yes	No	Yes	Yes	Normal	Yes	Yes	No	Yes	Basal ganglia	Yes
2	Moderate	No	Yes	Yes	Mild	Yes	Yes	Pronounced hypogenetic	Yes	No	No	Yes	Periventricular	Pronounced
3	Yes	Yes	Yes	Yes	Yes	Yes	Yes	Hypogenetic	Yes	Yes	No	No	Cortical subcortical white matter	Yes
4	Moderate	Yes	Yes	Yes	Yes	Yes	Yes	Hypoplastic	Yes	Yes	No	Yes	Cortical subcortical white matter	Yes
5	Yes	Yes	Yes	Yes	Mild	Yes	Yes	Agenetic or pronounced hypogenetic	Yes	Yes	No	No	Cortical subcortical white matter	Pronounced
6	Severe	Yes	Yes	Yes	Yes	Yes	Yes	Hypogenetic	Yes	Yes	Yes	No	Cortical subcortical white matter	Pronounced
7	Severe	Yes	Yes	Yes	Yes	Yes	Yes	Pronounced hypogenetic	Yes	Yes	Yes	Yes	Cortical subcortical white matter	Yes

abnormalities in one ear, and one had abnormalities in both ears.

Discussion

In this series of children with joint contractures (arthrogryposis) associated with congenital infection presumably caused by Zika virus, all seven showed changes on brain imaging, with calcifications predominantly in the cortex and subcortical white matter (especially in the junction between the cortex and white matter), with abnormalities of cortical development and brainstem and cerebellar atrophy. Tests to evaluate arthrogryposis were consistent with a neurogenic pattern, with electromyographic findings and spinal MRI suggesting involvement of the lower motor neurones. Microcephaly and craniofacial disproportion have been common, but were not present in all cases.

Comparison with other studies

In microcephaly a baby's head is smaller than that of a baby of the same sex and age. Microcephaly is a clinical sign and not a disease. Increased rates of congenital microcephaly have been reported during the Zika virus outbreak in Brazil, beginning in late 2015.^{14 15} Genetic or environmental brain damage in utero can result in congenital microcephaly at birth, and infectious causes are well known; eg, rubella, cytomegalovirus, and toxoplasmosis.¹² Before 2015, evidence for a congenital infection presumed to be caused by Zika virus was lacking.

This disease goes beyond microcephaly, with other symptoms such as visual and hearing impairment, and unusual signs and symptoms different from other congenital infections, such as arthrogryposis and no microcephaly, suggesting that the term congenital Zika syndrome is more appropriate. The visual changes in this syndrome have been described previously.¹⁶

The presence of disorders of cortical development suggest that the insult occurred within the first five months of pregnancy.¹⁷ An earlier study reported three infants with fetal brain disruption sequence, a recognisable pattern of defects, consisting of severe microcephaly, overlapping sutures, prominence of the occipital bone, and scalp rugae.¹⁸ This condition seems to be produced by partial brain destruction during the second or third trimester, diminution in intracranial hydrostatic pressure, and subsequent collapse of the fetal skull.¹⁸ Several causes for this condition have been suggested, including partial disruption of the blood supply to the brain and prenatal infection with viruses.¹⁸ This finding is similar to that in our patients. Dysphagia was a common symptom, probably related to the severity of changes apparent on brain imaging, including hypoplasia of the brainstem and cerebellum.

Arthrogryposis is derived from the Greek words arthro (joint) and gryposis (crooked).¹⁹ The term arthrogryposis is often used as shorthand to describe multiple congenital contractures that affect two or more areas of

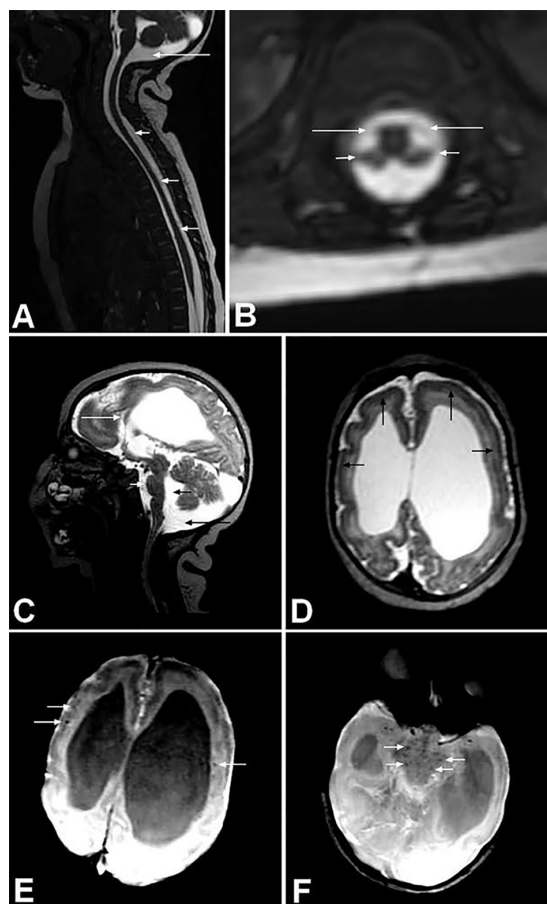


Fig 3 | Spine and brain magnetic resonance imaging of baby with arthrogryposis. Sagittal T2 weighted fast imaging employing steady state acquisition (FIESTA) (A) showing apparently reduced spinal cord thickness (short arrows) and mega cisterna magna (long arrow). Axial reconstruction of T2 weighted FIESTA (B) showing reduction of medullary cone ventral roots (long arrows) compared with dorsal roots (short arrows). Sagittal T2 weighted image (C) showing hypogenesis of corpus callosum (long white arrow), enlarged cisterna magna (long black arrow), enlarged fourth ventricle (short black arrow), and pons hypoplasia (short white arrow). Axial T2 weighted imaging (D) showing pachygyria in frontal lobes (black arrows) and severe ventriculomegaly, mainly at posterior part of lateral ventricles. Axial susceptibility weighted image (E and F) showing some hypointense small dystrophic calcifications (white arrows) in junction between cortical and subcortical white matter (E) and in midbrain (F)

the body. Arthrogryposis is not a specific diagnosis, but rather a clinical finding, and it is a characteristic of more than 300 disorders.¹⁹ Arthrogryposis can be divided into subgroups, as a way of generating a differential diagnosis, which includes neurological diseases (brain, spine, or peripheral nerve), connective tissue defects (diastrophic dysplasia), muscle abnormalities (muscular dystrophies or mitochondrial abnormalities), space limitations within the uterus (oligohydramnios, fibroids, uterine malformations, or multiple pregnancy), intrauterine or fetal vascular compromise (impaired normal development of nerves, or

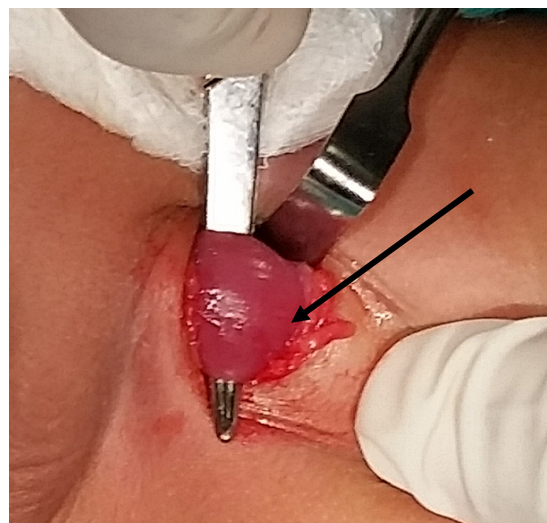

Fig 4 | Adductor longus muscle of child with irreducible dislocation of hips before surgery. Colour is characteristic of fibrofatty infiltration, typical of initial phase of neuropathies

anterior horn cell death), and maternal diseases (diabetes mellitus, multiple sclerosis, myasthenia gravis, infection, drugs, or trauma).⁹

Neurological abnormalities seem to be one of the most common causes of arthrogryposis (about 70-80% of cases).⁹ Developmental abnormalities affecting the forebrain (eg, hydranencephaly, microcephaly, forebrain neuronal migration disorders), whether primarily due to genetic factors or a consequence of infection in the fetal central nervous system, are sometimes associated with arthrogryposis. In most such cases, joint contractures are probably caused by diminished corticospinal tract activation of spinal cord motor neurones, or sometimes the underlying disease also directly injures spinal cord motor neurones, contributing to fetal hypomotility.^{9,10}

By 2015, there were no reports of congenital infections associated with arthrogryposis in humans. Two groups described the association between arthrogryposis and microcephaly in newborns with congenital infection presumably due to Zika virus,^{5,6} but without an indepth investigation of the possible causes and characterisation of deformities. The Arkabane virus, an arbovirus of the Simbu group of the family Bunyaviridae, might cause abortions, stillbirths, premature births, and deformed or anomalous bovine, caprine, and ovine fetuses or neonates, including brain malformations and arthrogryposis. Evidence for humans being infected by Akabane virus is lacking.²⁰

In our case series, the arthrogryposis did not result from abnormalities of the joints themselves but was likely to be of neurogenic origin, with chronic involvement of central and peripheral motor neurones, leading to fixed postures in utero and consequently deformities. Electromyographic findings suggest chronic involvement of peripheral motor neurones.

Table 5 | Ocular findings

Findings	Patient No						
	1	2	3	4	5	6	7
Macular pigment mottling	No	Both eyes	Both eyes	Left eye	No	Right eye	No
Optic disc pallor	No	Both eyes	No	No	No	Both eyes	No
Optic disc hypoplasia	No	Both eyes	No	No	No	No	No
Macular chorioretinal atrophic lesion	Right eye	Right eye	No	Left eye	No	Right eye	No
Chorioretinal atrophic macular lesion colobomatous	No	No	No	No	No	Left eye	No

In severely weak muscles the activation of the motor units was severely reduced, suggesting reduced central drive and involvement of central motor neurones. The pattern of peripheral denervation seems to correspond to the pattern of central involvement, which could suggest a component of trans-synaptic degeneration. Spinal MRI showed apparent thinning of the spinal cord, and a reduction in the ventral roots of medullary conus corroborate the findings on electromyography. An intraoperative macroscopic evaluation under anaesthesia is also consistent with findings on electromyography and spinal MRI.

Interestingly, developmental abnormalities of the cortex and arthrogryposis are found together in syndromes that result from exposure to misoprostol in utero and in perisylvian polymicrogyria.^{21,22} One study described neuropathological findings at autopsy and suggested a possible location of the virus in neurones.³ Another study found that Zika virus infection leads to cell cycle arrest, apoptosis, and inhibition of the differentiation of neural progenitor cells, resulting in cortical thinning and microcephaly.²³

Multiple hypotheses have been proposed to explain the presence of congenital joint contractures in some patients with abnormalities of brain development; these include an in utero vascular insult affecting both central and peripheral nervous systems, a common developmental mechanism of altered migration in both the brain and the spinal cord, and a direct central effect of the brain malformation on joint mobility in the fetus.²⁰ On the basis of our neurophysiological observations and the literature, we suggest two possible mechanisms: tropism for the neurones or neural progenitor cells, with involvement of peripheral motor neurons and central motor neurones; or a relation with vascular disorders.

Strengths and limitations of this study

In this case series we evaluated all seven children and carried out extensive imaging along with neurological and orthopaedic investigations, including fundoscopic examination and auditory screening. Further research is needed with a larger number of cases to study the neurological abnormalities behind arthrogryposis, including histopathology of autopsy samples or tissues from stillborn babies. As we do not know the potential implications of congenital Zika virus infection as it evolves, children must receive orthopaedic follow-up, even those with a standard first orthopaedic evaluation, because they could

develop musculoskeletal deformities secondary to neurological impairment, central or peripheral, or both, as these occur in patients with cerebral palsy and other chronic encephalopathies.

Conclusion

Congenital Zika syndrome should be added to the differential diagnosis of congenital infections and arthrogryposis.

Contributors: VvdL and ELRF coordinated all work and did most of the writing. VvdL, AvdL, PFSdS, and MDCGdC were responsible for the neurological data. ELRF was responsible for the orthopaedic data. OGL was responsible for the electromyographic data. RCR, MAWR, and DDCSC were responsible for laboratory data to exclude other congenital infections. FJdA was responsible for the ultrasonographic data. MdFVA and AMB-L helped to analyse brain and spinal cord imaging. CVV assisted with the ophthalmologic data. FJdA and ICRdM assisted the patients admitted to an intensive care unit. All authors reviewed and commented on drafts and approved the final manuscript and the decision to submit for publication. VvdL is the guarantor.

Competing interests: All authors have completed the ICMJE uniform disclosure form at www.icmje.org/coi_disclosure.pdf and declare: no support from any organisation for the submitted work; no financial relationships with any organisations that might have an interest in the submitted work in the previous three years; no other relationships or activities that could appear to have influenced the submitted work.

Ethical approval: All investigations described were conducted as part of a clinical protocol approved by the Brazilian government and analysed retrospectively; no investigations were conducted for research reasons and, therefore, neither ethical approval nor informed consent was necessary.

Patient consent: The authors obtained written consent from parents for publication of the images in figures 1 to 4. All mothers gave consent for neuroimaging studies to be performed as part of the Brazilian microcephaly outbreak protocol or clinical indication. All seven cases have been deidentified, and we decided to proceed with publication in the interests of public health.

Data sharing: No additional data available.

Transparency: The lead author (VvdL) affirms that the manuscript is an honest, accurate and transparent account of the study being reported; that no important aspects of the study have been omitted.

This is an Open Access article distributed in accordance with the Creative Commons Attribution Non Commercial (CC BY-NC 3.0) license, which permits others to distribute, remix, adapt, build upon this work non-commercially, and license their derivative works on different terms, provided the original work is properly cited and the use is non-commercial. See: <http://creativecommons.org/licenses/by-nc/3.0/>.

- 1 Heukelbach J, Alencar CH, Kelvin AA, de Oliveira WK, Pamplona de Góes Cavalcanti L. Zika virus outbreak in Brazil. *J Infect Dev Ctries* 2016;10:116-20.
- 2 Calvet G, Aguiar RS, Melo ASO, et al. Detection and sequencing of Zika virus from amniotic fluid of fetuses with microcephaly in Brazil: a case study. *Lancet Infect Dis* 2016;16:653-60.
- 3 Mlakar J, Korva M, Tul N, et al. Zika virus associated with microcephaly. *N Engl J Med* 2016;374:951-8.
- 4 Rasmussen SA, Jamieson DJ, Honein MA, Petersen LR. Zika Virus and Birth Defects—Reviewing the Evidence for Causality. *N Engl J Med* 2016;374:1981-7.

- 5 Schuler-Faccini L, Ribeiro EM, Feitosa IML, et al. Brazilian Medical Genetics Society–Zika Embryopathy Task Force. Possible Association Between Zika Virus Infection and Microcephaly–Brazil, 2015. *MMWR Morb Mortal Wkly Rep* 2016;65:59-62.
- 6 Oliveira Melo AS, Malinger G, Ximenes R, Szejnfeld PO, Alves Sampaio S, Bispo de Filippis AM. Zika virus intrauterine infection causes fetal brain abnormality and microcephaly: tip of the iceberg? *Ultrasound Obstet Gynecol* 2016;47:6-7.
- 7 Fedrizzi E, Botteon G, Inverno M, Ciceri E, D'Incerti L, Dworzak F. Neurogenic arthrogryposis multiplex congenita: clinical and MRI findings. *Pediatr Neurol* 1993;9:343-8.
- 8 Bamshad M, Van Heest AE, Pleasure D. Arthrogryposis: a review and update. *J Bone Joint Surg Am* 2009;91(Suppl 4):40-6.
- 9 Kalampokas E, Kalampokas T, Sofoudis C, Deligeorgiou E, Botsis D. Diagnosing arthrogryposis multiplex congenita: a review. *ISRN Obstet Gynecol* 2012;2012:264918. doi:10.5402/2012/264918.
- 10 Bamshad M, Van Heest AE, Pleasure D. Arthrogryposis: a review and update. *J Bone Joint Surg Am* 2009;91(Suppl 4):40-6.
- 11 Martin DA, Muth DA, Brown T, Johnson AJ, Karabatsos N, Roehrig JT. Standardization of immunoglobulin M capture enzyme-linked immunosorbent assays for routine diagnosis of arboviral infections. *J Clin Microbiol* 2000;38:1823-6.
- 12 World Health Organization. Assessment of infants with microcephaly in the context of Zika. Interim guidance. 25 February 2016. WHO/ZIKV/MOC/16.3. WHO.
- 13 Villar J, Cheikh Ismail L, Victora CG, et al. International Fetal and Newborn Growth Consortium for the 21st Century (INTERGROWTH-21st). International standards for newborn weight, length, and head circumference by gestational age and sex: the Newborn Cross-Sectional Study of the INTERGROWTH-21st Project. *Lancet* 2014;384:857-68.
- 14 Brasil-Ministério da Saúde. Protocolo de vigilância e resposta à ocorrência de microcefalia relacionada à infecção pelo vírus Zika. Available at: <http://portalsaude.saude.gov.br/images/pdf/2015/dezembro/09/Microcefalia---Protocolo-de-vigil-ncia-e-resposta---vers-o-1-----09dez2015-8h.pdf> [Accessed: January 26, 2016].
- 15 Brasil-Ministério da Saúde. Ministério da saúde atualiza casos suspeitos de microcefalia. Available at: <http://portalsaude.saude.gov.br/index.php/cidadao/principal/agencia-saude/21890-ministerio-da-saude-investiga-3-448-casos-suspeitos-de-microcefalia>. [Accessed: February 1, 2016].
- 16 Ventura CV, Maia M, Ventura BV, et al. Ophthalmological findings in infants with microcephaly and presumable intra-uterus Zika virus infection. *Arq Bras Oftalmol* 2016;79:1-3.
- 17 Volpe JJ. *Neurology of the Newborn*. 4th ed. WB Saunders, 2008.
- 18 Russell LJ, Weaver DD, Bull MJ, Weinbaum M. In utero brain destruction resulting in collapse of the fetal skull, microcephaly, scalp rugae, and neurologic impairment: the fetal brain disruption sequence. *Am J Med Genet* 1984;17:509-21.
- 19 Møller-Madsen B. Arthrogryposis multiplex congenita-an update. *J Child Orthop* 2015;9:425-6.
- 20 Akabane (Congenital arthrogryposis-hydranencephaly syndrome, A-H syndrome, Akabane disease, congenital bovine epizootic A-H syndrome, acorn calves, silly calves, curly lamb disease, curly calf disease, dummy calf disease). http://www.vet.uga.edu/vpp/gray_book/Handheld/aka.htm.
- 21 Marques-Dias MJ. Physiopathogeny of moebius syndrome and arthrogriposis due to in utero misoprostol exposure. Thesis. São Paulo, 1999.
- 22 Poduri A, Chitsazadeh V, D'Arrigo S, et al. The syndrome of perisylvian polymicrogyria with congenital arthrogryposis. *Brain Dev* 2010;32:550-5.
- 23 Li C, Xu D, Ye Q, et al. Zika Virus Disrupts Neural Progenitor Development and Leads to Microcephaly in Mice. *Cell Stem Cell* 2016;19:120-6.
- 24 Dick GW, Kitchen SF, Haddow AJ. Zika virus. I. Isolations and serological specificity. *Trans R Soc Trop Med Hyg* 1952;46:509-20.
- 25 Dick GW. Zika virus. II. Pathogenicity and physical properties. *Trans R Soc Trop Med Hyg* 1952;46:521-34.
- 26 Duffy MR, Chen TH, Hancock WT, et al. Zika virus outbreak on Yap Island, Federated States of Micronesia. *N Engl J Med* 2009;360:2536-43.
- 27 Besnard M, Lestere S, Teissier A, Cao-Lormeau V, Musso D. Evidence of perinatal transmission of Zika virus, French Polynesia, December 2013 and February 2014. *Euro surveill.* 2014;3:19(13).
- 28 Tognarelli J, Ulloa S, Villagra E, et al. A report on the outbreak of Zika virus on Easter Island, South Pacific, 2014. *Arch Virol* 2016;161:665-8.
- 29 Zanluca C, Melo VC, Mosimann AL, Santos GI, Santos CN, Luz K. First report of autochthonous transmission of Zika virus in Brazil. *Mem Inst Oswaldo Cruz* 2015;110:569-72.
- 30 Tavernise S, McNeil DG Jr. Zika virus a global health emergence, WHO says. 2016 Feb 1 [cited 2016 Feb 20]. In: New York Times. http://www.nytimes.com/2016/02/02/health/zika-virus-world-health-organization.html?_r=0
- 31 Mussi-Pinhata MM, Yamamoto AY. [Congenital and perinatal infections]. *J Pediatr (Rio J)* 1999;75(Suppl 1):S15-30.