

ENDGAMES

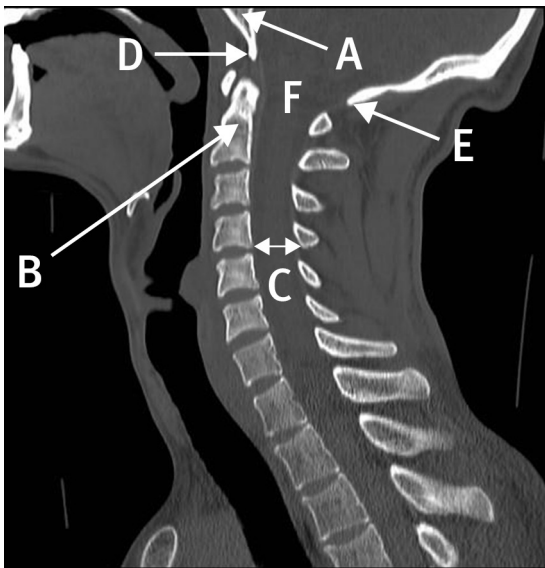
ANATOMY QUIZ

Sagittal computed tomogram of the cervicothoracic spine

Lorna Luo *medical student*¹, Senthil K Selvanathan *specialist registrar in neurosurgery*²

¹Medical School, University of Leeds, Leeds, UK; ²Department of Neurosurgery, Leeds General Infirmary, Leeds LS1 3EX, UK

Identify the structures labelled A, B, C, D, E, and F on this sagittal computed tomogram of the cervicothoracic spine.



Answers

- A: Clivus
- B: Odontoid peg
- C: Spinal canal
- D: Basion
- E: Opisthion
- F: Foramen magnum

Cite this as: *BMJ* 2014;349:g4795

© BMJ Publishing Group Ltd 2014