

## The Sick Dürer—a Renaissance prototype pain map

G D Schott

National Hospital  
for Neurology and  
Neurosurgery,  
London  
WC1N 3BG  
G D Schott  
consultant neurologist  
geoffrey.schott@  
uclh.org

BMJ 2004;329:1492

Modern pain mapping was introduced in 1949, when Palmer provided outline diagrams of the human body, and the patient was “invited to mark in on the charts wherever he experiences pain.”<sup>1</sup> Palmer’s maps not only used colours for the different varieties of pain, he also used the maps to distinguish functional from organic pain. Since then, pain maps have become widely used in clinical practice, and are included in the McGill pain questionnaire. They represent an accurate, permanent, and repeatable graphic device for delineating where pain is felt, but they also have been used to provide qualitative information—including the extent to which psychological factors contribute to an individual’s pain.<sup>2</sup>

Half a millennium earlier, Albrecht Dürer (1471-1528), the illustrious German printmaker, painter, and designer, produced an intriguing pen and watercolour, half length self portrait. *The Sick Dürer* is small, 12 cm×11 cm, and on it Dürer wrote, “Do wo der gelb fleck is und mit dem finger drawff dewt do is mir we” (There, where the yellow spot is located, and where I point my finger, there it hurts”). Why Dürer used colour remains a mystery, but it could have been added for emphasis, just as his index finger draws attention to the painful part.

The picture was sent to an out of town physician whom Dürer had consulted. When it was painted is uncertain, and suggested dates range from 1509 to 1521.<sup>3</sup> Dürer had been unwell on several occasions during this period, but it seems most likely that the picture relates to the illness he contracted in 1520. In the spring of 1521 Dürer recorded in his diary that, during a journey to the Netherlands the previous year, he had been seriously ill: “In the third week after Easter I was seized by a hot fever, great weakness, nausea, and headache. And before, when I was in Zeeland, a strange sickness came over me, such as I have never heard of from any man, and I still have this sickness.”<sup>4</sup> His fever periodically recurred, though in the intervening periods he was reportedly in excellent health. Dürer may have had malaria, but other diagnoses have been suggested—hepatic and splenic diseases, tuberculosis, syphilis, mental illness, and even poisoning by his competitors.<sup>5</sup>

Though the illness remains unclear, and though the picture cannot be exactly dated, Dürer was



*The Sick Dürer*, by Albrecht Dürer (1471-1528), held at the Kunsthalle, Bremen.

undoubtedly in pain, and he mapped exactly where he felt that pain. The precise delineation, addition of colour, emphasising finger, and annotation are striking features of this Renaissance pain map. It took five centuries until modern pain maps, some showing not dissimilar features, were introduced—or, as this picture suggests, were re-introduced.

Competing interests: None declared.

- 1 Palmer H. Pain charts. A description of a technique whereby functional pain may be distinguished from organic pain. *N Z Med J* 1949;48:187-213.
- 2 Rankine JJ, Fortune DG, Hutchinson CE, Hughes DG, Main CJ. Pain drawings in the assessment of nerve root compression: a comparative study with lumbar spine magnetic resonance imaging. *Spine* 1998;23:1668-76.
- 3 Strauss WL. *The complete drawings of Albrecht Dürer. Vol 3, 1510-1519*. New York: Abaris Books, 1974:1758.
- 4 Hutchison JC. *Albrecht Dürer. A biography*. Princeton: Princeton University Press, 1990:162.
- 5 Timken-Zinkann RF. Medical aspects of the art and life of Albrecht Dürer (1471-1528). In: *Proceedings of the XXIII international congress of the history of medicine, 1972, vol 2*. London: Wellcome Institute of the History of Medicine, 1974:870-5.

## Can you tell your clunus from your cubitus? A benchmark for functional imaging

Alison E Fisher, Gareth R Barnes, Arjan Hillebrand, Caroline Burrow, Paul L Furlong, Ian E Holliday

Correspondence to:  
G R Barnes  
barnesgr@aston.ac.uk  
continued over

BMJ 2004;329:1492-3

Advances in functional brain imaging have allowed the development of new investigative techniques with clinical application—ranging from presurgical mapping of eloquent cortex to identifying cortical regions

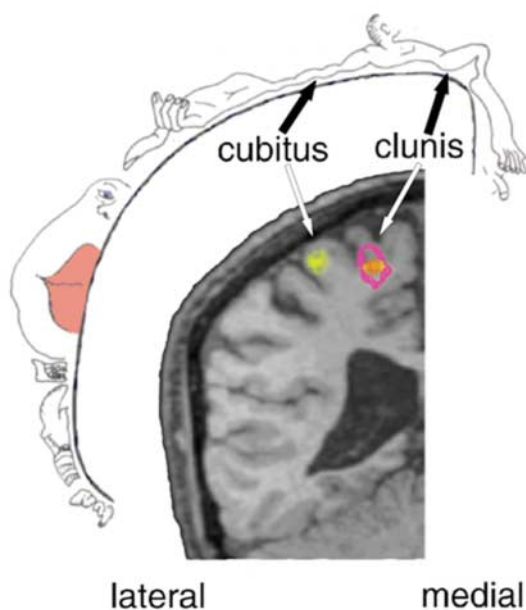
involved in religious experiences. Similarly a variety of methods are available to referring physicians, ranging from metabolic measures such as functional magnetic resonance imaging and positron emission tomography

to measurements based on electrical activity such as electroencephalography and magnetoencephalography. However, there are no universal benchmarks by which to judge between these methods. In this study we attempt to develop a standard for functional localisation, based on the known functional organisation of somatosensory cortex.<sup>1</sup>

Studies have shown spatially distinct sites of brain activity in response to stimulation of various body parts.<sup>2</sup> Generally these studies have focused on areas with large cortical representations, such as the index finger and face.<sup>3,4</sup> We tested the limits of magnetoencephalography source localisation by stimulation of body parts, namely the clunus and the cubitus, that map to proximal and relatively poorly represented regions of somatosensory cortex.

### Participants, methods, and results

Three participants (two men, one woman, aged 25-35 years) lay comfortably in a whole head Omega magnetoencephalograph (CTF Systems). We attached single disposable electrodes to each participant's right clunus (upper portion) and across the right cubitus. Electrical stimulation was delivered at twice the sensory threshold for each site. An experimenter sat beside each participant within the magnetically shielded room and operated an electrical switch to alternate the stimulation site when prompted by a visual cue. Fifty stimuli were delivered to each site in a boxcar design (5 seconds on, 5 seconds off). We collected magnetoencephalographic data using a 625 Hz sampling rate and averaged them for each stimulation site. We then co-registered the data with each participant's



Magnetoencephalography identified sites of brain activity in the left hemisphere, including 95% confidence ellipsoids, for stimulation of right cubitus (yellow) and clunus (purple). Note the close correspondence with Penfield's homunculus<sup>1</sup>

### What is already known on this topic

The ability to differentiate between one's clunus and one's cubitus is a nationally accepted minimum level of professional and social performance

### What this study adds

The same metric could be used to judge between brain imaging techniques

anatomical magnetic resonance image, using a surface matching approach. A single equivalent current dipole was fitted to the first evoked response peak. For each reconstructed location of brain activity, we used a Monte Carlo simulation to generate 95% confidence ellipsoids.

The figure shows identified sites of cortical activity, and 95% confidence ellipsoids, corresponding to stimulation of the clunus and cubitus superimposed on a representative magnetic resonance image. The two cortical sites are clearly distinct, with no overlap of the 95% confidence volumes. Furthermore, the data are in good agreement with Penfield's neurosurgically established homunculus.<sup>1</sup>

### Comment

We found that magnetoencephalography can successfully differentiate your clunus from your cubitus, despite the small cortical representation and close proximity of these areas, and despite informal behavioural observations which suggested that one of the participants (IEH) was incapable of such a distinction himself. Further work might involve the investigation of gender differences. To conclude, perhaps the most accessible and objective heuristic for the evaluation of any functional imaging technique comes in the form of a popular English idiom.<sup>5</sup>

We thank the reviewers, who would clearly make model subjects for this study, for their insightful comments.

Contributors: All authors contributed equally to this work. GRB is guarantor for the study.

Funding: The magnetoencephalograph used was jointly funded by HEFCE and the Wellcome Trust. AEF is funded by the Lord Dowding Fund for Humane Research.

Competing interests: None declared.

- 1 Penfield W, Boldrey E. Somatic motor and sensory representation in the cerebral cortex of man as studied by electrical stimulation. *Brain* 1937;60:389-443.
- 2 Narici L, Modena I, Opsomer RJ, Pizzella V, Romani GL, Torrioli G, et al. Neuromagnetic somatosensory homunculus: a non-invasive approach in humans. *Neurosci Lett* 1991;121:51-4.
- 3 Itomi K, Kakigi R, Hoshiyama M, Watanabe K. A unique area of the homunculus: the topography of the primary somatosensory cortex in humans following posterior scalp and shoulder stimulation. *Brain Topogr* 2001;14:15-23.
- 4 Yang TT, Gallen CC, Schwartz BJ, Bloom FE. Noninvasive somatosensory homunculus mapping in humans by using a large-array biomagnetometer. *Proc Natl Acad Sci USA* 1993;90:3098-102.
- 5 "Can't tell your arse from your elbow"—if you can't tell your arse from your elbow, you are stupid and become confused about simple things. Example: "It's no good asking him to organize anything—he can't tell his arse from his elbow." *Cambridge international dictionary of idioms*. Cambridge: Cambridge University Press, 2003.

Neurosciences Research Institute, Aston University, Birmingham B4 7ET

Alison E Fisher contract research fellow

Gareth R Barnes tenured research fellow

Arjan Hillebrand tenured research fellow

Caroline Burrow contract research fellow

Paul I Furlong lecturer in psychology

Ian E Holliday lecturer in psychology