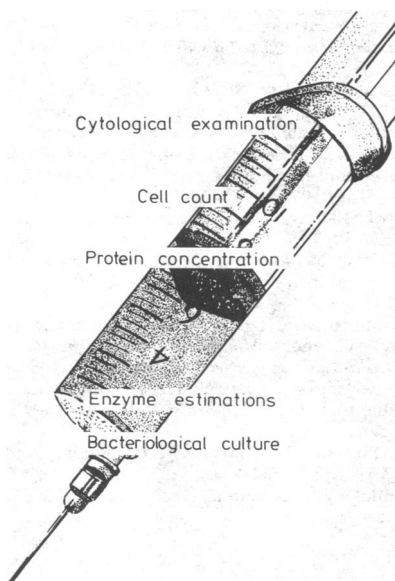


Procedures in Practice

E RYAN
G NEALE

TAPPING ASCITES (2)

Specimens



The appearance of the fluid removed by tapping the abdomen should be noted. A cloudy fluid often means peritonitis; uniform bloodstaining is most often found in patients who have cancer or who have suffered trauma to the abdomen; and a milky fluid indicates chylous ascites.

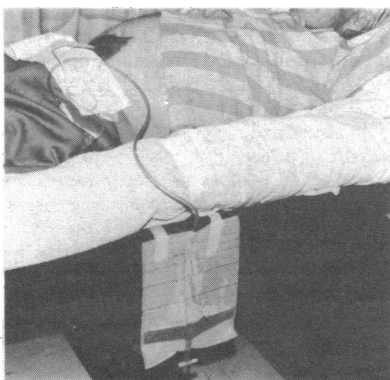Aliquots of the fluid are sent to the laboratory for cytological examination, cell count, measurement of protein concentration, and, in selected cases, enzyme estimations and bacteriological culture. Table II summarises the results to be expected, but these must be interpreted cautiously.

Fluid is removed from the peritoneal cavity most often in patients with ascites due to cirrhosis, especially when a complication is suspected. Spontaneous bacterial infection is a frequent worry, and thus abdominal tap should be performed in any patient with cirrhosis and ascites if he develops fever without obvious cause, abdominal pain, diarrhoea, or encephalopathy. In uncomplicated cases the fluid from a patient with cirrhosis is clear and yellow, contains few white cells, and has a low concentration of total protein. A high white cell count may indicate spontaneous bacterial peritonitis; a high protein concentration may point to hepatoma; and high amylase activity is associated with pancreatic disease. Nevertheless, 10% of patients with ascites secondary to uncomplicated cirrhosis have white cell counts of over $1 \times 10^9/l$ ($1000/mm^3$), and high protein concentrations have been described in a similar proportion.

TABLE II—Guide to results of laboratory tests on ascitic fluid

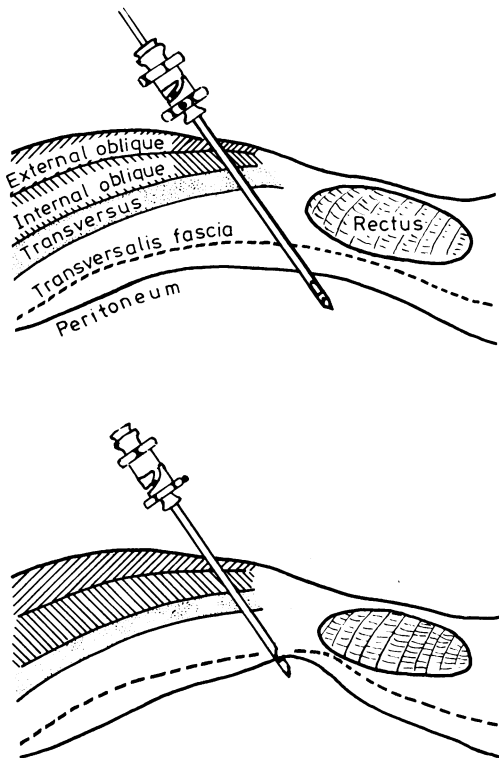
Source of ascites	Appearance	Protein concentration (g/l)	Total white cell count ($\times 10^9/l$)	Polymorphonuclear leucocytes (%)	Lymphocytes (%)	Amylase activity	Microscopy	Culture
Uncomplicated cirrhosis	Clear	30 (occasionally high)	<0.3 (occasionally high)	<25	>75	Low	Negative	Negative
Neoplastic	Bloodstained or clear	25 (sometimes low)	0.1-1.0	<50	>50	Low	May be positive	Negative
Pancreatic	Clear or serosanguinous	30	Variable	Variable	Variable	High	Negative	Negative
Tuberculous	Clear-cloudy	30	Variable	<50	>50	Low	Positive peritoneal biopsy	Positive
Nephrotic	Clear	10	<0.3	<25	>75	Low	Negative	Negative
Cardiac	Clear	Variable (sometimes high)	<0.3	<25	>75	Low	Negative	Negative
Spontaneous bacterial peritonitis	Cloudy	25	>0.3	>75	<25	Low	Positive	Positive

Therapeutic implications



Occasionally in patients with massive ascites a large quantity of fluid may have to be removed. This may best be performed through the avascular linea alba. Anaesthetise and cleanse the abdominal wall and pass a plastic intravenous cannula (14 gauge) through it. Remove the introducer and thread the cannula into the abdomen until fluid flows freely. Connect the cannula to a drainage bag and control the flow of fluid with an adjustable clip. Remove up to two litres over about four hours (rapid removal of fluid may cause hypotension). If necessary reposition the patient or the cannula to maintain the flow of fluid. Cytotoxic agents may be introduced through the cannula in appropriate dosage. After sufficient fluid has been removed take out the cannula and apply a firm dressing.

Peritoneal biopsy

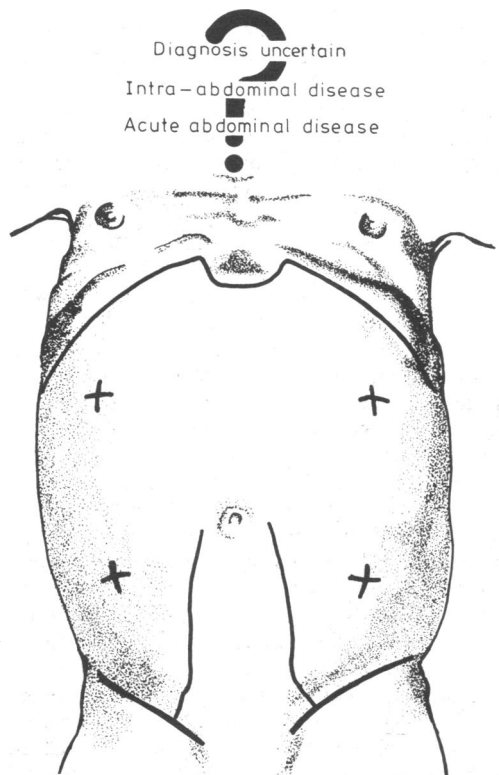


Indication—Biopsy of the peritoneum is useful in diagnosing non-purulent ascites in which the fluid has a protein concentration of over 25 g/l, is not rich in amylase, and in which direct examination does not show malignant cells or acid-fast bacilli.

Method—Ascertain the presence of ascitic fluid by tapping the abdomen in the standard manner. Remove the exploring needle and introduce an Abrams punch through a small skin incision. Attach the punch to a syringe and open the notch by twisting the hexagonal grip anticlockwise. Aspirate a little fluid. Angle the open notch against the peritoneal surface and withdraw the punch slowly until it engages the abdominal wall. Twist the hexagonal grip clockwise and withdraw the punch. Remove any tissue from the edge of the notch and, if necessary, repeat the procedure (it is virtually impossible to obtain tissue when the peritoneal surface is normal).

Specimens—Routine histological procedures are used to examine the specimens obtained. Peritoneal biopsy gives a high yield in patients with tuberculous peritonitis and is also useful in diagnosing cancer seedlings affecting the parietal peritoneum.

Tapping the acute abdomen



Paracentesis is not used universally to investigate patients with acute abdominal disorders even though many reports over the past 50 years have extolled its value. It is used when the diagnosis is in doubt, especially after abdominal trauma. The method is similar to that used in tapping a clinically demonstrable volume of ascitic fluid, but the site of puncture is determined by the local clinical findings. If there is generalised abdominal tenderness tapping in the four quadrants of the abdomen may be performed followed by needling the flanks. Local anaesthesia is usually unnecessary for this procedure. If the tap yields no fluid and there is still doubt about the diagnosis it may be worth while attempting to aspirate fluid from the pouch of Douglas. This is done by inserting a dialysis catheter through the linea alba, and some doctors believe that peritoneal lavage using this technique may be helpful.

Indications for the procedure are as follows: (1) puzzling diagnostic problems, especially in those regarded as presenting high operative risks; (2) obtunded patients in whom there are signs suggesting intra-abdominal disease (especially after trauma); and (3) suspected non-surgical acute abdominal disease (for example, pancreatitis).

Contraindications—Paracentesis should not be carried out on: (1) patients in whom the diagnosis appears to be clear-cut or in whom a diagnosis may be achieved by non-invasive investigations; (2) patients with multiple scars and distended bowel; (3) patients with localised inflammatory disease (results are usually unhelpful); and (4) pregnant patients.

Precautions—Analysis of fluid obtained by lavage should not be relied on if the results are inconsistent with other findings. The procedure is probably most usefully performed if one doctor in hospital takes special responsibility for the investigation and its interpretation.

This is the second and concluding part of this article; the first part appeared last week.

Dr E Ryan, MB, MRCPI, is a fellow in endocrinology at the University of Miami, Florida, and Dr G Neale, MB, FRCP, is consultant gastroenterologist and consultant in clinical nutrition at Addenbrooke's Hospital, Cambridge. (Dr Ryan was formerly a lecturer and Dr Neale a professor in the department of clinical medicine, St James's Hospital, Dublin.)