

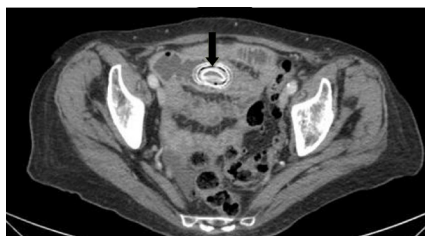


MINERVA

Small bowel diverticulosis

Neil Chanchlani *foundation year two doctor*, James R Goodhand *gastroenterology registrar*, Rebecca S Lewis *surgical registrar*, Nick G Reading *consultant radiologist*, Elizabeth Carty *consultant gastroenterologist*

Whipps Cross Hospital, London E11 1NR, UK



An 88 year old woman presented with a one week history of vomiting, abdominal pain, and distension. Computed tomography of the abdomen showed obstruction of the distal

small bowel by a lamellated calculus (arrow). Although initially thought to be a gallstone ileus, this diagnosis was refuted by the absence of pneumobilia and the observation of gallbladder stones with a different appearance from the obstructing calculus. Enteroliths similar to the obstructing calculus were seen, however, in several large jejunal diverticula. At laparotomy, a 3.5 cm enterolith was removed from the distal ileum. The patient made an uneventful recovery; rates of recurrence are unknown.

Patient consent obtained.

Cite this as: *BMJ* 2015;350:h1920

© BMJ Publishing Group Ltd 2015