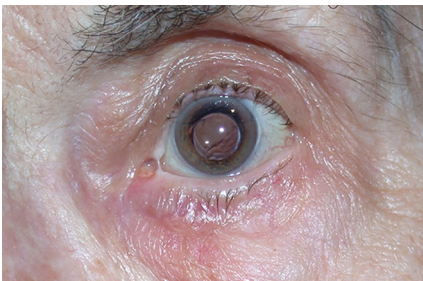


# MINERVA

## Incomplete eyelid disjunction

Ali S Hassan *specialist trainee year 3*, Huw Oliphant *specialist trainee year 1*, Paul Baddeley *consultant*, Khin Nyunt *associate specialist*

Worthing Hospital, Worthing, West Sussex BN11 2DH, UK



An 87 year old woman was found to have a band connecting the left upper and lower eyelids close to her lacrimal puncta. She had no new ophthalmic problems. Eyelids fuse together

during fetal development, with separation normally occurring at 5-6 months' gestation. Congenital ankyloblepharon (congenital eyelid band syndromes) are caused by abnormal eyelid separation. Incomplete eyelid separation results in tissue remnants connecting the upper and lower eyelids. This condition is usually an isolated sporadic finding. It has also been reported in association with cleft lip and palate, trisomy 18, imperforate anus, and cardiac anomalies. If the visual axis is restricted, prompt separation is needed to allow normal visual development.

Patient consent obtained.

Cite this as: *BMJ* 2014;349:g5095

© BMJ Publishing Group Ltd 2014