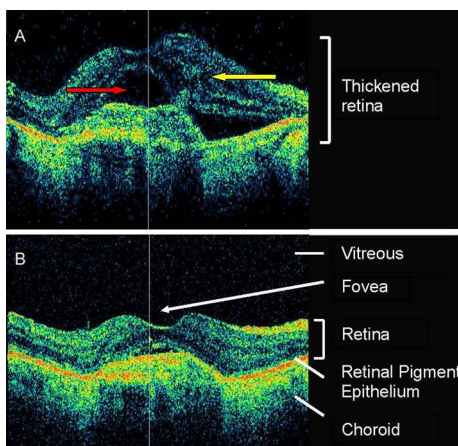


## MINERVA

Hannah Timlin *specialty training 1*, Caroline Styles *consultant*

Ophthalmology Department, Queen Margaret Hospital, Dunfermline, Fife, UK



tomography of the retinal layers showed subretinal fluid (A, red arrow) and intraretinal fluid (yellow arrow). She was diagnosed with wet age related macular degeneration and received monthly injections of anti-vascular endothelial growth factor into the vitreous. After three injections the retinal fluid resolved (B) and her vision improved to 6/9.5. Metamorphopsia is a typical symptom of wet age related macular degeneration. Early referral and prompt treatment with anti-vascular endothelial growth factor can result in visual improvement, with the best results if treated within two weeks of symptom onset.

Patient consent obtained.

Cite this as: [BMJ 2011;342:d3221](https://doi.org/10.1136/bmj.d3221)

A 76 year old woman presented with metamorphopsia (distortion of straight lines) and reduced vision of 6/36. Optical coherence