

Regular Review

Surgical correction of nearsightedness

Samir J Bechara, Keith P Thompson, George O Waring III

Nearsightedness (or myopia) has been recognised for more than 2000 years<sup>1</sup>; during the past several centuries, efforts have been made to determine its cause and to devise adequate treatment. About a quarter of the population in the West is nearsighted,<sup>1,3</sup> and this proportion rises to almost 50% in Asia.<sup>4</sup> In the United States nearly a quarter of people aged 12-54 are myopic, and the proportion increases considerably with family income and educational level. Myopia is less prevalent in men and in blacks.<sup>2</sup>

Myopia occurs when parallel rays of light entering the eye are brought to focus in front of the retina, causing distant objects to be blurred while the near vision is preserved.<sup>5</sup> The amount of myopia is measured in negative dioptres. A dioptre is the unit of measure of the power of a spectacle or contact lens, and one dioptre is equal to the power of a lens with a focal length of one metre. Therefore, a subject who has -5.00 dioptres of myopia needs a concave corrective lens with a power of -5.00 dioptres to neutralise that refractive error and provide normal visual acuity. Among myopic people, 80% have up to -6.00 dioptres of myopia.

Treatment for myopia has included herbs and procedures based on superstitions that predate recorded history.<sup>6</sup> For centuries prosthetic devices such as spectacles were the only option to correct myopia. Other non-surgical treatments such as orthokeratology,<sup>7</sup> cycloplegic agents,<sup>8</sup> and bifocal lenses<sup>9</sup> failed to show effective or consistent results. Spectacles provide an efficient optical solution but they are often inconvenient, they limit some activities, and they are considered unattractive by some people. Many myopic people would like normal vision without dependence on external devices, and this is what drives most patients to consider ocular surgery.<sup>10</sup>

Refractive surgery includes any operation intended to alter the refractive state of the eye.<sup>11</sup> The ideal refractive surgical procedure should provide predictable, reversible, adjustable, and stable correction without any loss of corrected visual acuity. Surgical methods to treat refractive errors were first proposed a century ago, and the main developments in this field are shown in the table. There are currently more than

Surgical procedures to treat myopia

**Refractive keratoplasty**—surgical techniques that change the corneal refractive power

- Lamellar techniques
  - Keratomileusis
  - Epikeratoplasty
  - Intracorneal lens
  - Lamellar keratoplasty
- Refractive keratotomy
  - Radial keratotomy
  - Transverse keratotomy for astigmatism

- Excimer laser (photorefractive keratectomy)
- Penetrating keratoplasty (refractive aspects)

**Intraocular implants**—surgical techniques that change the power of the lens

- Aphakic intraocular lens
- Phakic intraocular lens

**Posterior scleral support**—surgical techniques that act on the axial length of the eye

20 procedures to treat nearsightedness: they can be classified according to surgical technique (box).<sup>11</sup>

We review the major surgical procedures currently performed in clinical practice to treat myopia, highlighting the aspects that are of interest to non-ophthalmologists.

Refractive keratoplasty

The cornea is the most powerful refracting surface of the eye, accounting for more than two thirds of the eye's optical power.<sup>15</sup> Refractive keratoplasty refers to surgical procedures designed to correct refractive error by altering the refractive state of the cornea, either by changing its anterior radius of curvature or by changing its index of refraction. All refractive keratoplasty procedures attempt to change the radius of the anterior surface of the cornea, except when intracorneal lenses with a high index of refraction are used.

KERATOMILEUSIS

Keratomileusis was proposed by Jose Barraquer in Colombia in 1949,<sup>15</sup> and he first reported clinical results in 1964.<sup>20</sup> A disc of anterior cornea approximately 9 mm in diameter and 300 µm thick is removed with a microkeratome (a cutting instrument consisting of a vibrating plane that slides across the cornea), ground into a new shape, and sutured back into position (fig 1). The button is reshaped by cryolathing,<sup>21</sup> cutting on a mould,<sup>22</sup> or with the laser.

Department of  
Ophthalmology, Emory  
University School of  
Medicine, Atlanta, Georgia  
30322, USA  
Samir J Bechara,  
international fellow  
Keith P Thompson,  
assistant professor  
George O Waring III,  
professor

Correspondence and  
requests for reprints to:  
Dr G O Waring III,  
Department of  
Ophthalmology, Emory Eye  
Center, 1327 Clifton Rd NE,  
Atlanta, GA 30322, USA.

BMJ 1992;305:813-7

Main developments in refractive surgery for myopia

Year	Author	Contribution
1890	Fukala	Removal of the lens for high myopia <sup>12</sup>
1894	Bates <sup>13</sup>	Keratotomy for astigmatism
1898	Lans <sup>14</sup>	Keratotomy for astigmatism
1949	Barraquer <sup>15</sup>	Keratophakia and keratomileusis
1953	Sato <i>et al</i> <sup>16</sup>	Anterior and posterior radial keratotomy
1972	Fyodorov and Durnev <sup>17</sup>	Anterior radial keratotomy
1979	Werblin and Klyce <sup>18</sup>	Epikeratoplasty
1983	Trokel <i>et al</i> <sup>19</sup>	Excimer laser

Keratomileusis is indicated for high myopia ( $-5.00$  to  $-15.00$  dioptres), especially when other techniques are considered insufficient to achieve a desired result.<sup>23</sup> After the operation it may take up to six months for the refraction to stabilise,<sup>24</sup> and most published series indicate that the refractive results of keratomileusis are unpredictable.<sup>25-27</sup>

Major intraoperative complications include inadvertent corneal perforation (requiring a full thickness corneal transplantation), irregular disc removal, and irregular stromal carving.<sup>26</sup> Postoperative complications include corneal opacities and irregular astigmatism leading to loss of best corrected visual acuity, as well as overcorrection and undercorrection.<sup>24 27 28</sup>

Notwithstanding its inherent problems and difficulties, keratomileusis was the first procedure that provided correction for high myopia. In the hands of a well trained surgeon it offers a reasonable chance of permanent correction of high myopia. The major disadvantages of keratomileusis are its technical complexity, the high cost of instrumentation, and unpredictable refractive outcome. For these reasons only a handful of surgeons in the world currently perform keratomileusis.

#### EPIKERATOPLASTY

Motivated to simplify keratomileusis, Werblin,<sup>18</sup> Kaufman,<sup>29</sup> and McDonald<sup>30</sup> developed a new technique in 1979. In epikeratoplasty a lenticule cut from a donated cornea is placed on a de-epithelialised cornea of the recipient (fig 2). The patient's epithelium then re-covers the button.

Epikeratoplasty is indicated only for high myopia of a larger range than is indicated for keratomileusis.<sup>30</sup> The surgery decreases the refractive error in almost all eyes, but the predictability, like that of keratomileusis, is poor. Although uncorrected visual acuity is improved in most people after epikeratoplasty, only 59% achieve a refractive error within three dioptres of emmetropia, and about 30% of patients lose some best corrected visual acuity<sup>31</sup> through irregularities of the corneal surface and loss of transparency.

Because the lenticule may be removed, epikeratoplasty has the advantage of being potentially reversible, but it is certainly not an adjustable procedure. Among

the reported complications are failure of the epithelium to recover the lenticule, irregular astigmatism, loss of best corrected visual acuity, secondary microbial infection, overcorrection, and undercorrection.<sup>32</sup>

Clinical studies of epikeratoplasty for myopia showed instability and unpredictability of refraction after operation.<sup>32</sup> Accordingly, the United States Food and Drug Administration classified epikeratoplasty as an investigational device subject to its regulatory laws.<sup>31</sup> Now, except for a few investigators, epikeratoplasty is performed rarely for myopia, and from April 1988 the Food and Drug Administration limited the distribution of lenticules to surgeons who have previous experience with the procedure.

If epikeratoplasty is to gain widespread acceptance as a viable method of correcting myopia a suitable synthetic material must be developed.<sup>33</sup> Synthetic collagen has been used successfully,<sup>34</sup> and research to develop this technique is continuing.

#### INTRACORNEAL LENSES

Intracorneal lenses for treating nearsightedness consist of placing a synthetic lenticule within the corneal stroma to change either the cornea's radius of curvature or its index of refraction. Two synthetic materials are currently under investigation: hydrogel and polysulphone.

The surgical technique for hydrogel intracorneal lens implantation consists of removing an anterior corneal disc with the microkeratome (identical to the keratomileusis technique), placing the lens on the corneal bed, and suturing the resected disc of cornea back into position (fig 3). Hydrogels, because of their high water content, are permeable to water and nutrients, a key requirement for a successful intracorneal lens. Hydrogel intracorneal lenses were developed in 1981 and showed good biocompatibility and reasonable predictability in animals.<sup>35</sup> Clinical trials controlled by the Food and Drug Administration are underway in the United States. Like epikeratoplasty, intracorneal lenses can correct higher refractive errors than can keratomileusis because there is no limit to the thickness of the material used. The major problem is using the microkeratome and cutting across the visual axis, which requires high surgical skill and increases the chance of irregular astigmatism and irreversible damage to the patient's cornea.<sup>36</sup>

Intracorneal lenses made of polysulphone, a material that has a high index of refraction, do not require altering the anterior corneal curvature to alter the refractive status of the eye. Accordingly, using the microkeratome is not necessary and the lenticule can be implanted by placing it in a corneal pocket, a simple surgical technique requiring ordinary manual instruments (fig 4). After initial experience in humans<sup>37</sup> implantation of solid intracorneal lenses was discontinued owing to the occurrence of aseptic necrosis of the cornea in an appreciable number of eyes due to the blockage of the transport of water and nutrients to the anterior cornea.<sup>38</sup> To overcome this problem lenticules with holes less than  $1 \mu\text{m}$  in diameter were developed, and animal studies are now underway.<sup>39</sup>

An intracorneal ring composed of either silicone or polymethylmethacrylate (PMMA) placed within the mid-peripheral corneal stroma increases the volume of the peripheral cornea and flattens the central cornea, reducing myopia (fig 5).<sup>40</sup> The ring can be implanted either after a circular dissection or with the microkeratome. A few patients worldwide have received the intracorneal ring but no clinical data have yet been reported. A similar technique injecting gel in a circular stromal channel is being developed.<sup>41</sup>

All types of intracorneal lenses for the correction of myopia are highly experimental.

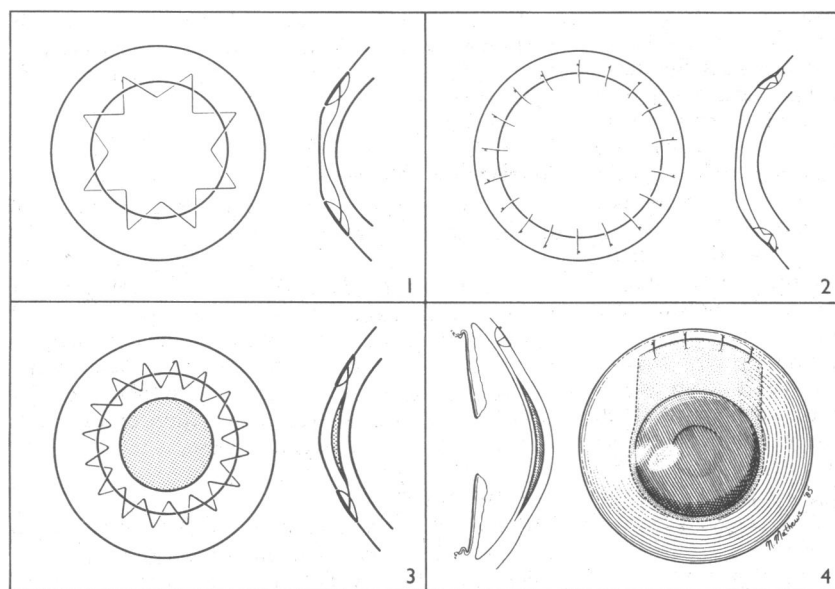


FIG 1—Keratomileusis for myopia. Lamellar disc of patient's cornea is excised with the microkeratome, carved on the cryolathe, and sutured back on the cornea, flattening its central curvature<sup>11</sup> FIG 2—Epikeratoplasty. Lenticule cut from a donor cornea in a flatter curvature is placed on a de-epithelialised cornea of the recipient<sup>11</sup> FIG 3—Hydrogel intracorneal lens. The technique consists of removing an anterior corneal disc with the microkeratome, placing the lens on the corneal bed, and suturing the resected disc of cornea back into position<sup>11</sup> FIG 4—Polysulphone intracorneal lens. The lens is implanted by placing it in a manually dissected corneal pocket<sup>11</sup>

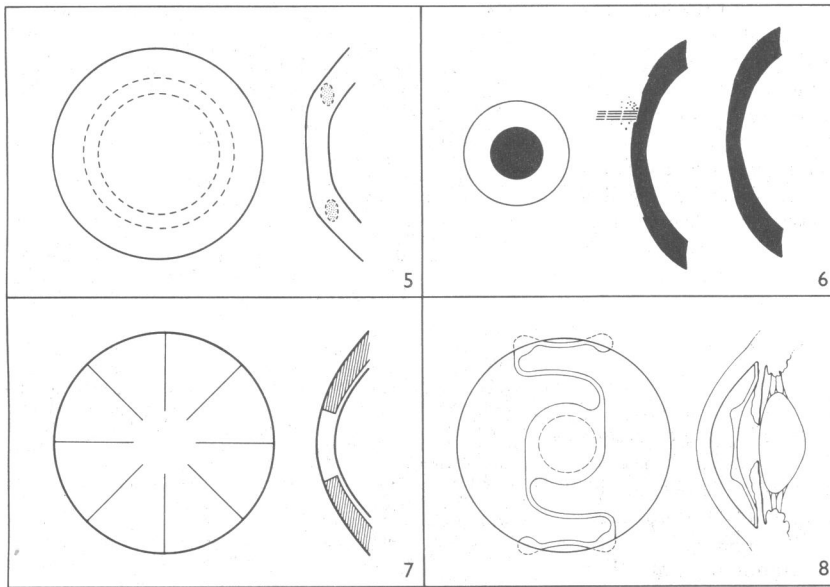


FIG 5—Intracorneal ring. The ring is placed within the mid-peripheral corneal stroma, increasing its volume and flattening the corneal curvature<sup>11</sup> FIG 6—Radial keratotomy. Equally spaced radial incisions made deeply into the peripheral corneal stroma flatten the central corneal curvature and reduce the myopia<sup>11</sup> FIG 7—Photorefractive keratectomy. The optical zone of the cornea is recontoured by ablation with the 193 nm excimer laser; the corneal epithelium covers the ablated zone, which has a reduced optical power, correcting myopia FIG 8—Anterior chamber intraocular lens in a phakic eye.<sup>12</sup>

#### RADIAL KERATOTOMY

In radial keratotomy the cornea is partially incised with a diamond scalpel to flatten it and reduce its refractive power (fig 6). It is the oldest refractive surgical procedure and the one most commonly performed today.

Since 1980 hundreds of thousands of radial keratotomy procedures have been done around the world by thousands of doctors.<sup>42</sup> About 10% of ophthalmologists in the United States perform radial keratotomy, but most surgery is done by only 2-3% of the surgeons. Radial keratotomy was especially popular with doctors in the United States from 1980 to 1984, driven by the promise of helping patients, making large sums of money, and the apparent simplicity of the procedure. The popularity died down when the procedure was found not to be as predictable as initially thought; more artistic individual variation was required, many insurance companies did not pay for the surgery, and the volume of surgery was insufficient to support a practice devoted largely to radial keratotomy.

The surgery is usually done under topical anaesthesia.<sup>42</sup> The older the patient, the greater the refractive effect of the surgery. Most of the effect is achieved by the first four to eight incisions,<sup>43</sup> which must be made to at least 90% of the corneal thickness to induce meaningful amounts of correction. Sometimes transverse incisions to treat astigmatism are made in conjunction with the radial incisions.

Radial keratotomy almost always reduces myopia, but the results are not precisely predictable. The results have improved since the early studies owing to better case selection and surgical technique. Radial keratotomy is most effective for lower amounts of myopia, generally in the range of -1.50 to -6.00 dioptres. In the prospective evaluation of radial keratotomy (PERK) study, five years after surgery 60% of the 757 operated eyes had an uncorrected visual acuity of 20/20 or better, 88% had a visual acuity of 20/40 or better, and 64% were within 1.00 dioptre of emmetropia.<sup>44</sup> More recent series, specifically those using four incisions and calculating the effects of age, have achieved even better results, with up to 91% of the patients within 1.00 dioptre of emmetropia.<sup>43 45</sup>

In general, radial keratotomy is safe procedure. About 3% of eyes will lose two lines or more of best

spectacle corrected visual acuity after the operation, and most of this loss is in the finer ranges of visual acuity, from 20/15 to 20/25.<sup>44</sup> The most common complications are overcorrection and undercorrection. Overcorrections are more difficult and less predictable to treat. Undercorrections can be treated by repeated radial keratotomy (either adding or deepening incisions).<sup>46</sup> Other complications that do not threaten vision include mild irregular astigmatism, glare commonly perceived at night, and vision that fluctuates mildly from morning to evening.<sup>46-48</sup> Complications that disrupt vision, although extremely rare, can occur.<sup>46</sup>

Fluctuation of vision is common for the first three months after radial keratotomy and continues for many years as a small morning to evening change that is bothersome for some patients. Long term stability is usually achieved by three months after surgery, and about 80% of eyes remain stable thereafter.<sup>49</sup> In about one in five eyes, however, a continued effect of the surgery sometimes termed progressive hyperopia is experienced—the refraction moves toward hyperopia or farsightedness.<sup>44</sup> What proportion of the population will have this and how long it will last is unknown, but progressive hyperopia could become a major complication of radial keratotomy if most patients become hyperopic over time.

#### PHOTOREFRACTIVE KERATECTOMY

Excimer lasers emit ultraviolet wavelengths with high photon energy capable of breaking intermolecular bonds within proteins and other macromolecules without causing significant thermal damage to adjacent structures.<sup>50</sup> They can remove submicrometre amounts of tissue from the anterior corneal surface, alter its anterior radius of curvature, and yield a very precise refractive change.<sup>50</sup> This procedure is called photorefractive keratectomy (fig 7). Excimer lasers have been used in industry since the 1970s and were first introduced for ophthalmic surgery by Trokel in 1983.<sup>19</sup> Because of remarkable experimental results—precise and smooth corneal surfaces could be cut—they proceeded to large scale clinical trials in human eyes.<sup>51 52</sup>

The procedure is technically very simple. The epithelium is removed from the central cornea and the laser is activated, delivering a series of a few hundred pulses to a 4-5 mm central ablation zone over 20-60 seconds. For the correction of myopia, the central cornea is ablated most deeply, shallowing as the edge of the ablation zone is reached.<sup>53</sup>

Early experimental studies showed that even though the procedure was technically very precise, early refractive results were not as predictable as expected owing to epithelial and stromal wound healing after the laser ablation.<sup>54</sup> Epithelial wound healing tends to fill in the ablated defect in the superficial cornea by hyperplasia, but if the ablation curves can be made smooth enough the epithelium may not undergo this thickening with the consequent reduction of refractive effect.<sup>55</sup> Subepithelial deposition of new extracellular matrix occurs after all excimer laser procedures, and this may also cause thickening of the ablated area, causing the shape of the cornea to return towards its original curvature and decreasing the refractive effect. This healing response is also responsible for the haze or clouding of the cornea observed postoperatively in a large percentage of treated eyes.<sup>54 56</sup> Experimental studies showed that postoperative topical steroids may reduce new subepithelial collagen deposition in rabbits,<sup>57</sup> and clinical studies suggest that giving topical steroids may reduce postoperative haze in the cornea.

FDA phase III clinical trials on 700 normally sighted eyes are now underway at several centres in the United States. Clinical results from phase IIB (100 normally sighted eyes) and from centres outside the United



States show that the excimer laser has a predictability similar to that observed after radial keratotomy.<sup>51 52</sup> After one year 92% of the treated eyes were within 1.00 dioptre of the intended refraction, and none of the patients lost or gained more than one line of spectacle corrected visual acuity.<sup>51</sup>

Because of the great commercial interest, considerable publicity and exaggeration are surrounding this new procedure, as occurred with radial keratotomy. Whether or not the early claims will be borne out with more careful long term clinical studies remains to be seen.

### Intraocular lens implants

Intraocular lens implantation is a type of refractive surgery that involves not the cornea but the crystalline lens. It occurs in two contexts, after cataract surgery and with the implantation of lenses in the anterior chamber in phakic eyes (eyes with their natural lens).

Cataract surgery, the most common ophthalmic surgical procedure, removes the opaque (cataractous) crystalline lens and replaces it with a clear plastic intraocular implant of an adequate power to correct the patient's refractive error. Intraocular lenses are used in over 95% of routine cataract operations in developed countries and make thick glasses or contact lenses unnecessary.

Implanting an intraocular lens in the anterior chamber of the eye to correct naturally occurring myopia in patients who have a normal lens (fig 8) was proposed by Strampelli in 1954.<sup>58</sup> Joaquin Barraquer in Spain, during the 1950s, had much experience with these lenses<sup>59</sup> but abandoned the idea because of adverse results.<sup>60</sup> The main problem with these implants is the trauma to the corneal endothelium, the delicate single cell inner layer that is responsible for corneal deturgescence and clarity. Damage to the endothelium is irreversible and may result in corneal oedema and opacification.

Interest in these implants was revived recently by modified lens designs that may better preserve the endothelium.<sup>61 62</sup> Even with the new designs, however, the high vault and prominent edge of the optic may produce corneal endothelial damage in some eyes.<sup>63</sup>

The concept of the phakic intraocular implant for myopia remains an exciting one: the technique is simple and cheap, there is an unlimited supply of lenses, and the procedure avoids the surgical manipulation of the corneal stroma and the subsequent scarring and loss of visual acuity. Some essential problems remain, such as damage to the corneal endothelium, damage to the crystalline lens causing cataract, and damage to the anterior chamber angle causing intraocular pressure rise and glaucoma.

### Posterior scleral support

There are a few reports, especially from Russian and eastern European centres, describing surgical techniques aiming at reinforcing the sclera and preventing the progression of high myopia. These techniques include the use of plastic materials,<sup>64</sup> collagen sponge,<sup>65</sup> and fascia lata implants.<sup>66</sup> Even though the scientific basis of these procedures is not entirely clear, their effectiveness is explained by improved blood circulation in the scleral coat of the eye.<sup>67</sup> Satisfactory results, avoiding the progression of high myopia and its complications, have been reported by some authors, but most studies have not included controls and longer follow up is needed.<sup>68</sup>

SJB is supported in part by CNPq-Brazilian government (grant No 203024/90-7).

- Jensen H. Myopia progression in young school children. A prospective study of myopia progression and the effect of a trial with bifocal lenses and beta blocker eye drops. *Acta Ophthalmol* 1991;69(suppl 200):1-79.
- Sperduto RD, Seigel D, Roberts J, Rowland M. Prevalence of myopia in the United States. *Arch Ophthalmol* 1983;101:405-7.
- Sveinsson K. The refractions of Icelanders. *Acta Ophthalmol* 1982;60:779-87.
- Lin L-L-K, Hung L-F, Shih Y-F, Hung P-T, Ko L-S. Correlation of optical components with ocular refraction among teenagers in Taipei. *Acta Ophthalmol* 1988;185(suppl):69-73.
- Curtin BJ. *The myopias: basic science and clinical management*. Philadelphia: Harper and Row, 1985:3-11.
- Woo GC, Wilson MA. Current methods of treating and preventing myopia. *Optom Vis Sci* 1990;67:719-27.
- Polse KA, Brand RJ, Vastine DW, Schwalbe JS. Corneal change accompanying orthokeratology. *Arch Ophthalmol* 1983;101:1873-8.
- Bedrossian RH. The effect of atropine on myopia. *Ophthalmology* 1979;86:713-7.
- Pärssinen O, Hemminki E, Klemetti A. Effect of spectacle use and accommodation on myopic progression: final results of a three-year randomized clinical trial among schoolchildren. *Br J Ophthalmol* 1989;73:547-51.
- Bourque LB, Rubenstein R, Cosand BB, Waring GO, Moffitt S, Gelender H, et al. Psychosocial characteristics of candidates for the prospective evaluation of radial keratotomy (PERK) study. *Arch Ophthalmol* 1984;102:1187-92.
- Waring GO III. Making sense of "keratospark." A classification of refractive corneal surgery. *Arch Ophthalmol* 1985;103:1472-7.
- Trevor-Roper P. The treatment of myopia. *BMJ* 1983;287:1822-3.
- Bates WH. A suggestion of an operation to correct astigmatism. *Arch Ophthalmol* 1894;23:9-13.
- Lans LJ. Experimentelle Untersuchungen über Entstehung von Astigmatismus durch nicht-perforierende Cornea Wunden. *Albrecht von Graefes Arch Klin Exp* 1898;45:117-52.
- Barraquer JI. Basis of refractive keratoplasty. *An Med Espec* 1965;51:66-82.
- Sato T, Akiyama K, Shibata H. A new surgical approach to myopia. *Am J Ophthalmol* 1953;36:823-9.
- Fyodorov SN, Durnev V. Operation of dosaged dissection of corneal circular ligament in cases of myopia of mild degree. *Ann Ophthalmol* 1979;11:1885-90.
- Werblin TP, Klyce SD. Epikeratophakia: the surgical correction of aphakia. I. Lathing of corneal tissue. *Curr Eye Res* 1981;1:123-9.
- Trokel SL, Srinivasan R, Braren B. Excimer laser surgery of the cornea. *Am J Ophthalmol* 1983;96:710-5.
- Barraquer JI. Quereromileusis para la correccion de la miopia. *Arch Soc Am Ophthalmol Optom* 1964;5:27-48.
- Barraquer JI. Keratomileusis for myopia and aphakia. *Ophthalmology* 1981;88:701-8.
- Krumeich JH, Swinger CA. Non-freeze epikeratophakia for the correction of myopia. *Am J Ophthalmol* 1987;103:397-403.
- Nordan LT. Keratomileusis. *Int Ophthalmol Clin* 1991;31:7-13.
- Swinger CA, Barker BA. Prospective evaluation of myopic keratomileusis. *Ophthalmology* 1984;91:785-92.
- Dossi F, Bosio P. Myopic keratomileusis: results with a follow-up over one year. *J Cataract Refract Surg* 1987;13:417-20.
- Swinger CA, Barraquer JI. Keratophakia and keratomileusis—clinical results. *Ophthalmology* 1981;88:709-15.
- Arenas-Archila E, Sanchez-Thorin JC, Noranjo-Urbe JP, Hernandez-Lozano A. Myopic keratomileusis in situ: a preliminary report. *J Cataract Refract Surg* 1991;17:424-35.
- Nordan LT, Fallor MK. Myopic keratomileusis: 74 consecutive non-amblyopic cases with one year of follow-up. *J Refract Surg* 1986;2:124-8.
- Kaufman HE. The correction of aphakia. *Am J Ophthalmol* 1980;89:1-10.
- McDonald MD, Klyce SD, Suarez E, Kandarakis A, Friedlander M, Kaufman HE. Epikeratophakia for myopia correction. *Ophthalmology* 1985;92:1417-22.
- Ophthalmic Procedures Assessment—Epikeratoplasty—American Academy of Ophthalmology. *Ophthalmology* 1990;97:1225-32.
- McDonald MB, Kaufman HE, Aquavella JV, Durrie DS, Hiles DA, Hunkeler JD, et al. The nationwide study of epikeratophakia for myopia. *Am J Ophthalmol* 1987;103:375-83.
- McDonald MB. The future direction of refractive surgery. *J Refract Surg* 1988;4:158-68.
- Thompson KP, Hanna KD, Gipson RK, Gravagna P, Waring GO, Johnson-Wint B. Synthetic epikeratoplasty in rhesus monkeys with human type IV collagen. *Cornea* (in press).
- McCarey BE, Andrews DM. Refractive keratoplasty with intrastromal hydrogel lenticular implants. *Invest Ophthalmol Vis Sci* 1981;22:107-15.
- Werblin TP, Peiffer RL, Patel AS. Synthetic keratophakia for the correction of aphakia. *Ophthalmology* 1987;94:926-34.
- Choyce DP. Semi-rigid corneal inlays used in the management of albinism, aniridia and ametropia. *Ophthalmology* 1982;89(suppl):55.
- Kirkness CM, Steele ADM, Garner A. Polysulfone corneal inlays. Adverse reactions: a preliminary report. *Trans Ophthalmol Soc UK* 1985;104:343-50.
- Lane SS, Cameron JD, Holland E, Mindrup E, McMichael W, Lindstrom R. Fenestrated intracorneal lenses—update and a model for the evaluation of optical resolution. *Invest Ophthalmol Vis Sci* 1991;32(suppl):921.
- Fleming JF, Reynolds AE, Kilmer L, Burris TE, Abbott RL, Schanzlin DJ. The intrastromal corneal ring: two cases in rabbits. *J Refract Surg* 1987;3:227-32.
- Simon G, Kervick GN, Parel J-M, Davis P. In vivo evaluation of gel injection adjustable keratoplasty (GIAK). *Invest Ophthalmol Vis Sci* 1991;32(suppl):921.
- Waring GO III. *Refractive keratotomy for myopia and astigmatism*. St Louis: Mosby Year Book, 1985.
- Salz JJ, Salz JM, Salz M, Jones D. Ten years experience with a conservative approach to radial keratotomy. *Refract Corneal Surg* 1991;7:12-22.
- Waring GO III, Lynn MJ, Nizam A, Kutner MH, Cowden JW, Culbertson W, et al. Results of the prospective evaluation of radial keratotomy (PERK) study five years after surgery. *Ophthalmology* 1991;98:1164-76.
- Spigelman AV, Williams PA, Lindstrom RL. Further studies of four incision radial keratotomy. *Refract Corneal Surg* 1989;5:292-5.
- Rashid ER, Waring GO III. Complications of radial and transverse keratotomy. *Surv Ophthalmol* 1989;34:73-106.
- McDonnell PJ, Caroline PJ, Salz JJ. Irregular astigmatism after radial and astigmatic keratotomy. *Am J Ophthalmol* 1989;107:42-6.
- MacRae S, Rich L, Phillips D, Bedrossian R. Diurnal variation in vision after radial keratotomy. *Am J Ophthalmol* 1989;107:262-7.

- 49 Waring GO III, Lynn MJ, Strahman ER, Kutner MH, Culbertson W, Laibson P, *et al.* Stability of refraction during four years after radial keratotomy in the prospective evaluation of radial keratotomy study. *Am J Ophthalmol* 1991;111:133-44.
- 50 Krauss JM, Puliafito CA, Steinert RF. Laser interactions with the cornea. *Surv Ophthalmol* 1986;1:37-53.
- 51 Seiler T, Wollensak J. Myopic photorefractive keratectomy with the excimer laser. One year follow-up. *Ophthalmology* 1991;98:1156-63.
- 52 McDonald MB, Liu JC, Byrd TJ, Abdelmegeed M, Andrade HA, Klyce SD, *et al.* Central photorefractive keratectomy for myopia. Partially sighted and normally sighted eyes. *Ophthalmology* 1991;98:1327-37.
- 53 Seiler T. Laser corneal surgery. In: Waring GO III, ed. *Refractive keratotomy for myopia and astigmatism*. St Louis: Mosby Year Book, 1992.
- 54 McDonald MB, Frantz JM, Klyce SD, Salmeron B, Beuerman RW, Munnerlyn CR, *et al.* One-year refractive results of central photorefractive keratectomy for myopia in the nonhuman primate cornea. *Arch Ophthalmol* 1990;108:40-7.
- 55 Fantes FE, Hanna KH, Waring GO III, Pouliquen Y, Thompson KP, Savoldelli M. Wound healing after excimer laser keratomileusis (photorefractive keratectomy) in monkeys. *Arch Ophthalmol* 1990;108:665-75.
- 56 Hanna KD, Pouliquen Y, Waring GO III, Savoldelli M, Cotter J, Morton K, *et al.* Corneal stromal healing in rabbits after 193 nm excimer laser surface ablation. *Arch Ophthalmol* 1989;107:895-901.
- 57 Tuft SJ, Zabel RW, Marshall J. Corneal repair following keratectomy. *Invest Ophthalmol Vis Sci* 1989;30:1769-77.
- 58 Strampelli B. Sopportabilità di lenti acriliche in camera anteriore nella afachia e nei vizi di refrazione. *Annali di Ottalmologia e Clinica Oculistica* 1954;80:75-82.
- 59 Barroquer J. Anterior plastic lenses. Results of and conclusions from five years experience. *Trans Ophthalmol Soc UK* 1959;79:393-424.
- 60 Waring GO III. Phakic intraocular lenses for the correction of myopia—where do we go from here? *Refractive and Corneal Surgery* 1991;7:275-6.
- 61 Baikoff G, Joly P. Comparison of minus power anterior chamber lenses and myopic epikeratoplasty in phakic eyes. *Refractive and Corneal Surgery* 1990;6:252-60.
- 62 Worst JGF, Veen GVD, Los LI. Refractive surgery for high myopia. The Worst-Fechner biconcave iris claw lens. *Doc Ophthalmol* 1990;75:335-41.
- 63 Mimouni F, Colin J, Koffi V, Bonnet P. Damage to the corneal endothelium from anterior chamber intraocular lenses in phakic myopic eyes. *Refract Corneal Surg* 1991;7:277-81.
- 64 Kovalevskii EI, Dubovskaia LA, Kotiasheva GI, Sotnikova TA, Mishustin AV. The surgical prophylaxis stage in the progression of myopia in children. *Oftalmol Zh* 1989;4:199-202.
- 65 Svirin AV, Antipova OA, Milovanova ZP. Collagen plastic surgery in progressive myopia. *Vestn Oftalmol* 1989;105:20-5.
- 66 Alberth B, Nagy Z, Berta A. Combined surgical procedure for the prevention of blindness caused by progressive high myopia. *Acta Chir Hung* 1988;29:3-13.
- 67 Golychev VN, Morozova IV. A combination of scleroplasty with intrascleral revascularization in myopia. *Oftalmol Zh* 1989;3:160-2.
- 68 Tarutta EP, Shamkhalova ES, Valskii VV. An analysis of the late results of scleroplasty in progressive myopia. *Oftalmol Zh* 1989;4:204-7.

(Accepted 20 May 1992)

## US health care. I: The access problem

Jennifer Dixon

*The crisis in health care is looming large in the presidential campaign in the United States, which is now approaching its climax. This is the first of three articles analysing the profound problems and proposed solutions*

The "issue from hell" and the "lose-lose issue" are how health care in the United States has been described over the past year. After two decades of crisis the American health system represents a policy problem which, despite much impressive analysis, refuses to be solved. The twin problems of increasing costs and decreasing access have prompted a myriad of proposals for health care reform to which President Bush recently added his own. But its staying power as a domestic problem reflects the fact that reform of American health care is a complex political issue, not simply a technical one. This year's presidential election provides an opportunity for politicians to come up with a reform strategy which offers more than the "look concerned but do nothing" policy of the current administration.

This series of three articles examines why reform is necessary and what form it should take. Part I examines access to health care and changes over recent years. Part II considers the costs of American health care and the impact of key cost containment strategies. Part III looks at the proposals on offer and the likely course of health care reform.

### Access

It is a stark fact that access to health care in the United States is rationed by ability to pay. In 1990, although 83% of all non-elderly Americans (those under 65) were covered by some form of health insurance, some 16.6%—that is, 35.7 million people—had none at all (see table I).<sup>1</sup> Though uninsured people face the most difficulty obtaining care, access is a growing problem for all Americans. This paper examines why access is such a concern for three groups—namely, people without health insurance, those with public insurance through the Medicare and Medicaid programmes, and those covered by private health insurance. The paper also examines federal initiatives to expand access.

### Uninsured people

Without insurance to cushion the costs of care uninsured people face steep bills for health services. As

TABLE I—Non-elderly and elderly Americans with selected sources of health insurance coverage in 1990

Source of coverage	Non-elderly No (millions) (%)	Elderly No (millions) (%)
Total population	215.9 (100)	30.1 (100)
Total with private health insurance	158.3 (73)	20.6 (68)
Employer coverage	138.7 (64)	10.0 (33)
Other private coverage	19.7 (9)	10.6 (35)
Total with public health insurance	29.2 (14)	28.9 (96)
Medicare	3.5 (2)	28.8 (96)
Medicaid	21.6 (10)	2.6 (9)
CHAMPUS/CHAMPVA*	5.9 (3)	1.1 (4)
No health insurance	35.7 (17)	0.3 (1)

Source: Employee Benefit Research Institute.<sup>1</sup>

Figures may not add to totals because individuals may receive coverage from more than one source.

\*Includes Civilian Health and Medical Program for the Uniformed Services and Civilian Health and Medical Program for the Department of Veterans' Affairs.

a result they delay or avoid seeking care<sup>2</sup> and tend to use a patchy network of health services that are free or cheap—mainly hospital emergency rooms, outpatient clinics, and publicly funded health centres. However, in recent years hospital emergency rooms have become more crowded<sup>3</sup> and public health centres have become scarcer,<sup>4,5</sup> as have the primary care physicians to work in them.<sup>6</sup> Since hospitals and physicians must foot the bill when uninsured people can't or won't pay for their health care, providers have taken steps to reduce their financial risk. Some hospitals have cut back on services uninsured patients use the most (such as emergency room, outpatient, and obstetric care) or relocated out of neighbourhoods where they tend to seek care.<sup>7</sup> Outside hospitals private physicians can and do refuse to treat uninsured people rather than risk picking up the bill. The lack of access to even basic preventive care has contributed to the current epidemic of preventable childhood infectious disease<sup>8</sup> and the high infant mortality that persists in the United States.<sup>9</sup>

Not surprisingly, Americans with no health insurance use fewer health services than Americans who have insurance. Studies show that uninsured people receive less ambulatory and inpatient care,<sup>10,11</sup> and utilisation differences persist even after adjusting for race, geographic location, and health status.<sup>12</sup> Once

**Health Services  
Research Unit, London  
School of Hygiene and  
Tropical Medicine,  
London WC1E 7HT**  
Jennifer Dixon, honorary  
lecturer in public health  
medicine

BMJ 1992;305:817-9