

occurrence of at least one symptom, the relative risk of symptoms adjusted for age and sex being significantly increased in bathers (1.31; 95% confidence interval 1.04 to 1.64). Risk increased with degree of exposure, rising from 1.25 (0.96 to 1.62) in waders to 1.31 (0.98 to 1.75) in swimmers to 1.81 (1.09 to 2.99) in surfers or divers, indicating a dose-response relation (table).

Bathers experienced significantly more gastrointestinal illness than non-bathers (relative risk 1.47,

Relative risk of reported symptoms adjusted for age and sex according to bathing in sea water, Ramsgate, August 1990

	No (%) reporting symptoms	Relative risk (95% confidence interval)
<i>At least one reported symptom</i>		
Non-bathers (n=839)	180 (21.5)	1.00
Bathers (n=1044)	275 (26.3)	1.31 (1.04 to 1.64)
Waders (n=561)	142 (25.3)	1.25 (0.96 to 1.62)
Swimmers (n=399)	105 (26.3)	1.31 (0.98 to 1.75)
Surfers or divers (n=84)	28 (33.3)	1.81 (1.09 to 2.99)
<i>Gastrointestinal symptoms (including diarrhoea)</i>		
Non-bathers (n=839)	68 (8.1)	1.00
Bathers (n=1044)	116 (11.1)	1.47 (1.06 to 2.04)
<i>Diarrhoea</i>		
Non-bathers (n=839)	30 (3.6)	1.00
Bathers (n=1044)	61 (5.8)	1.88 (1.18 to 2.99)
<i>Eye symptoms</i>		
Non-bathers (n=839)	41 (4.9)	1.00
Bathers (n=1044)	62 (5.9)	1.24 (0.81 to 1.90)
<i>Ear, nose, and throat symptoms</i>		
Non-bathers (n=839)	110 (13.1)	1.00
Bathers (n=1044)	148 (14.2)	1.08 (0.82 to 1.43)
<i>Respiratory symptoms</i>		
Non-bathers (n=839)	47 (5.6)	1.00
Bathers (n=1044)	77 (7.4)	1.40 (0.94 to 2.07)

95% confidence interval 1.06 to 2.04); in particular, the risk of diarrhoea was almost doubled (relative risk 1.88, 1.18 to 2.99). Relative risks were raised also for eye; ear, nose, and throat; and respiratory symptoms, although they did not reach significance. Surfers or divers had a significantly increased risk of eye (relative risk 2.65, 1.22 to 5.75) and respiratory (relative risk 2.85, 1.38 to 5.87) symptoms. Risks were highest among 15-24 year olds. No significant differences were apparent between residents and visitors. The detailed findings are reported elsewhere.⁴

Water quality varied appreciably day by day, and the beach failed the European Commission's mandatory standard for thermotolerant coliforms on 12% of sampling occasions. The association between the microbiological quality of the water daily and reported symptoms is best investigated in day trippers, but their numbers were insufficient for analysis.

Comment

We showed an increased and dose related risk of self reported illness from bathing in sea water, findings consistent with those of the first phase study at Langland Bay.⁵ These studies confirm that the study design used by the United States Environmental Protection Agency, endorsed by the World Health Organisation and the United Nations environment programme, and developed further by us is suitable for application in the United Kingdom. The noteworthy difference between our findings for Ramsgate and those for Langland Bay is the significant association between bathing and gastrointestinal symptoms observed at Ramsgate, where the sea water contains higher levels of faecal pollution.

The increased risk associated with sea bathing needs careful verification in terms of bacterial indicators of water quality, by examining the relation between these indicators and illness daily. We have performed a larger study this summer, encompassing several beaches of varying quality, to determine more precisely the incidence of illness against bacterial indicators of quality of sea water.

- 1 Eykin SJ. Health hazards from British beaches? *BMJ* 1988;296:1484.
- 2 Commission of the European Communities. Council directive of 8 December 1975 concerning the quality of bathing water (76/160/EEC). *Official Journal of the European Communities* 5 Feb 1976. (L31/1.)
- 3 House of Commons Environment Committee. *Pollution of beaches. Fourth report.* London: HMSO, 1990.
- 4 Epidemiology and Public Health Research Unit. *Health risks associated with bathing in the sea: results of a study in Ramsgate.* Guildford: University of Surrey, 1990.
- 5 Epidemiology and Public Health Research Unit. *Health risks associated with bathing in the sea: results of a pilot study in Langland Bay.* Guildford: University of Surrey, 1990.

(Accepted 23 July 1991)

Effect of high dose steroid bolus on occlusion of ocular central artery: angiographic study

N Hausmann, G Richard

Department of
Ophthalmology,
Landeskrankenhaus
Feldkirch, A-6807 Austria
N Hausmann, MD, assistant
director

Department of
Ophthalmology, University
of Mainz, D-6500 Mainz,
Germany
G Richard, MD, professor of
ophthalmology

Correspondence to:
Dr Hausmann.

BMJ 1991;303:1445-6

Occlusion of the ocular central artery generally leads to permanent blindness after 105 minutes.¹ It may be caused by endothelial oedema,² so quick recanalisation may be possible with steroid treatment. We report four cases of acute occlusion of the ocular central artery in which a bolus of high dose steroid was injected intravenously and its effect on the retina examined by fluorescein angiography.³

Patients, methods, and results

The four patients studied were the only ones to have been admitted to our hospital in the past 15 years in the early stages of ocular central artery occlusion. All were women (ages 42, 48, 51, and 69) and all reported a sudden, one sided blindness during the 1½ to 2 hours before admission. The only ophthalmopathological sign was an amaurotic fixed pupil. After fluorescein

angiography had shown occlusion of the ocular central artery in all four cases (figure, c and d) intraocular pressure was reduced by giving acetazolamide 500 mg intravenously and performing anterior chamber puncture. (Lower intraocular pressure facilitates the inflow of blood into the eye⁴ and either retinal circulation is reinstated and the patient regains vision or the patient remains blind.) Thirty minutes later none of our patients had regained retinal circulation or subjective visual improvement.

We then administered 1000 mg undiluted prednisolone intravenously as a bolus. Ten to 15 minutes after the injection all the patients recognised contours and described their visual field as a "cracked mirror." In a second angiogram (60 minutes after steroid injection), three patients had a functioning retinal circulation with nearly normal circulation times (figure, e and f). In the eldest patient circulation was reduced and circulation times prolonged fivefold. To protect the recanalised ocular vascular system 250 ml plasma expander was infused on the second, fourth, and sixth day after treatment. Thereafter all patients but the eldest patient started taking heparin followed by nicoumalone, and their final visual acuity during five years of follow up was between 0.05 and 0.15. Perimetry showed a persistent central scotoma of about 5° in the three younger patients, which suggests permanent macular

damage, the macula being the most vulnerable retinal area (recanalisation of the ocular vascular system had occurred more than 105 minutes after occlusion in all patients). Reocclusion occurred in only the eldest patient, who was not given anticoagulation treatment, after 10 days and resulted in amaurosis.

General examinations of all patients detected no arrhythmias, carotid stenoses, or embolic disorders.

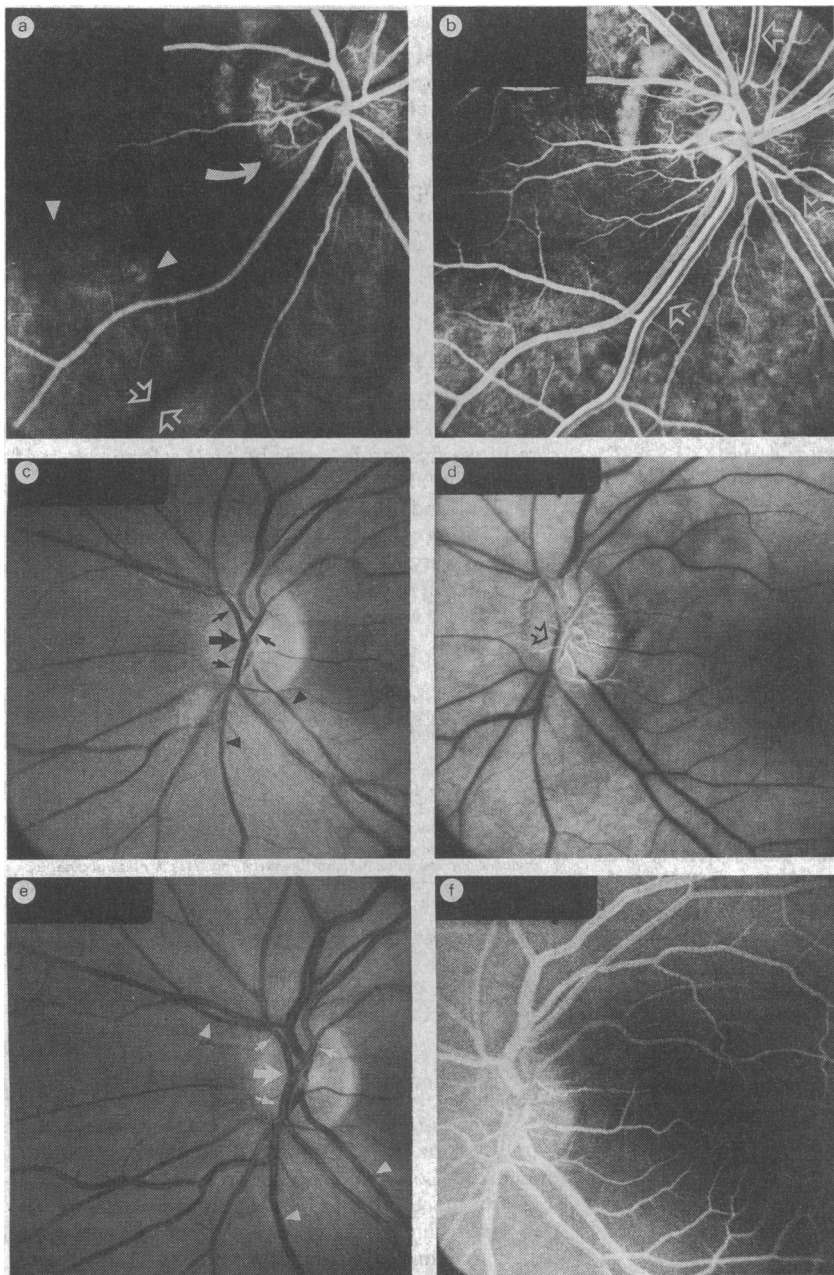
Severe hypertension was found in only the eldest patient, which implies that atherosclerotic changes in the wall of the ocular central artery were more likely than endothelial oedema to have been causal factors in this case.

Comment

After several hours of ischaemia due to an occlusion fluorescein escapes from the occluded retinal arteries despite the so called blood-retina barrier, which is normally impenetrable to it. This means that the first line of defence, the endothelial cell, is not functioning normally. The primary cause of this dysfunction is the cell's oedema.

The angiographically documented recirculation in our patients was attributable to the single intravenous bolus of high dose steroid. Given the time course of blindness in acute occlusion (105 minutes),¹ plasma expander and anticoagulant treatment (days later) would have been too late. Steroids are always the fastest working substances in oedemas of other organs, such as the brain.⁵ However, to our knowledge, angiographic evidence of the immediate efficacy of steroids on vessel walls has not been documented. As our patients showed angiographically complete recirculation in the eye so quickly after steroid application, their occlusions were probably due to vasospasm with consecutive ischaemic endothelial oedema rather than atherosclerosis, particularly in the younger patients.

A steroid bolus seems to be a suitable emergency treatment. Steroids do not interfere with any drugs that might be given for this condition. Possible side effects compared with other treatments—for example, lysis—are negligible. The possibility of giving other treatments simultaneously is also not ruled out: in other words, even lysis could be started immediately after admission.



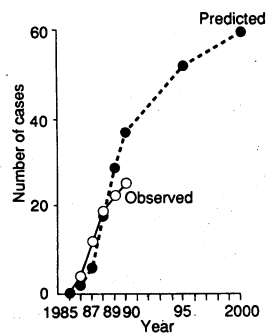
(a) Normal fluorescein angiogram 0-56 s after first appearance of fluorescein on optic disc (arterial circulation time).³ Capillaries on optic disc (thick arrow) are stained from ciliary vessel system; choroid is patchily fluorescent (arrowheads); and veins (open arrows) are still dark and unfilled. (b) Normal fluorescein angiogram 7-8 s after first appearance of fluorescein on optic disc (late venous circulation time).³ Venous system (open arrows) is completely filled up to disc's edge. (c) Red free photograph of left fundus (case 2, age 48) 1½ hours after ocular central artery occlusion (thick arrow). Main arterial branches (small arrows) as well as veins (arrowheads) appear thinned owing to missing circulation. (Whether blood is flowing in vessels cannot be proved ophthalmoscopically). (d) Fluorescein angiogram (case 2) 120 s after fluorescein injection. Bright background indicates complete choroidal filling, bright disc good filling by ciliary vessels. Ocular central artery and its main branches (arrow) show only laminar flow due to passive coloration of plasma—corporeal movement in centre of arteries cannot be proved. Laminar flow can be seen only in disc area. There is definite proof of occlusion. (e) Red free photograph (case 2) 60 minutes after intravenous steroid bolus injection. Ocular central artery (thick arrow) and its branches (small arrows), as well as the veins (arrowheads) appear thicker owing to reinstated circulation. Compare their calibre with that in (c). (f) Fluorescein angiogram (case 2) 60 minutes after intravenous steroid bolus injection. Late venous circulation time of 10 s is nearly normal (b). Arterial and venous systems are completely filled with fluorescein

- 1 Hayreh SS, Weingeist TA. Experimental occlusion of the central artery of the retina. IV. Retinal tolerance time to acute ischaemia. *Br J Ophthalmol* 1980;64:818-25.
- 2 Neubauer H, Karges E. Corticosteroids in the treatment of disturbances of the retinal arterial blood supply. *Klin Monatsbl Augenheilkd* 1962;141:70-93.
- 3 Richard G. *Fluoreszenzangiographie. Atlas und Lehrbuch*. Stuttgart: Thieme, 1989:19-21.
- 4 Magargal LE, Goldberg RE. Anterior chamber paracentesis in the management of acute nonarteritic central retinal artery occlusion. *Surgery Forum* 1977;28:518-21.
- 5 Braugher JM, Hall ED. Current application of "high-dose" steroid therapy for CNS injury. *J Neurosurg* 1985;62:805-10.

(Accepted 4 July 1991)

Correction

Progression of HIV disease in a haemophilic cohort followed for 11 years and the effect of treatment



Owing to an editorial error figure 2 in this paper by Dr Christine A Lee and others (2 November, p 1093) was incorrect. The correct figure is reproduced here.