

### Discussion

There has been an increase recently in the use of L.S.D. in this country on a casual basis and not under medical supervision. Use in this way as a "mind-expanding" drug has been extensively discussed in the press and on television, and has been advocated in non-medical journals. After a similar interest in the non-medical uses of the drug and extensive self-medication by fringe groups in New York there was a sudden upsurge of admissions to Bellevue Hospital with acute reactions from its use (Frosch *et al.*, 1965). These fell into three groups: (1) acute panic reactions; (2) recurrence of symptoms while abstaining from the drug, which was more likely to occur after multiple ingestion; and (3) prolonged psychosis.

Cases 1, 2, and 5 reported here appeared to be acute panic reactions, and Cases 3 and 4 a recurrence of symptoms in a period of abstinence. Case 4 also showed signs of a prolonged psychosis. Case 6 may have been due to disordered judgement or a psychotic reaction. Prolonged adverse reactions, including chronic hallucinatory states, also occur (Rosenthal, 1964). Owing to the fashion of using sugar cubes as a vehicle for black market L.S.D. it can also be taken accidentally—for example, by children—and three such cases have been reported. One of these sustained a dissociative state, accompanied by anxiety and visual illusions, that lasted for several weeks (Cohen, 1966). Cases 5 and 6 show the need to look for L.S.D. and amphetamines at necropsy in deaths of this type, lest some be wrongly attributed to suicide.

Despite the statements of the protagonists of the use of this drug that it is safe, L.S.D. can be dangerous when taken casually—for example, when not taken by selected patients under strict medical supervision and with the use of proper safeguards. The incidence of adverse effects associated with controlled use of the drug by physicians suggested that in medical hands it was an exceptionally safe drug (Levine and Ludwig, 1964).

### Summary

Recently there has been an increase in the use of lysergide (lysergic acid diethylamide; L.S.D.) obtained illicitly. Adverse reactions are not uncommon, and six (two fatal) cases are reported.

I am grateful to Professor F. E. Camps, Dr. A. Robinson, and Mr. F. F. Haddock for help with information about some of these cases.

### REFERENCES

- Cohen, S. (1966). *Psychosomatics*, 7, 182.  
 — and Ditman, K. S. (1962). *J. Amer. med. Ass.*, 181, 161.  
 — (1963). *Arch. gen. Psychiat.*, 8, 475.  
 Frosch, W. A., Robbins, E. S., and Stern, M. (1965). *New Engl. J. Med.*, 273, 1235.  
 Levine, J., and Ludwig, A. M. (1964). *Comprehens. Psychiat.*, 5, 314.  
 Ludwig, A. M., and Levine, J. (1965). *J. Amer. med. Ass.*, 191, 92.  
 Rosenthal, S. H. (1964). *Amer. J. Psychiat.*, 121, 238.

## Preliminary Communications

### Trephine Biopsy for Diffuse Lung Lesions

*Brit. med. J.*, 1967, 3, 30–32

Drill biopsy of various tissues by means of a dental drill and cylindrical rotating cutting needle was described by Kirschner (1935). The technique was modified by Christiansen (1940) and further results with this method were reported by Ellis (1947). A high-speed pneumatic drill was used by Deeley (1960). Within the thorax, these authors confined themselves to the diagnosis of peripheral tumours adherent or adjacent to the chest wall, and, despite the theoretical advantages of the procedure over other methods of lung biopsy, interest in it has lapsed because of this limited application. It is our purpose to show how high-speed drill biopsy can be extended to the diagnosis of diffuse pulmonary conditions.

The extremely fast cutting edge provided by the air-drill was found to be effective in obtaining specimens from the lung at necropsy, but the small trephine described by Deeley failed to provide adequate specimens of diffuse lesions from inflated lung. To overcome this difficulty a large trephine with special features was designed by one of us (S. J. S.) and proved successful experimentally and in practice.

#### INDICATIONS

Indications include diffuse and localized lesions of the lung or pleura where a definitive diagnosis is required for the purpose of treatment, prognosis, or a claim for industrial compensation.

There are no specific contraindications other than bullae, cysts, or aneurysms, but it is wise to avoid patients with a

bleeding diathesis or insufficient respiratory reserve to risk a pneumothorax. Some upper-lobe lesions may prove inaccessible and those adjacent to the mediastinum are best avoided.

#### METHOD

The apparatus consists of a small Desoutter pneumatic drill easily held in the hand and driven by compressed air from a cylinder fitted with a reducing valve. A speed of up to 15,000 revolutions per minute at a pressure of 100 lb./sq. in. (7 kg./sq. cm.) is controlled by a trigger. The spindle of the drill is connected by a Luer fitting to a hollow trephine 7.5 cm. long and 3 mm. in external and 2.1 mm. in internal diameter, with a right-angled smooth cutting edge. The trephine is rifled internally for 5 mm. behind the cutting edge to guide the specimen into its lumen, and fitted with a sharp-pointed keyed stylet projecting 2.5 mm. beyond the end (Fig. 1).




FIG. 1.—Lung biopsy trephine for use with high-speed air-drill. Length 7.5 cm., external diameter 3 mm., internal diameter 2.1 mm. Internal rifling for 5 mm. at end. Sharp-pointed keyed stylet fitted.

The first step is to choose a suitable site with chest radiographs and markers. If the lesion is diffuse and bilateral the most convenient position is usually the eighth right intercostal space posteriorly with the patient sitting across the bed and leaning forward, but an axillary or anterior approach may be used with the patient lying down. Premedication is not usually necessary, but it is essential to demonstrate the apparatus to familiarize the patient with the whistling noise produced by

the air-drill. At the same time the patient should be instructed not to move, cough, or breathe deeply during the drilling process, but breath-holding is not necessary.

The trephine, previously sterilized, is flushed with 3.8% sodium citrate, and about 5 ml. of the citrate is left in a 20-ml. syringe. After infiltration with local anaesthetic a small skin incision is made with a scalpel. The trephine, with the pointed stylet in position, is introduced and, unless a specimen of pleura is required, the point is gently pushed through the parietal pleura. The stylet is then removed and the drill is attached to the trephine. The patient is told to keep still. The trigger is pressed and the trephine, revolving at maximum speed, is steadily pushed into the lung almost as far as the hub; this should take about three seconds. The drill is then detached from the trephine and replaced by the 20-ml. syringe, which is used to provide suction to retain the specimen while the trephine is withdrawn. The specimen is ejected into filter paper in a funnel and the liquid allowed to run through. Finally it is transferred into fixative.

### RESULTS

The results of the first 100 consecutive biopsies, performed from 1962 to 1966, are shown in Table I. A successful biopsy is defined as one where adequate material for histological examination was obtained. The first 21 biopsies, mostly of pleura, were performed with the small trephine, and though it proved successful for thickened pleura or solid lung lesions all the attempts to obtain specimens from lung with diffuse lesions failed.

TABLE I.—100 Biopsies of the Lung and Pleura with a High-speed Air-drill

	Total	Successful	Complications	
			Pneumo- thorax	Haemo- ptysis
<i>Small Trephine</i>				
Lung .. .. .	7	3	1	—
Pleura .. .. .	14	12	—	—
<i>Large Trephine</i>				
Transitional stage while undergoing development:				
Lung .. .. .	17	9	6	1
Pleura .. .. .	12	10	1	1
Final stage with rifling and pointed stylet added:				
Lung .. .. .	38	33 (87%)	7	6
Pleura .. .. .	12	10	—	—
Totals .. .. .	100	77	15	8

Subsequent biopsies were performed with the large trephine. There was a transitional stage during which modifications to the trephine were reflected in improving results in lung biopsy. Finally, when rifled and fitted with the pointed stylet, 33 out of 38 (87%) lung biopsies were successful at the first attempt, the majority being diffuse lung conditions (Table II).

TABLE II.—Histological Findings in 38 Lung Biopsies With the Large Trephine

Histological Diagnosis of Biopsy Specimen	
Number attempted .. .. .	38
Number successful .. .. .	33
Organizing pneumonia .. .. .	3
Lung abscess .. .. .	1
Tuberculosis .. .. .	3
Sarcoidosis .. .. .	5
Asbestosis .. .. .	2
Berylliosis .. .. .	2
Diffuse interstitial pulmonary fibrosis .. .. .	2
Non-specific pulmonary fibrosis .. .. .	2
Emphysema .. .. .	1
Alveolar proteinosis .. .. .	1
Eosinophilic vasculitis .. .. .	1
Adenocarcinoma .. .. .	3
Squamous carcinoma .. .. .	1
Undifferentiated carcinoma .. .. .	3
Normal lung .. .. .	3

**Complications.**—Complications were not serious. Routine post-biopsy radiographs showed that pneumothorax occurred in 15% of cases, but it was usually shallow and asymptomatic (Table I). In most instances the lung re-expanded uneventfully, but one patient required aspiration of air to relieve dyspnoea and another two with surgical emphysema needed an intercostal tube. Only one of the eight haemoptyses consisted of more than transient staining. It amounted to 50 ml. and ceased within half an hour. None of the patients complained of significant pain. There was no instance of air embolism or of invasion of the biopsy track by infection or neoplasm.

### CASE REPORTS

**Case 1.**—A 59-year-old male electroplater complained of three months' increasing dyspnoea on exertion. He had a few crepitations at both bases. A chest radiograph (Fig. 2) showed bilateral diffuse nodular shadowing confluent in the hilar regions. Sputum examination for acid-fast bacilli and neoplastic cells was negative and bronchoscopy showed no abnormality. Drill biopsy of the right lower lobe showed distension of the alveolar spaces with granular periodic-acid/Schiff-positive material, the picture being that of alveolar proteinosis (Fig. 3). He improved clinically and radiologically without treatment.

**Case 2.**—A 45-year-old man who worked with beryllium-copper alloys complained of two years' increasing dyspnoea on exertion, with cough and scanty sputum. There were no abnormal physical

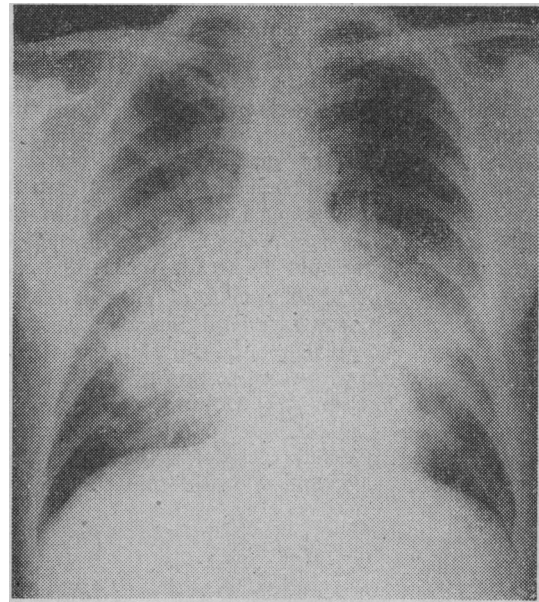


FIG. 2.—Case 1. Bilateral diffuse nodular shadowing confluent in the hilar regions.

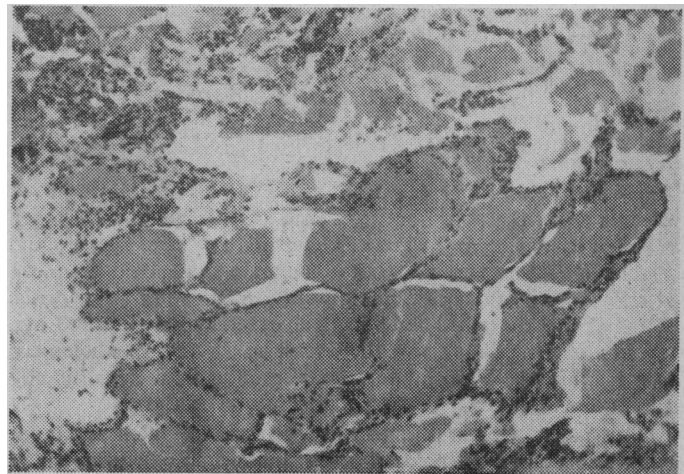


FIG. 3.—Case 1. Alveolar proteinosis. (H. and E. ×90.)

signs. Chest radiography showed bilateral granular and nodular shadowing. A patch test for berylliosis was negative. Drill biopsy of the right lower lobe showed miliary granulomata, the outstanding feature of which was the presence of numerous conchoid bodies. The appearances were those of chronic berylliosis. A shallow right pneumothorax resulted from the drill biopsy but absorbed uneventfully. Treatment was started with corticosteroids, but without appreciable clinical or radiological improvement. He was awarded 20% industrial compensation.

#### DISCUSSION

The first systematic approach to percutaneous lung biopsy was the needle aspiration method described by Martin and Ellis (1930). This technique produces a small specimen and has chiefly been used by investigators such as Lauby, Burnett, Rosemond, and Tyson (1965) for the differential diagnosis of pulmonary tumours.

In order to obtain a larger specimen for the study of diffuse lesions interest has recently centred on special needles incorporating a cutting mechanism. Manfredi, Rosenbaum, and Behnke (1963) published the results of 18 lung biopsies and advocated the use of a Franklin-Silverman needle. Smith (1964a) reviewed the literature and reported a series of 61 patients who had needle biopsy of the lung—39 with a Vim-Silverman and 22 with a Jack needle. In an addendum further experience with the Jack needle was mentioned, but he subsequently recorded one fatal pulmonary haemorrhage and recommended that the procedure should be performed in an operating theatre with a thoracic surgeon available (1964b). Krumholz and Weg (1966) obtained lung tissue in 56 out of 65 (86%) biopsies with a Franklin-Silverman needle on patients with diffuse lung lesions, chiefly sarcoidosis or interstitial fibrosis. Complications included 12 pneumothoraces, six of which required intubation, and two haemoptyses of 40–50 ml. Another patient with pulmonary hypertension, not included in the series, had a 750-ml. haemoptysis. A disadvantage of their method is that the patient has to hold his breath for 15–30 seconds.

Apart from the work of these authors, most of the reported techniques of needle biopsy have been directed towards a diagnosis of peripheral thoracic tumours, and biopsy of diffuse lung lesions has usually been performed by open thoracotomy according to the method described by Andrews and Klassen (1957). Although this ensures an adequate specimen of lung for histological examination, it entails a major surgical procedure and is subject to the usual complications of thoracotomy.

In our experience high-speed air-drill biopsy with the large trephine has proved successful in obtaining adequate specimens of diffuse lung lesions without the need for major surgery. It is performed at the bedside, thereby saving time in the operating theatre, although it is wise to arrange thoracic surgical cover. From the patient's point of view it is quick and painless, and breath-holding is not required. A further advantage is that the procedure can be repeated if an adequate specimen is not obtained or as a means of assessing the patient's progress.

#### SUMMARY

One hundred biopsies of the lung or pleura have been performed with a high-speed air-drill over the last four years. A specially designed trephine, 2.1 mm. in bore, proved successful in obtaining adequate specimens from patients with diffuse lung lesions. With this trephine in its final form 33 out of 38 (87%) lung biopsies were successful. Conditions such as sarcoidosis, berylliosis, alveolar proteinosis, and eosinophilic vasculitis were successfully diagnosed. Complications were not serious and pneumothorax, which occurred in 15% of cases, was usually asymptomatic.

We wish to thank the physicians and surgeons of the London Chest Hospital, in particular Dr. E. H. Hudson, for their support. We are indebted to Mr. K. G. Moreman for the photomicrograph and the Photographic Department of the Royal Marsden Hospital for the illustrations.

S. J. STEEL, M.D., M.R.C.P.,  
Consultant Physician to the Romford Group of Hospitals  
and Clinical Assistant to the London Chest Hospital.  
D. P. WINSTANLEY, M.R.C.P., M.C.PATH.,  
Consultant Pathologist to the London Chest Hospital.

#### REFERENCES

- Andrews, N. C., and Klassen, K. P. (1957). *J. Amer. med. Ass.*, **164**, 1061.  
Christiansen, H. (1940). *Acta radiol. (Stockh)*, **21**, 349.  
Deeley, T. J. (1960). *Acta Un. int. Cancr.*, **16**, 338.  
Ellis, F. (1947). *Brit. J. Surg.*, **34**, 240.  
Kirschner (1935). *Schweiz. med. Wschr.*, **65**, 28.  
Krumholz, R. A., and Weg, J. G. (1966). *J. Amer. med. Ass.*, **195**, 38.  
Lauby, V. W., Burnett, W. E., Rosemond, G. P., and Tyson, R. R. (1965). *J. thorac. cardiovasc. Surg.*, **49**, 159.  
Manfredi, F., Rosenbaum, D., and Behnke, R. H. (1963). *Ann. intern. Med.*, **58**, 773.  
Martin, H. E., and Ellis, E. B. (1930). *Ann. Surg.*, **92**, 169.  
Smith, W. G. (1964a). *Thorax*, **19**, 68.  
— (1964b). *Lancet*, **2**, 318.

## Medical Memoranda

### Agranulocytosis Coincident with Amodiaquine Therapy

*Brit. med. J.*, 1967, **3**, 32–33

Agranulocytosis is recognized as a rare complication of amodiaquine therapy. Love, Foulk, Williams, and Mitchell (1953) reported two cases of leucopenia; Yates, Leeper, and Fishler (1955) reported a case of pancytopenia; and Kennedy (1955) described a case of absolute neutrophil leucopenia. Glick (1957) described fatal agranulocytosis following 200 mg. of amodiaquine daily for eight weeks, and Perry, Bartholomew, and Hanlon (1962) an almost fatal reaction with hepatitis and agranulocytosis after 200 mg. daily for seven days.

This paper reports four cases (one fatal) in which agranulocytosis occurred coincident with taking amodiaquine as a malaria suppressive.

#### CASE 1

A previously healthy 20-year-old man, resident in Papua for only one week, was admitted to hospital with high fever, malaise, and a sore throat. He had taken 150 mg. of amodiaquine once or twice daily for three weeks, that dose having been prescribed in error as a malaria suppressive. He had never taken amodiaquine before, and was not taking any other drug. Haemoglobin was 14.1 g./100 ml., and the total leucocyte count 3,000/cu. mm., with no granulocytes. Bone-marrow aspiration showed an almost complete absence of developing granulocytes. Paul-Bunnell test was negative.

He was extremely ill from the onset, running a high fever and vomiting intermittently. A small blister on the knee developed into a spreading cellulitis from which *Pseudomonas pyocyanea* was isolated, the same organisms also being cultured from the blood stream. In spite of broad-spectrum antibiotics, digitalis, and corticosteroids he died on the fifth day in a state of "Gram-negative shock." Blood counts are shown in the Table.