9 Miller E. *Recovery and management of neuropsychological impairments*. Chichester: John Wiley and Sons, 1984.
10 Powell GE. *Brain function therapy*. Aldershot: Gower Publishing Company, 1981:20-57.
11 Rosenthal M, Griffith ER, Bond MR, Miller DJ, eds. *Rehabilitation of the head injured adult*. Philadelphia: FA Davis Co, 1983.
12 Newcombe F. Rehabilitation in clinical neurology: neuropsychological aspects. In: Vinken PJ, Bruyn GW, eds. *Handbook of clinical neurology. Neurobehavioural disorders*. Amsterdam: Elsevier (new edition of this volume in press).
13 Diller L, Gordon W. Interventions for cognitive deficits in brain-injured adults. *J Consult Clin Psychol* 1981;**49**:822-34.
14 Evans CD, ed. *Rehabilitation after severe head injury*. Edinburgh: Churchill Livingstone, 1981.
15 Wilson BA, Moffat N, eds. *Clinical management of memory problems*. London: Croom Helm, 1984.
16 Harris JE, Sunderland A. A brief survey of the management of memory disorders in rehabilitation units in Britain. *Int Rehabil Med* 1981;**3**:206-9.
17 Wilson B. A survey of behavioural treatments carried out at a rehabilitation centre for stroke and head injuries. In: Powell GE. *Brain function therapy*. Aldershot: Gower Press, 1981.
18 Grafman J. Memory assessment and remediation in brain-injured patients: from theory to practice. In: Edelstein BA, Couture ET. *Behavioural assessment and rehabilitation of the traumatically brain-damaged*. New York: Plenum Press, 1984:151-89.
20 Goodman-Smith A, Turnbull J. A behavioural approach to the rehabilitation of severely brain-injured adults. *Physiotherapy* 1983;**69**:393-6.
21 Code C, Müller DJ, eds. *Aphasia therapy*. London: Edward Arnold, 1983.
22 Jay P. *Coping with disability*. 2nd ed. London: Disabled Living Foundation, 1984.
23 Jay P. *Help yourselves: a handbook for hemiplegics and their families*. 3rd ed. Hornchurch: Ian Henry, 1979 (new edition in press).
24 Miller E. The training characteristics of severely head-injured patients: a preliminary study. *J Neurol Neurosurg Psychiatry* 1980;**43**:525-8.
25 Wilson B. *Rehabilitating memory*. New York: Guilford Press (in press).

Lesson of the Week

Osteomalacia presenting as pathological fractures during pregnancy in Asian women of high socioeconomic class

P DANDONA, F OKONOFUA, R V CLEMENTS

Osteomalacia is widely prevalent in the Asian immigrant population at clinical[1] and subclinical[2 3] levels, especially in those who are vegetarians. Pregnancy is associated with increased demands for vitamin D and hence may be responsible for the induction of clinical osteomalacia[4] among women who may otherwise have only biochemical, subclinical abnormalities. We describe two vegetarian Asian women who presented with pathological fractures during the third trimester of pregnancy, having been completely asymptomatic before pregnancy. So far as we know this is the first report showing the occurrence of such fractures in pregnant women who were asymptomatic before pregnancy.

Osteomalacic fractures may occur in pregnancy in Asian women irrespective of socioeconomic state

Case 1

A vegetarian primigravid Asian chartered accountant aged 28 developed pain in her foot during the seventh month of pregnancy. The pain gradually increased and she was referred for an orthopaedic consultation. She had tenderness and swelling over the metatarsal bones and a radiograph confirmed fractures of the metatarsals. She also stated that she had aches and pains in her chest and pelvis and weakness, with difficulty in climbing stairs. She had proximal myopathy.

Plasma biochemical studies confirmed osteomalacia—calcium concentration 2·0 mmol/l (8·0 mg/100 ml); phosphate 0·7 mmol/l (2·1 mg/100 ml); alkaline phosphatase activity 222 IU/l (normal 30-120 IU/l); albumin concentration 38 g/l. 25 Hydroxyvitamin D was not detectable and serum parathyroid hormone concentration (N terminal assay) was 320 ng/l (upper limit of normal 120 ng/l). She was treated with calciferol, 600 000 IU by intramuscular injection, and with one tablet of calcium and vitamin D daily. Over the next four weeks the pain in her foot subsided, the aches and pains disappeared, and the proximal myopathy resolved. Plasma calcium and phosphate concentrations became normal. At term she delivered a normal baby who had no neonatal complications.

After delivery she stopped taking vitamin D tablets and did not attend for follow up. She breast fed her baby. Six months after delivery she presented with diffuse aches and pains and inability to carry her baby in her arms. She had diffuse bony tenderness and severe proximal myopathy. Plasma calcium and phosphate concentrations had fallen, while alkaline phosphatase activity had increased. She was treated with calciferol and calcium+vitamin D tablets. She again lost her symptoms within four weeks and continued to take vitamin D supplements thereafter.

Case 2

A 25 year old Asian vegetarian primigravid biochemist (the wife of a pharmacist) presented with severe pain in hips and feet of four days' duration during the seventh month of pregnancy. These pains had kept her in bed. She had had mild to moderate pain in her hips in the earlier part of her pregnancy. She had been taking calcium, iron, and folic acid supplements for the duration of pregnancy but had taken no vitamin D. There was noticeable limitation in movement of both hips, more prominent on the left.

Radiography of the hips showed Looser's zones in the femoral neck bilaterally with severe demineralisation; radiographs of feet showed fractures of metatarsals on both sides (figure). Plasma biochemical values were: calcium concentration 2·02 mmol/l (8·1 mg/100 ml), phosphate 0·7 mmol/l (2·2 mg/100 ml), alkaline phosphatase activity 178 IU/l, and albumin concentration 35 g/l. Serum iron concentration was 20 μmol/l (112 μg/100 ml) with a total iron binding capacity of 66 μmol/l (369 μg/100 ml). Serum 25 hydroxyvitamin D was not detectable. She was treated with 300 000 IU of calciferol by intramuscular injection and also given oral vitamin D supplements.

The pregnancy continued uneventfully and at 38 weeks she delivered spontaneously a normal baby.

Metabolic Unit, Department of Chemical Pathology and Human Metabolism, Royal Free Hospital and School of Medicine, London NW3 2QG
P DANDONA, DPHIL, MRCP, director of metabolic unit, senior lecturer
F OKONOFUA, MB, research fellow

Department of Obstetrics and Gynaecology, North Middlesex Hospital, London N18 2QX
R V CLEMENTS, FRCOG, FRCS, consultant

Correspondence to: Dr P Dandona.

Comment

The occurrence of these pathological fractures during pregnancy in two Asian vegetarian women emphasises yet again the high prevalence of subclinical osteomalacia in the Asian community, more especially in women. Pregnancy clearly played a part in the pathogenesis of these fractures, since pregnancy may be associated with (*a*) a depletion of vitamin D stores and (*b*) a state of relative hyperparathyroidism.[5] Both would render patients vulnerable to fractures and to delayed healing. Of relevance to these facts are our other data, showing an increase of parathyroid hormone concentrations in sera of both Asian and white women during pregnancy, the concentrations of parathyroid hormone in Asian women being greater than those in white women throughout pregnancy.[6] Like other studies, ours did not show a progressive fall in 25 hydroxyvitamin D concentrations. Thus, although we assume that pregnancy puts greater demands on vitamin D stores, there are no objective biochemical data to support this. It is also relevant that the bone density is inversely related to serum parathyroid hormone concentrations in patients with nutritional osteomalacia (unpublished observations).

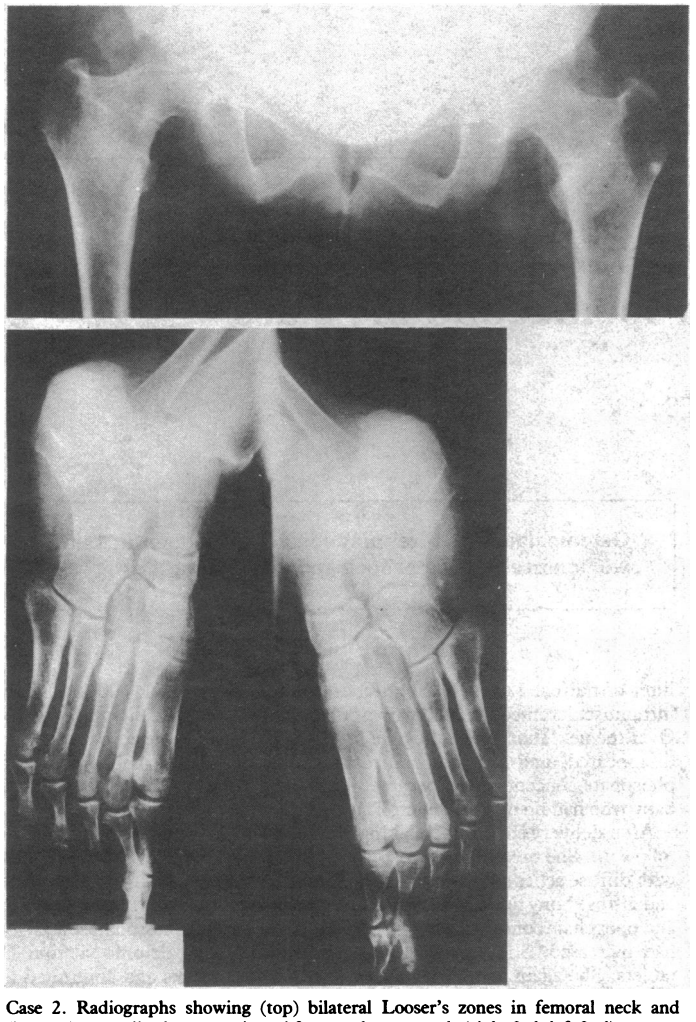

Case 2. Radiographs showing (top) bilateral Looser's zones in femoral neck and (bottom) generalised osteopenia and fractured metatarsals (right 3rd, left 2nd).

Clearly, therefore, supplementation of pregnant Asian women with vitamin D must be carried out on a routine basis. This would ensure adequate vitamin D stores in these women and their newborn and thus help adequate mineralisation of their skeletons. It is relevant that the concentration of 25 hydroxyvitamin D in cord serum is significantly lower than that in maternal serum at term[7] and that in states of vitamin D deficiency 25 hydroxyvitamin D concentrations may be even lower or undetectable.[8] Supplementation with vitamin D would also prevent neonatal secondary hyperparathyroidism observed by us in Asian babies.[6] Babies born to both women were normal clinically and did not have neonatal hypocalcaemia or rickets. This is probably the result of the ability of the fetus to extract from the mother sufficient 25 hydroxyvitamin D across the placenta and to activate 25 hydroxyvitamin D through rapid 1α hydroxylation in the kidney and the placenta to 1,25 dihydroxycholecalciferol. In addition, both these women were given large therapeutic doses of calciferol, which would have restored fetal vitamin D metabolism to normal.

The other important fact to emerge from this report is that both patients were well educated, professional members of the middle class, who should have been aware of the endemicity of hypovitaminosis D among their community. Both were oblivious of the necessity of this vitamin, while one was taking calcium supplements. Nutritional disease is usually associated with members of lower socioeconomic groups, and clinicians often ignore the possibility of nutritional disease among professional people and members of higher socioeconomic groups. Plainly the immigrant community of all classes needs to be made more aware of this problem and community based health services must start an educational and prevention programme in this subject. It is remarkable that a totally preventable nutritional disease is being allowed to continue more than two decades after its identification in the immigrant community.

References

1 Dunnigan MG, Patten JDJ, Haases SJ, McNicol GW, Gardner MG, Smith CM. Late rickets and osteomalacia in Pakistan community in Glasgow. *Scott Med J* 1961;7:159-67.
2 Stanbury SW. Vitamin D and hyperparathyroidism. *J R Coll Physicians Lond* 1981;**15**:205-10.
3 Dandona P, Mohiuddin J, Weerakoon J, Fonseca V, Healy T. Persistence of parathyroid hypersecretion following vitamin D supplementation in Asian vegetarian osteomalacics. *J Clin Endocrinol Metab* 1984;**59**:535-8.
4 Felton DJC, Stone WD. Osteomalacia in Asian immigrants during pregnancy. *Br Med J* 1966;i:1521-2.
5 Reitz RE, Daane TA, Woods JR, Weinstein RL. Calcium, magnesium, phosphorus and parathyroid hormone inter-relationships in pregnancy and newborn infants. *Obstet Gynecol* 1977;**50**:701-5.
6 Okonofua F, Houlder S, Thomas M, O'Brien S, Dandona P. Elevated plasma parathyroid hormone concentrations in pregnant Asian women and their neonates. *Clin Sci* 1985;**68**:70P.
7 Cockburn F, Belton NR, Purvis RJ, *et al.* Maternal vitamin D intake and mineral metabolism in mothers and newborn infants. *Br Med J* 1980;**281**:11-3.
8 Serenius F, Elldressy AHT, Dandona P. Vitamin D nutrition in pregnant women at term and in newly born babies in Saudi Arabia. *J Clin Pathol* 1984;**37**:444-7.

(Accepted 20 November 1984)

Is it reasonable to advise patients that verrucas and other warts require no treatment and will eventually disappear spontaneously and that the only reason for removing them surgically is if they are causing pain and discomfort?

Warts of all types including plantar warts, often referred to as verrucas, are caused by the human wart (papilloma) virus, of which there are several types. Whereas most people can develop an immune response to the infection followed by disappearance of the warts, this may take anything up to five years.[1] About 30% will disappear within six months. Some warts, such as mosaic warts, are notoriously slow to cure. Individuals suffering from any immunological abnormality will also have great difficulty in getting rid of their warts. Children's warts resolve more quickly than adults' and in the under 5s there is much to be said for refraining from treatment, but in others treatment will accelerate resolution, and recent warts are more responsive than those of long standing. Surgical treatment of warts is rarely indicated as most will respond to simple topical applications[2] or judicious cryotherapy. Excision of warts should be avoided as this does not eradicate the infection and leaves permanent scars. Curettage with a spoon curette or treatment with electrocautery is occasionally justified in non-responding painful warts. Although there should be no scarring after these procedures, the recurrence rate is about 20%.—M H BUNNEY, associate dermatologist, Edinburgh.

1 Massing AM, Epstein WL. Natural history of warts. *Arch Dermatol* 1963;**87**:306.
2 Bunney MH, Nolan M, Williams D. An assessment of methods of treating viral warts by comparative treatment trials based on a standard design. *Br J Dermatol* 1976;**94**:667-9.