

administration despite having intermittently normal values for both serum cortisol concentration and urinary free cortisol excretion rate. We believe that cyclical hormonogenesis could possibly give rise to misleading responses during dexamethasone suppression tests, though this is likely to be as true for measurement of urinary free cortisol excretion or 17-hydroxycorticosteroids as it is for serum cortisol concentration.

In summary, we suggest that the low dose dexamethasone suppression test, incorporating measurement of serum cortisol concentration rather than of urinary cortisol or steroid excretion rate, is highly reliable in screening for Cushing's syndrome and may be of considerable financial benefit in facilitating outpatient rather than inpatient investigation.

We thank Sister R Humphries and the nursing staff of this unit for their careful and conscientious help during this study; and Paula Robinson for preparing the manuscript.

## References

- 1 Crapo L. Cushing's syndrome: a review of diagnostic tests. *Metabolism* 1979;28: 955-77.

- 2 Liddle GW. Tests of pituitary adrenal suppressibility in the diagnosis of Cushing's syndrome. *J Clin Endocrinol Metab* 1960;20:1539-60.
- 3 Burke CW, Beardwell CG. Cushing's syndrome. An evaluation of the clinical usefulness of urinary free cortisol and other urinary steroid measurements in diagnosis. *Q J Med* 1973;42:175-204.
- 4 Eddy RL, Jones AL, Gilliland PF, Ibarra JD, Thompson JQ, McMurray JF Jr. Cushing's syndrome: a prospective study of diagnostic methods. *Am J Med* 1973;55:621-38.
- 5 Tucci JR, Jagger PI, Lauler DP, Thorn GW. Rapid dexamethasone suppression test for Cushing's syndrome. *JAMA* 1967;199:379-82.
- 6 Seidensticker JF, Folk RL, Wieland RG, Hanwi GJ. Screening test for Cushing's syndrome with plasma 11-hydroxycorticosteroids. *JAMA* 1967;202:87-90.
- 7 McHardy-Young S, Harris PWR, Lessof MH, Lyne C. Single-dose dexamethasone suppression test for Cushing's syndrome. *Br Med J* 1967;iii:740-4.
- 8 Connolly CK, Gore MBR, Stanley N, Wills MR. Single-dose dexamethasone suppression in normal subjects and hospital patients. *Br Med J* 1968;iii:665-7.
- 9 Holdaway IM, Evans MC, Ibbertson HK. Experience with a short test of pituitary-adrenal function. *Aust NZ J Med* 1973;3:507-11.
- 10 Thoren M, Sjöberg HE, Hall K, Low H. A rapid screening test for Cushing's syndrome. *Acta Med Scand* 1975;198:303-8.
- 11 Mattingly D. Disorders of the adrenal cortex and pituitary gland. In: Baron DN, Compston N, Dawson AM, eds. *Recent advances in medicine*. 15th ed. London: Churchill, 1968:125-69.
- 12 Besser GM, Edwards CRW. Cushing's syndrome. *Clin Endocrinol Metab* 1972; 1:451-90.
- 13 Ashcraft MW, Wan Herle AJ, Vener SL, Geffner DL. Serum cortisol levels in Cushing's syndrome after low and high dose dexamethasone suppression. *Ann Intern Med* 1982;97:21-6.
- 14 Riad-Fammy D, Read GF, Gaskell SJ, Dyas J, Hindawi R. A simple direct radioimmunoassay for plasma cortisol featuring a <sup>125</sup>I radioligand and a solid phase separation technique. *Clin Chem* 1979;25:665-8.
- 15 Orth DN. The old and new in Cushing's syndrome. *N Engl J Med* 1984;310: 649-51.

(Accepted 14 August 1984)

# SHORT REPORTS

## Television induced seizures in alcoholics

Television induced seizures usually occur in patients with photosensitive epilepsy. This epilepsy is usually idiopathic and has a well known genetic predisposition.<sup>1</sup> We describe three chronic alcoholics who during a period of abstinence had a grand mal seizure while watching or adjusting the television set. So far as we know environmentally induced photic seizures have not been reported as a manifestation of alcohol withdrawal.

### Case reports

**Case 1**—A 26 year old man had a grand mal seizure when he was adjusting the television set. In the hours before the fit he had noticed tremulousness and irritability. Six months earlier he had suffered an identical seizure, which had also occurred while he was adjusting the television. He had been a heavy beer drinker for several years and on both occasions he had not had a drink since the day before. There was no other past medical history or family history of epilepsy and he was not taking medication. Examination showed a coarse tremor of both arms, spider angiomas, palmar erythema, and a lip bite lesion. Laboratory findings on admission contained the following abnormal values: mean corpuscular volume 100 fl (100 µm<sup>3</sup>), γ-glutamyltransferase activity 153 IU/l (normal < 40 IU/l), and creatine kinase activity 482 IU/l (normal < 100 IU/l). Serum electrolyte, glucose, and ammonia concentrations were normal, as were renal function values. An electroencephalogram the day after the seizure showed an α rhythm of 10 Hz and no abnormalities on intermittent light stimulation. A computed tomogram of the brain was normal. Liver biopsy disclosed cirrhosis.

**Case 2**—A 40 year old chronic alcoholic had a first grand mal seizure when watching television. A few minutes after regaining consciousness he had a second fit. Two days earlier he had stopped alcohol because of an upper respiratory tract infection. There was no family history of epilepsy and he was not taking medication. Examination showed mild confusion and a postural tremor of both arms. Abnormal findings on routine laboratory investigation were: potassium concentration 2.9 mmol(mEq)/l, γ-glutamyltransferase activity 650 IU/l, and creatine kinase activity 152 IU/l. Serum electrolyte and glucose concentrations, renal function values, and haematological measurements were normal. Four days after admission the electroencephalogram showed fast, low voltage activity and no abnormalities on intermittent light stimulation. CT scan of the brain was normal.

**Case 3**—A 31 year old man with a history of delirium tremens five years before had a first grand mal seizure the moment that he started watching television. He usually drank about 15 bottles of beer daily. There was no family history of epilepsy and he was not taking medication. He had not had a drink since the day before the seizure. Examination showed only tremor of both hands. γ-Glutamyltransferase activity was 1020 IU/l and creatine kinase activity 225 IU/l. Serum electrolyte and glucose concentra-

tions, renal function values, and haematological measurements were normal. Four days after admission an electroencephalogram showed an α rhythm of 9 Hz and no abnormalities on intermittent light stimulation. CT scan of the brain was normal.

The table gives the circumstances of the seizures in the three patients.

Circumstances of seizures in the three patients

Case No	Television set (transverse diameter of screen)	Distance (and angle) of person to screen	Background lighting	Interference on screen
1 { First seizure	Colour (30 cm)	Close (horizontal)	Dim	None
2 { Second seizure	Colour (66 cm)	Close (horizontal)	Dim	None
3	Colour (66 cm)	2.5 m (horizontal)	Dim	None
3	Colour (56 cm)	3 m (horizontal)	Dim	None

### Comment

Seizures after alcohol withdrawal are usually grand mal attacks which occur between six and 48 hours after the last drink. Liability to this type of seizure is often accompanied by heightened stroboscopic flicker sensitivity with photomyoclonic or photoconvulsive responses in the electroencephalogram.<sup>2</sup> The occurrence of seizures in our patients when watching or adjusting the television set may have been simple coincidence. Nevertheless, in view of the heightened photosensitivity observed in the electroencephalograms of patients after alcohol withdrawal it is tempting to assume that their seizures were television induced. In our first patient simple coincidence seems especially unlikely because he twice had a seizure under identical circumstances. In none of our patients did the electroencephalogram show abnormal responses on intermittent light stimulation. This agrees with the notion that photic induced electroencephalographic abnormalities in the alcohol withdrawal period may occur only at the time of the seizure.<sup>2</sup>

Evidence suggests that central dopaminergic neurotransmission is implicated in the pathophysiology of generalised photosensitive epilepsy. Apomorphine, a dopamine agonist, blocks epileptic photosensitivity in patients with generalised photosensitive epilepsy.<sup>3</sup> The mechanism by which dopamine acts in the visual cortex has still to be elucidated. Interestingly, other studies have shown that dopaminergic neurotransmission is also impaired in the alcohol withdrawal period. In ethanol dependent rats release of dopamine in the striatum is reduced during alcohol withdrawal.<sup>4</sup> Although this has not been shown in man, we may assume that there is also a reduced dopaminergic turnover in the visual cortex in patients during abstinence from alcohol. Intermittent photic stimulation by itself reduces the release

of endogenous dopamine in the visual cortex.<sup>5</sup> Photic stimulation, in our patients brought about by television, might exacerbate a latent dopaminergic deficiency in the visual cortex due to alcohol withdrawal and lead to seizure.

The presenting feature in all three patients was that they had had a seizure when watching or adjusting the television set. We suggest that when a patient presents after a television induced seizure the possibility of alcoholism should be considered, because management is completely different from that of idiopathic photosensitive epilepsy.

- 1 Newmark ME, Penry JK. *Photosensitivity and epilepsy: a review*. New York: Raven Press, 1979.
- 2 Victor C, Brausch C. The role of abstinence in the genesis of alcoholic epilepsy. *Epilepsia* 1967;8:1-20.
- 3 Quesney LF, Andermann F, Gloor P. Dopaminergic mechanism in generalized photosensitive epilepsy. *Neurology (NY)* 1981;31:1542-4.
- 4 Hunt WA, Majchrowicz E, Dalton TK, Swartzwelder HS, Wixon H. Alterations in neurotransmitter activity after acute and chronic ethanol treatment: studies of transmitter interactions. *Alcohol: Clinical and Experimental Research* 1979;3:359-63.
- 5 Reader TA, Champlain J, Jasper H. Catecholamines released from cerebral cortex in the cat: decrease during sensory stimulation. *Brain Res* 1976;11:95-108.

(Accepted 8 August 1984)

Department of Neurology, Akademisch Ziekenhuis, Vrije Universiteit Brussel, Brussels, Belgium

J DE KEYSER, MD, assistant

A MICHOTTE, MD, assistant

G EBINGER, MD, head of department

Correspondence to: Dr J De Keyser, Department of Neurology, Akademisch Ziekenhuis VUB, Laarbeeklaan 101, B-1090 Brussels, Belgium.

## Protein C values in coronary artery disease

The many risk factors that have been identified for coronary artery disease include a hypercoagulable state, one large study showing that high concentrations of fibrinogen and factors VIIIc and VIIc are better predictors of death from cardiovascular disease than is the serum cholesterol value.<sup>1</sup> Defective fibrinolytic activity has also been implicated in the aetiology of early onset coronary artery disease,<sup>2</sup> and protein C is a recently described regulator of fibrinolysis. Deficiency of protein C has been associated with venous thrombotic disease<sup>3</sup> but concentrations of the protein have not been reported in patients with coronary artery disease. We have therefore assayed protein C values in a group of young patients with coronary artery disease; those with known risk factors for the disease (diabetes mellitus and hyperlipidaemia requiring drug treatment) were excluded.

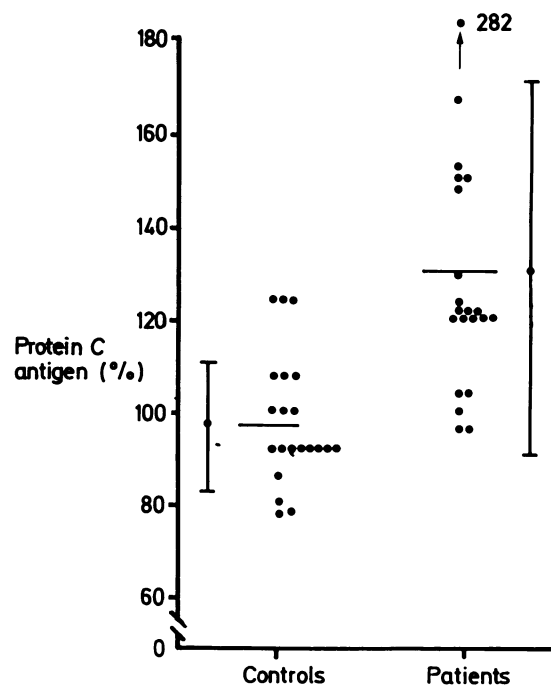
### Patients, methods, and results

We studied 21 men aged less than 50 who had angiographic evidence of coronary artery disease. All coronary angiograms made at the John Radcliffe Hospital between 1 January 1979 and 31 December 1983 were reviewed. Angiography in each case was to assess whether patients with angina pectoris were suitable for surgical intervention. Seventy one patients had a positive angiogram, but those who had undergone surgery within the past six months, lived more than 30 miles (48 km) away, or were considered by their cardiologist to be psychologically unsuitable for study were excluded, as were three patients with hyperlipidaemia requiring drug treatment. None had diabetes mellitus. All 21 patients included in the study had documented severe coronary artery disease with complete occlusion of at least one coronary artery in seven cases and almost complete occlusion in 12. Myocardial infarction had been documented in four patients, and 13 had undergone coronary artery surgery. Twenty one healthy non-smoking men aged 25-48 years served as controls.

All patients were well, and none had been in hospital over the past 12 months. Thirteen continued with antianginal treatment, although only four suffered from exertional angina. No patient was taking coumarin anticoagulants, and only two were smokers (fewer than 10 cigarettes a day) at the time of study.

Subjects were studied between 1 June and 31 August 1983, being seen between 0830 and 1030 after an overnight fast. Blood was drawn after 30 minutes' supine rest and samples assayed for prothrombin ratio, kaolin cephalin clotting time, full blood count, fasting blood lipid concentrations, and protein C antigen and activity values.<sup>3,4</sup> Lastly, plasminogen activator concentrations were assayed on euglobulin lysis plates before and after a standard venous occlusion stress test.<sup>5</sup> Protein C antigen and activity values were expressed as a percentage of normal (pooled plasma obtained from 40 normal subjects).

Full blood count, prothrombin ratio, and kaolin clotting time were normal in all subjects, and four patients had borderline hyperlipidaemia. Protein C antigen values were normal or increased in all patients studied, eight of them having values higher than in the controls (figure). Protein C activity results were similar: the mean activity in the patients was 115% (SD 27%) and in the controls 96.6% (SD 16.5%). Fibrinolytic potential in response to venous occlusion was poor in 10 of the 21 patients and two of the controls, but the high protein C values were not related to defective fibrinolysis.



Protein C antigen values in men aged < 50 with proved coronary artery disease and in controls. Bars are means and SD.

### Comment

Protein C is the proenzyme of a serine protease concerned in the regulation of coagulation and which is made in the liver in the presence of vitamin K. The protease is a powerful anticoagulant which inactivates factors V and VIIIc and stimulates the fibrinolytic pathway.<sup>3</sup> Both protein C deficiency and defective fibrinolysis have been independently identified as risk factors for venous thrombotic disease,<sup>3,5</sup> and defective fibrinolysis has been linked with early onset coronary artery disease.<sup>4</sup> None of our patients with coronary artery disease had a deficiency of protein C; indeed, eight of them had values higher than in the controls. These high values, however, were unrelated to an individual's fibrinolytic potential and remain unexplained.

We thank Dr B Gribbin and Professor P Sleight for allowing us to study their patients. This work was supported by a grant from the Oxford Area Research Committee.

- 1 Meade TW, Chakrabarti R, Haines AP, *et al*. Haemostatic function and cardiovascular death: early results of a prospective study. *Lancet* 1980;i:1050-4.
- 2 Walker ID, Davidson JF, Hutton I, Laurie TDV. Disordered fibrinolytic potential in coronary artery disease. *Thromb Res* 1977;10:509-20.
- 3 Broekmans AW, Velkamp JJ, Bertina RM. Congenital protein C deficiency and venous thrombosis. *N Engl J Med* 1983;309:340-4.
- 4 Bertina RM, Broekmans AW, Krommenhoek-van Es C, Van Wijngaarden A. The use of a functional and immunologic assay for plasma protein C in the study of the heterogeneity of congenital protein C deficiency. *Thromb Haemost* 1984;51:1-5.
- 5 Isaacson S, Nilsson IM. Defective fibrinolysis in blood and vein walls in recurrent "idiopathic" venous thrombosis. *Acta Chir Scand* 1972;138:313-9.

(Accepted 21 August 1984)

Department of Haematology, John Radcliffe Hospital, Headington, Oxford OX3 9DU

N T J O'CONNOR, MRCP, registrar in haematology

Haemostasis and Thrombosis Research Unit, Leiden University Hospital, Rijnsburgerweg, Leiden, The Netherlands

A W BROEKMANS, PHD, consultant in thrombosis and haemostasis  
R M BERTINA, PHD, consultant in thrombosis and haemostasis

Correspondence to: Dr N T J O'Connor.