

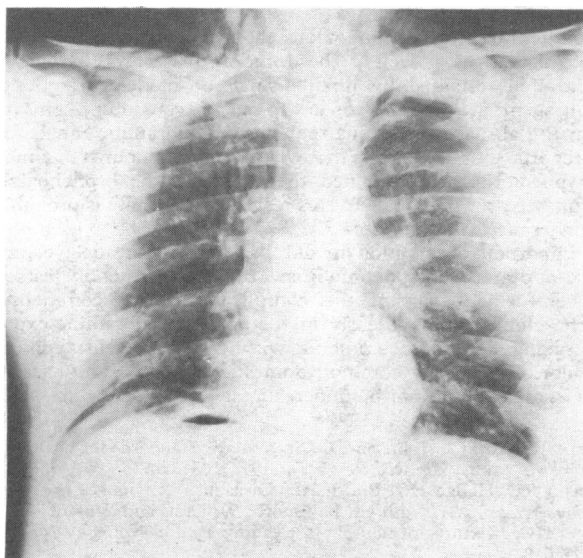
## Severe coughing and pneumoperitoneum

Coughing and straining have been suggested as contributing to the formation of subcutaneous emphysema, mediastinal emphysema, and pneumothorax in adults and children with and without underlying lung disease.<sup>1-4</sup> Severe and protracted coughing, however, has not previously been associated with pneumoperitoneum. I describe a patient with subcutaneous emphysema, mediastinal emphysema, and pneumoperitoneum in whom coughing may have had a causative role.

### Case report

A 23-year-old man presented to casualty complaining of feeling wheezy after having inhaled copper soldering flux fumes. He was examined, reassured, and sent home. Twelve hours later he returned complaining of dyspnoea and a severe, dry, non-productive cough. Clinically the chest was overinflated with poor bilateral expansion and widespread wheezing. The abdomen was distended but no discrete masses or organs were palpable.

An intravenous injection of aminophylline was given followed by an aminophylline infusion, and amoxycillin was started. Chest radiography showed subcutaneous emphysema, mediastinal emphysema, and pneumoperitoneum (figure). The subcutaneous emphysema worsened until it eventually almost closed both eyes. Salbutamol 2 mg thrice daily by mouth was started. Over the next few days the coughing decreased, his chest improved, and the pneumoperitoneum resolved. The subcutaneous emphysema slowly disappeared and he was discharged free of symptoms one week after admission.



Chest radiograph showing subcutaneous emphysema, mediastinal emphysema, and pneumoperitoneum.

### Comment

The extra-alveolar air in this case probably arose by a mechanism similar to that described by Macklin and Macklin,<sup>3</sup> who showed that when gas under pressure was applied to the trachea of cats it ruptured the overdistended alveoli, forming pulmonary interstitial emphysema that then disseminated towards the mediastinum to form mediastinal emphysema. From there it disseminated into the fascial planes of the neck to form a subcutaneous emphysema, ruptured through the mediastinal pleura to cause a pneumothorax, and escaped retroperitoneally to form a pneumoperitoneum. The pressures needed to cause a pneumoperitoneum are higher than those usually needed to cause a pneumothorax, and a pneumoperitoneum has not been previously noted without a pneumothorax when the source of the air is from the lungs.<sup>4</sup>

The extra-alveolar air in this case was probably due to a combination of the three factors that lead to alveolar breakdown.<sup>4</sup> Firstly, because this patient had an overinflated chest with wheezing there may have been overdistended alveoli distal to obstructed bronchioles. Formation of extra-alveolar air has been reported under these circumstances,

particularly in asthma.<sup>3</sup> Secondly, underlying lung damage due to the inhaled fumes may have encouraged breakdown of the alveoli wall. When this happens pulmonary interstitial emphysema forms, and this can progress to mediastinal emphysema, subcutaneous emphysema, pneumothorax, and pneumoperitoneum.<sup>4</sup> Thirdly, Macklin and Macklin reported that a sudden increase in intrathoracic pressure during a Valsalva manoeuvre, such as coughing, could also cause pulmonary interstitial emphysema, mediastinal emphysema, subcutaneous emphysema, and pneumothorax in otherwise normal lungs or facilitate the movement of extra-alveolar air in damaged lungs.<sup>2,3</sup> Although pneumoperitoneum and coughing have not been associated previously, there have been cases of so-called idiopathic or spontaneous pneumoperitoneum that might have been caused or exacerbated by coughing or vomiting; this could perhaps be determined by reading the case histories carefully.<sup>4</sup>

This case shows several important principles. Firstly, because the free air in the abdominal cavity was associated with subcutaneous emphysema and mediastinal emphysema it was almost certainly derived from ruptured alveoli in the thorax and not from a perforated abdominal viscus.<sup>4</sup> Abdominal air may itself cause respiratory embarrassment by splinting the diaphragm. Secondly, the pressure in the pleural space should be relieved if necessary with an intercostal drain; but the formation of extra-alveolar air, from whatever cause, may be decreased or prevented by reducing coughing and all forms of straining. Furthermore, understanding of the mechanism of formation of extra-alveolar air would allow doctors to consider more critically current suggested practices such as clamping the intercostal tube of a patient with a pneumothorax who is about to cough.<sup>5</sup>

I thank Ms L Smith for her help in preparing this manuscript.

<sup>1</sup> Ozanam C. De la rupture pulmonaire chez les enfants et de l'emphyseme general qui lui succede. *Archives g n rals de m decine* 1854;1:31.

<sup>2</sup> Macklin CC. Transport of air along sheaths of pulmonic blood vessels from alveoli to mediastinum. *Arch Intern Med* 1939;64:913-26.

<sup>3</sup> Macklin MT, Macklin CC. Malignant interstitial emphysema of the lungs and mediastinum as an important occult complication in many respiratory diseases and other conditions: an interpretation of the clinical literature in the light of laboratory experiment. *Medicine* 1944;23:281-358.

<sup>4</sup> Hillman KM. Pneumoperitoneum—a review. *Crit Care Med* 1982;10:476-81.

<sup>5</sup> Peatfield RC, Edwards PR, Johnson NMCI. Two unexpected deaths from pneumothorax. *Lancet* 1979;i:356-8.

(Accepted 6 July 1982)

Department of Anaesthesia, Charing Cross Hospital, London W6 8RF  
K M HILLMAN, MB, FFARCS, director of intensive care

## Retroperitoneal fibrosis associated with sotalol

Retroperitoneal fibrosis is fairly rare, and the aetiology usually remains unknown. Occasionally, however, an aetiological factor may be identified: methysergide taken for migraine reportedly induced retroperitoneal fibrosis in 1-3% of patients,<sup>1</sup> and analgesics, sedatives, and antihistamines have also been incriminated.<sup>2</sup> Retroperitoneal fibrosis has also been reported in patients who have taken beta-blockers, including atenolol,<sup>3</sup> oxprenolol,<sup>4</sup> and metoprolol.<sup>5</sup> We describe a case of retroperitoneal fibrosis in a patient who had been taking sotalol for five years.

### Case report

A 55-year-old children's nurse was referred to this hospital in December 1981 for fever and a raised erythrocyte sedimentation rate. She had been treated with sotalol 80 mg twice daily for five years for uncomplicated hypertension. At the time of diagnosis intravenous urography had shown nothing abnormal. She was also taking a derivative of vitamin A (retinoic acid) 25 mg twice daily, which she had begun six months before admission for pustulosis palmoplantaris. She had otherwise been in a good health until three weeks before admission, when she complained of lack of appetite, nausea, and mild fever.

Clinical examination showed nothing abnormal, and blood pressure was well controlled at 124/84 mm Hg. Haemoglobin concentration was 10.6 g/dl, erythrocyte sedimentation rate 77 mm in first hour, and serum creatinine concentration 71  $\mu$ mol/l (0.8 mg/100 ml). There was no abnormality on