Clinical Topics

Incidence and detection of occult hepatic metastases in colorectal carcinoma

I G FINLAY, D R MEEK, H W GRAY, J G DUNCAN, C S McARDLE

Abstract

Isotope liver scan, ultrasonography, and computed tomography of the liver were performed during the postoperative period in 43 consecutive patients undergoing laparotomy for colorectal carcinoma. Obvious hepatic metastases were detected in six patients at the time of surgery. Eleven patients considered to have a disease-free liver at laparotomy developed hepatic metastases during the two-year follow-up period. These patients were considered to have had occult hepatic metastases at the time of surgery. Postoperative isotope liver scan, ultrasonography, and computed tomography detected the presence of overt metastases in four, five, and six patients respectively. Of the 11 patients with occult metastases, isotope liver scan, ultrasonography, and computed tomography detected one, three, and nine respectively.

These observations suggest that 29% of patients undergoing apparently curative resection for colorectal carcinoma possess occult hepatic metastases and that computed tomography is superior to ultrasonography and isotope liver scan in detecting them.

Introduction

About 15-20% of patients undergoing laparotomy for colorectal carcinoma possess obvious hepatic metastases (overt metastases).[1 2] Clinicians are aware that a further group of patients exist in whom hepatic metastases are present but which remain undetected by the surgeon at laparotomy. The incidence of these occult hepatic metastases is not known.

Non-invasive methods of detecting hepatic metastases include the use of biochemical tests, isotope liver scan, ultrasonography, and, more recently, computed tomography. The relative value of these investigative techniques has been well established in patients with overt hepatic metastases,[3 4] but their role in detecting occult disease is not known. The aim of the present study was to determine the incidence of occult hepatic metastases in colorectal carcinoma and to compare the value of isotope liver scan, ultrasonography, and computed tomography in their detection.

Royal Infirmary, Glasgow G4 0SF

I G FINLAY, BSC, FRCS, registrar, University Department of Surgery
D R MEEK, MB, DMRD, senior registrar, Department of Radiology
H W GRAY, MD, MRCP, consultant physician, Department of Nuclear Medicine
J G DUNCAN, FRCS, FRCR, consultant radiologist, Department of Radiology
C S McARDLE, MD, FRCS, consultant surgeon, University Department of Surgery

Patients and methods

Forty-three consecutive patients undergoing surgery for colorectal carcinoma were included in the study. At laparotomy the surgeon allocated the patients to two groups (fig 1): (1) patients in whom obvious metastases were present which we will refer to as overt metastases; and (2) patients in whom the surgeon was unable to detect hepatic metastases.

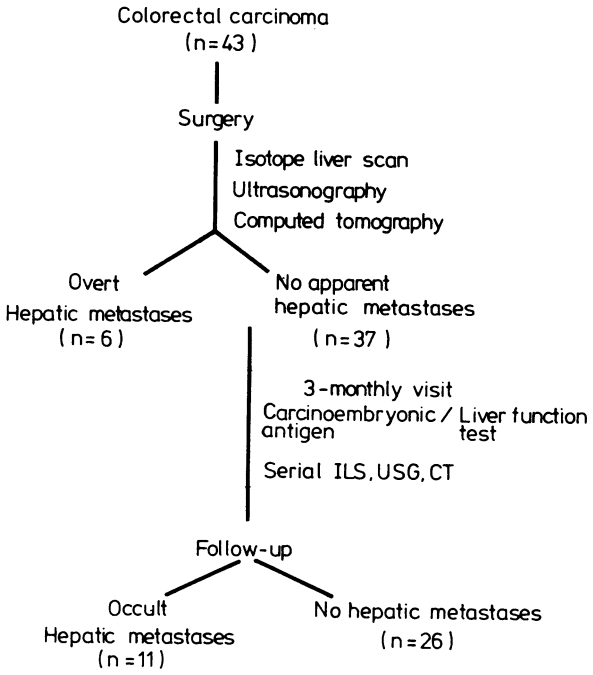

FIG 1—Definition of patient groups (overt metastases, occult metastases, and disease-free).

During the immediate postoperative period all patients underwent isotope liver scan, liver ultrasonography, and computed tomography.

Isotope liver scans were obtained by using 5 mCi of ^{99m}Tc tin colloid and imaged using high resolution parallel hole collimation and an Ohio Nuclear Series 100 gamma camera. Ultrasonography was performed using a Nuclear Enterprises 4200 Diasonograph with a 2·5 MHz transducer. Routine transverse and longitudinal scans of the liver were carried out.

Computed tomography scans were obtained with an EMI 5005 Whole Body Scanner using a 13-mm collimated beam, a 32-cm field size, and a 320×320 reconstruction matrix. Scans were performed at 15-mm intervals. In all cases the scans were performed without clinical information other than the knowledge that the patient had had a colorectal carcinoma.

To determine the incidence of occult hepatic metastases, patients considered at laparotomy to have a disease-free liver were followed up for a minimum of two years (fig 1). During this period they were seen

Br Med J (Clin Res Ed): first published as 10.1136/bmj.284.6318.803 on 13 March 1982. Downloaded from http://www.bmj.com/ on 18 April 2024 by guest. Protected by copyright.

one month postoperatively and thereafter at three-monthly intervals. At each visit blood was taken for liver function tests and estimation of serum carcinoembryonic antigen.[5] Serial imaging was performed within the follow-up period (*a*) when recurrent disease was suspected clinically; (*b*) in the presence of a persistently raised serum alkaline phosphatase or carcinoembryonic antigen concentration (>2·5 μg/l); and (*c*) in those patients in whom an initial investigation had been positive or equivocal. All patients surviving two years underwent further routine imaging.

At the end of the two-year follow-up period two clearly defined groups emerged (fig 1).

(1) Those patients who were alive and well with no clinical or biochemical evidence of hepatic metastases and normal imaging. These patients were considered to have been free of hepatic metastases at the time of surgery two years previously.

(2) Those patients who developed hepatic metastases during the follow-up period. This latter group of patients were considered to have had occult hepatic metastases at the time of surgery.

On the basis of the above allocation to three distinct clinical groups (overt metastases, occult metastases, and no hepatic disease), the predictive value of the three hepatic scanning techniques at the time of laparotomy was analysed.

Results

At laparotomy six patients had overt hepatic metastases (fig 1). Of the 37 patients considered to have a disease-free liver at laparotomy, 26 had no evidence of hepatic metastases at two years, while the remaining 11 patients had developed hepatic metastases during the period of follow-up. The presence of these metastases was confirmed histologically in five patients. The remaining six patients ultimately developed hepatomegaly, grossly raised serum alkaline phosphatase and carcinoembryonic antigen concentrations, and progressive enlargement of lesions confirmed by serial imaging. These 11 patients were therefore considered to have had occult hepatic metastases at the time of surgery. Nine died within the two-year follow-up period. A clinical example that highlights the role of serial scanning is outlined below.

Case history—A 55-year-old man presented with an acute large bowel obstruction. At laparotomy a hepatic flexure carcinoma was found, but no hepatic metastases were detected. An extended right hemicolectomy was performed. Histology confirmed the presence of lymph node metastases (Dukes C). Ultrasonography and isotope liver scan performed before discharge from hospital showed no abnormality whereas computed tomography suggested the presence of hepatic metastases. Both serum carcinoembryonic antigen and alkaline phosphatase concentrations became raised nine months after surgery, at which point the patient remained asymptomatic. Repeat computed tomography showed the suspected metastases to have enlarged (fig 2). The patient eventually complained of right upper quadrant pain 13 months postoperatively. The isotope scan at this time showed no abnormality but at 15 months became positive, at which time computed tomography showed the presence of extensive disease. The patient died 30 months after surgery.

Of the six patients with overt hepatic metastases, isotopic liver scan, ultrasonography, and computed tomography confirmed the presence of hepatic metastases in four, five, and six patients respectively (table).

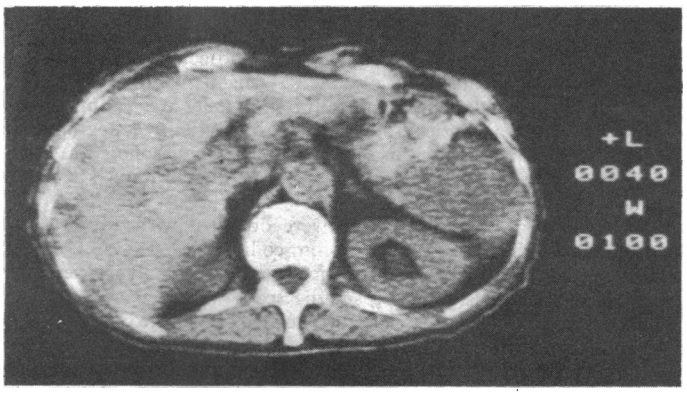

FIG 2—Computed tomography showing multiple hepatic metastases 10 months after surgery.

Predictive value of isotopic liver scan, ultrasonography, and computed tomography in detecting hepatic metastases. Number of positively identified metastases for each imaging technique is indicated

	Isotopic liver scan	Ultrasonography	Computed tomography
Overt metastases (n = 6)	4	5	6
Occult metastases (n = 11)	1	3	9
Total metastases (n = 17) true-positive	5	8	15
False-positive	4	1	3

Of the 11 patients with occult metastases, isotopic liver scan, ultrasonography, and computed tomography during the postoperative period detected the presence of hepatic metastases in one, three, and nine patients respectively (fig 3). Ultrasonography was technically unsatisfactory in three patients in this group. A combination of ultrasonography and computed tomography detected hepatic metastases in 10 of the 11 patients in the occult group.

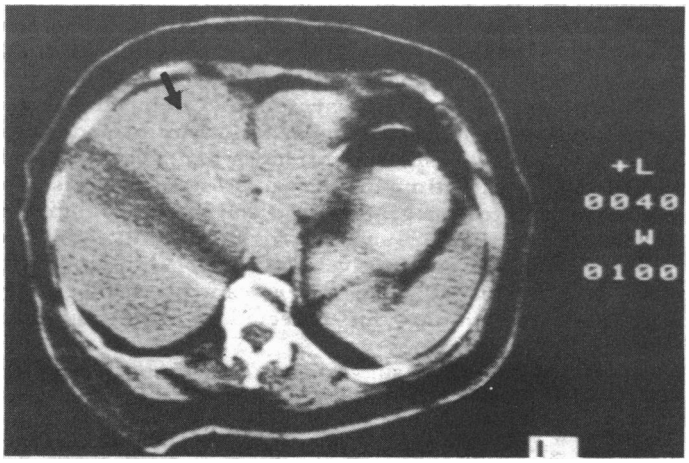

FIG 3—Example of occult hepatic metastases on computed tomography scan (arrowed).

The overall sensitivity (ability of the test to detect patients with disease) of isotopic liver scan, ultrasonography, and computed tomography in the 17 patients with hepatic metastases was 29%, 47%, and 88% respectively. The corresponding specificities (percentage of patients without disease correctly identified) were 85%, 96%, and 88%.

In four patients with overt hepatic metastases serum carcinoembryonic antigen concentration was raised one month postoperatively and remained raised until death. Only one patient with occult hepatic metastases had a raised serum carcinoembryonic antigen concentration one month after surgery. These five patients all had abnormal isotope liver scans.

Discussion

In the present study three groups of patients with colorectal carcinoma have been defined. Our observation that 14% of patients had overt hepatic metastases agrees with previous reports.[1 2] The second group of 11 patients who developed hepatic metastases during the follow-up period were considered to have had occult hepatic metastases at surgery. In five the metastases were histologically proved. The remaining six patients were considered to have hepatic metastases not merely on the basis of progressive changes on serial imaging but in addition they all developed clinically obvious progressive hepatic disease and abnormal biochemical indices. The third group of patients were alive at two years and were considered to have had no hepatic metastases at the time of laparotomy. This does not

Br Med J (Clin Res Ed): first published as 10.1136/bmj.284.6318.803 on 13 March 1982. Downloaded from http://www.bmj.com/ on 18 April 2024 by guest. Protected by copyright.

preclude the possibility that further metastases may become apparent at a later stage in this group.

Our group of 11 patients considered to have had occult hepatic metastases at operation are of particular interest. As long ago as 1941 Goligher studied 790 consecutive patients considered to have a disease-free liver at laparotomy.[6] Thirty-one patients died in the immediate postoperative period and a necropsy was performed. Of these, five (16%) had histological evidence of hepatic disease. The present prospective study suggests that 29% of patients with an apparently disease-free liver at laparotomy had occult hepatic metastases. This is in accordance with the work of Mooney,[7] who used umbilical vein perfusion of ^{99m}Tc microspheres and found a 30% incidence of occult metastases in a comparable group of patients.

Previous studies comparing the value of isotope liver scan, ultrasonography, and computerised tomography have used proved hepatic metastases detected by surgical exploration, liver biopsy, or necropsy to assess the accuracy of the imaging techniques.[3 4] These studies used patients comparable with the overt group in the present study. Histologically proved hepatic metastases are comparatively large, and this is reflected in the high sensitivity rates attributed to the standard imaging techniques in previous studies. For example, a recent comparison of the three techniques undertaken in a group of patients with a wide variety of proved hepatic neoplasia showed the sensitivity of computed tomography, isotope liver scan, and ultrasonography to be 96%, 94%, and 75% respectively. The false-positive rate for isotope liver scan was 26%.[8]

The present study is the first prospective comparative study of these three imaging techniques that has attempted to define the role of each in the detection of occult hepatic metastases in colorectal carcinoma. Computed tomography proved to be the most sensitive method of detecting occult hepatic metastases. Although these scans were assessed without clinical information, the technique was under appraisal and each image was carefully interpreted. This sensitivity may not therefore be reproduced in routine clinical practice. Ultrasonography and isotope liver scan predicted the presence of three and one respectively of the 11 occult metastases. The discrepancy between ultrasonography and isotope liver scan in these patients was unexpected but may be explained in several ways. Many of the metastases were under 1 cm in diameter and were therefore outside the resolution of standard scintigraphy. Furthermore, ultrasonography more readily detects hepatic metastases (such as those from colorectal carcinoma) that are predominantly positively echogenic.[9] The favourable results attributed to ultrasonography in the present study should not therefore be extrapolated to other tumours that are not positively echogenic.

A further feature of ultrasonography in this and other studies[10] was its high specificity in detecting hepatic neoplasia. Although we would not wish to draw firm conclusions on the basis of the few patients in the present study, it would appear that ultrasonography holds a marginal advantage over standard scintigraphy in detecting hepatic metastases from colorectal carcinoma if only because of its higher specificity. In addition there were three technical failures of ultrasonography, and it may be that with careful preparation of the patient the sensitivity will be enhanced.

In the present study 29% of patients with colorectal carcinoma considered to have a disease-free liver at the time of laparotomy proved to have occult hepatic metastases. All these patients subsequently developed clinical evidence of gross hepatic disease and nine of the 11 died within two years. A high-risk group of patients have therefore been identified who may warrant further treatment.

References

1 Oxley EM, Ellis H. Prognosis of carcinoma of the large bowel in the presence of liver metastases. *Br J Surg* 1969;**56**:149-52.

2 Bengtsson G, Carlsson G, Hafström L, Jonsson P. Natural history of patients with untreated liver metastases from colorectal carcinoma. *Am J Surg* 1981;**141**:586-9.

3 Levitt RG, Sagel SS, Stanley RJ, Gilbert Jost R. Accuracy of computed tomography of the liver and biliary tract. *Radiology* 1977;**124**:123-8.

4 Taylor KJW, Sullivan D, Rosenfield AT, Gottschalk A. Grey scale ultrasound and isotope scanning: complementary techniques for imaging the liver. *Am J Roentgenol* 1977;**128**:277-81.

5 Lawrence DJR, Stevens U, Bettleheim R. Role of plasma carcinoembryonic antigen in diagnosis of gastrointestinal, mammary, and bronchial carcinoma. *Br Med J* 1972;iii:605-9.

6 Goligher JC. The operability of carcinoma of the rectum. *Br Med J* 1941; ii:393-7.

7 Mooney B, Critchley M, Grime S, Taylor I. Portal vein liver scanning for early detection of liver metastases in colorectal cancer. *Gut* 1981;**25**: A436.

8 Snow JH, Goldstein HM, Wallace S. Comparison of scintigraphy, sonography and computed tomography in the evaluation of hepatic neoplasms. *Am J Roentgenol* 1977;**128**:277-81.

9 Green B, Bree RL, Goldstein HM, Courtney-Stanley RT. Grey scale ultrasound evaluation of hepatic neoplasms: patterns and correlations. *Radiology* 1977;**124**:203-8.

10 Debongnie JC, Pauls C, Fievez M, Wibin E. Prospective evaluation of the diagnostic accuracy of liver ultrasonography. *Gut* 1981;**21**:130-5.

(*Accepted 9 January 1982*)

MEDICINE AND THE MEDIA

IT IS DIFFICULT to make ignorance interesting: the scientific uncertainty that bedevils much of medical practice does not readily create dramatic television. *Horizon's* "Shots in the Dark" (BBC2, 1 March) explored the ethical implications of our uncertainty over the side-effects of medroxyprogesterone acetate—the long-acting contraceptive, Depo-Provera. The viewer was enticed by advance publicity suggesting that Third World women taking this drug were being exploited by Western capitalism, and the film began with a lean American talking persuasively about a "serious threat" of cancer in both mothers and children. The carcinogenic effects of diethylstilboestrol were briefly recalled, and the case against the injectable contraceptive looked black.

This fearsome overture turned out to be a device to engage our attention. Then came the facts: a summary of the inconclusive animal experiments, and a list of countries which, unlike the USA, have approved the drug (Britain sitting on the fence with "limited" approval). A missionary in Thailand with extensive experience put the case for the defence, and a judicious summing-up came from a Thai statistician, who spoke of his surprise at the cynicism and "unbelievable overstatements" of American pressure groups on both sides. The limitations of our knowledge became clear. Dr John Guillebaud (thank heavens—at last, an Englishman) explained how experts can disagree over the same inconclusive data, and suggested that individual members of the public can choose which attitude to take about drug safety. But to what extent can an isolated Thai community make an informed decision? The dilemma was graphically illustrated by a description of the success of injectable contraceptives compared with other contraceptives, and by pictures of a struggling agricultural people for whom anything less than impeccable contraception will mean the collapse of a way of life.

We all tend to listen only to what we want to hear, and no doubt "hawks" and "doves" on the issue of drug safety each drew different conclusions from this programme. For my part, the pictures of stoical Thai peasants convinced me that they are as capable as any other community of making sound decisions. I did not feel that Edward Goldwyn's brilliantly controlled script pressed me to that conclusion—though perhaps that is an indication of his art. His intelligent film quietly demonstrated to me the limitations of my urban British experience.—JAMES OWEN DRIFE, lecturer in obstetrics, Bristol.

Br Med J (Clin Res Ed): first published as 10.1136/bmj.284.6318.803 on 13 March 1982. Downloaded from http://www.bmj.com/ on 18 April 2024 by guest. Protected by copyright.