

age at successive deliveries and at last delivery (positively correlated); height and stature (weight:height) at biopsy (younger women were taller and slimmer); and concentrations of oestrogen and progesterone receptors in the tumour.<sup>4</sup> Possibly less direct indicators of age were also positively related: the number of children, how long she had nursed them, whether she had a sister with breast cancer, and the time between discovery of disease and biopsy.

To separate analytically the effects of aging from other causes that alter the age at diagnosis of breast cancer, data are needed on age-matched women of similar origins who do not have cancer.

We thank Dr Robert L Egan for access to his data files, which permitted independent verification of parts of our data.

<sup>1</sup> Olsson H, Brandt L. Relation between age of mothers with breast cancer and sex of their children. *Br Med J* 1980;**281**:1029-31.

<sup>2</sup> Elwood M, Coldman A. Age of mothers with breast cancer and sex of their children. *Br Med J* 1981;**282**:734.

<sup>3</sup> Korenman SG. The endocrinology of breast cancer. *Cancer* 1980;**46**:874-8.

<sup>4</sup> Kiang DT, Kennedy BJ. Factors affecting estrogen receptors in breast cancer. *Cancer* 1977;**40**:1571-6.

(Accepted 28 October 1981)

Joseph B Whitehead Department of Surgery, Robert Winship Memorial Clinic, Emory University School of Medicine, Atlanta, Georgia 30322, USA

YOLANDA A DURALDE, MD (Department of Family Practice, University of Cincinnati, Ohio)

ROBERT H BYERS, PHD, assistant director, Emory University computing centre

CHARLES D STEVENS, PHD, professor emeritus of biometry

RALPH WALDO POWELL, MD, associate professor of surgery

## “Non-accidental injury” and wild parsnips

Phototoxic dermatitis may be caused by many plants (phytophotodermatitis), especially those of the genus *Umbelliferae*.<sup>1</sup> The linear and often bullous skin lesions may have a bizarre appearance. We describe a patient who presented in unusual circumstances.

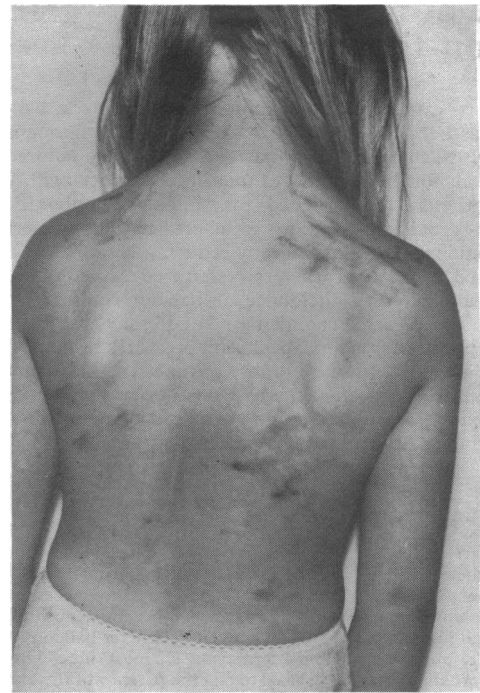
### Case report

In August 1980 an 8-year-old girl was visited by a social worker in connection with a forthcoming holiday. Her family was well known to the social services department owing to previous child neglect. The girl was noted to have extensive linear and blistering skin lesions, which the social worker thought might have been inflicted by the father with a whip or a lighted cigarette. The child and her parents were referred to hospital the same day. The parents stated that skin lesions had been present for 10 days, and the father repeatedly and indignantly protested that he had not touched her. The child denied any ill treatment.

The lesions were most prominent on the trunk, especially the back and shoulders (figure), but were also present on the forehead, hands, arms, thighs, and lower legs. Many lesions were linear with dusky redness consistent with whip marks, but closer inspection showed areas of brown hyperpigmentation. The lesions were recognised as those of phytophotodermatitis. It transpired that during recent sunny weather she had been playing on waste ground near her home wearing only her underpants. In view of the medicolegal aspects of the case a photographer subsequently visited the area with the child and photographed large quantities of wild parsnip (*Pastanaca sativa*), which was in full flower and starting to set seed.

### Comment

Wild parsnip is a common yellow-flowered umbelliferous plant growing to a height of about one metre. It contains at least three furocoumarins (psoralens)—namely, 5-methoxypsoralen, 8-methoxypsoralen, and 5-isopentenylloxypsoralen<sup>1</sup>—which act as photosensitisers. Development of lesions depends on exposure of the skin both to furocoumarins in the plant sap and to adequate amounts of long-wave ultraviolet irradiation.<sup>2</sup> The reaction is a phototoxic one and is not dependent on previous allergic sensitisation.<sup>3</sup> The severity of skin lesions ranges from erythema through oedema to blistering in severe cases.<sup>2,4</sup> Hyperpigmentation develops within a few days and is diagnostically helpful.<sup>4</sup>



Extensive skin lesions caused by phytophotodermatitis.

Furocoumarins are usually most abundant in mature plants that have flowered and set seed,<sup>1</sup> as in this instance. The usual time of presentation is in July and August, when the plants are fully developed, the weather is sunny, and children on holiday from school are playing out of doors, often wearing few clothes. The linear pattern of skin lesions corresponds to the areas of streaking of plant sap on to the skin from crushed or cut stems and leaves. The circumstances in which phytophotodermatitis was confused with non-accidental injury in this child were understandable. The prompt recognition of the true diagnosis enabled a potentially awkward and unpleasant situation to be rapidly defused.

We thank the audiovisual centre of Newcastle University for photographing the patient.

<sup>1</sup> Pathak MA, Daniels F, Fitzpatrick TB. The presently known distribution of furocoumarins (psoralens) in plants. *J Invest Dermatol* 1962;**39**:225-39.

<sup>2</sup> Jensen T, Hansen KG. Active spectral range for phyto-genic photodermatitis produced by *Pastanaca sativa*. *Archives of Dermatology and Syphilology* 1939;**40**:566-79.

<sup>3</sup> Epstein JH. Phototoxicity and photoallergy: clinical syndromes. In: Fitzpatrick TB, Pathak MA, Harber LC, Seiji M, Kukita A, eds. *Sunlight and man*. Tokyo: University of Tokyo, 1974:459-77.

<sup>4</sup> Sommer RG, Jillson OF. Phytophotodermatitis (solar dermatitis from plants). Gas plant and wild parsnip. *N Engl J Med* 1967;**276**:1484-6.

(Accepted 30 October 1981)

Department of Paediatrics, Newcastle General Hospital, Newcastle upon Tyne NE4 6BE

A N CAMPBELL, MB, MRCP, senior registrar (present address: The Hospital for Sick Children, Toronto, Canada M5G 1X8)

CHRISTINE E COOPER, OBE, MA, FRCP, consultant

University Department of Dermatology, Royal Victoria Infirmary, Newcastle upon Tyne NE1 4LP

M G C DAHL, MB, FRCP, consultant

### Correction

One year's treatment with propranolol after myocardial infarction; preliminary report of Norwegian multicentre trial

In the paper by Dr V Hansteen and others (16 January 1982, pp 155-160) the list of authors should contain the name of H P Dørum, MD, of the Central Hospital of Opland (Lillehammer).