Procedures in Practice

BENVON CRAMER
GERALD DE LACEY

INTRAVENOUS UROGRAPHY

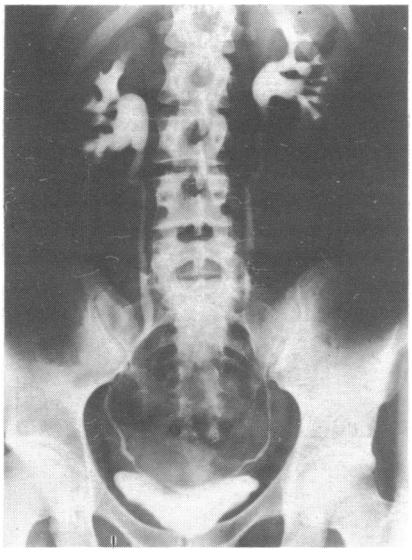

Intravenous urography is the most commonly performed radiological examination of the urinary tract. The information obtained is primarily anatomical, as the examination provides only a crude assessment of renal function. It is, however, highly accurate in delineating the size and shape of the kidneys, calices, and ureters. Most hospitals will have a basic routine procedure, but it must be modified to suit each individual patient. This may entail changing the radiographic technique, dose of contrast medium, and views obtained, and possibly using tomography.

Contraindications

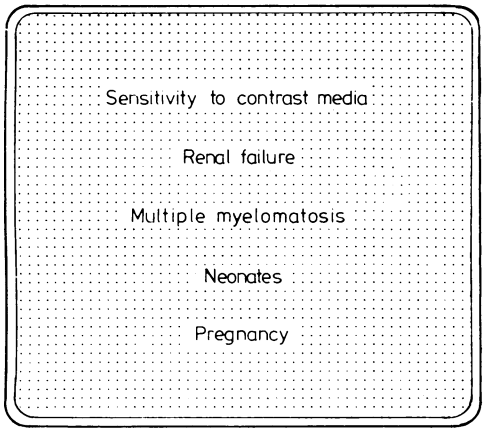

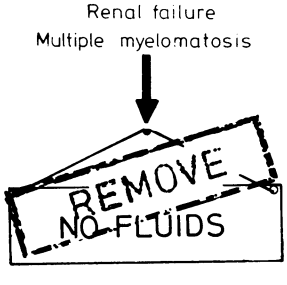

No absolute contraindications to urography exist but caution should be observed in five groups.

(1) Patients with known sensitivity to radiological contrast media.

(2) Patients with renal failure: transient rises in serum creatinine concentrations after high-dose urography have occurred. Care is particularly important in patients with diabetes mellitus and even mild renal failure.

(3) Patients with multiple myelomatosis.

(4) Neonates.

(5) Pregnant women.

Careful selection is essential in all these patients, and the radiologist will often suggest an alternative and safer procedure such as ultrasonography or isotope renography. For example, when ureteric or bladder-neck obstruction is suspected then ultrasonography will invariably confirm or refute this possibility. When excretion urography is regarded as essential in multiple myeloma or renal failure, however, then the patient should be well hydrated before the procedure. In renal failure dehydration may result in severe volume depletion, electrolyte imbalance, and worsening renal function. Preparing these patients requires more than removing the "no fluids" instruction on the ward. There is often a delay before urography is performed, which can effectively result in a dehydrated patient. It is important that the radiologist and referring clinician make arrangements to see that such inadvertent dehydration does not occur.

The possibility of irradiating an unsuspected fetus is minimised if the *x*-ray department institutes the "10-day rule"—that is, that women of reproductive age (12-50 years) will be booked for urography only during the first 10 days of their menstrual cycle.

Contrast media

Suggested dose of contrast medium according to patient's age and indication

Age and indication	Dose
Adults:	
Routine	50 ml sodium iothalamate (Conray 420)
Renal failure	2 ml meglumine iothalamate (Conray 280)/kg
Children:	
8-12 years	40 ml meglumine iothalamate (Conray 280)
4-8 years	20 ml meglumine iothalamate
< 4 years	2 ml meglumine iothalamate/kg to maximum of 20 ml

The media in use are the sodium and meglumine salts of tri-iodinated organic compounds, which are remarkably safe. Nevertheless, a small risk of hypersensitivity reaction exists and urography should not be undertaken unless equipment and drugs necessary for full resuscitation are readily available. Inquiry about a history of any allergy is always necessary, as the incidence of reactions is increased in atopic patients. Pretesting with small doses of media is now regarded as useless, but in high-risk patients premedication with corticosteroids is necessary, preferably during the 24 hours before the examination.

The choice of contrast medium will vary among radiology departments. There appears to be very little difference in the quality of the *x*-ray image obtained whether the sodium or meglumine salts are used. In patients with heart failure, however, it is advisable to avoid giving sodium ions (for example, sodium iothalamate (Conray 420)) and therefore to choose instead a meglumine salt (for example, meglumine iothalamate (Conray 280)).

Normal procedure in adults

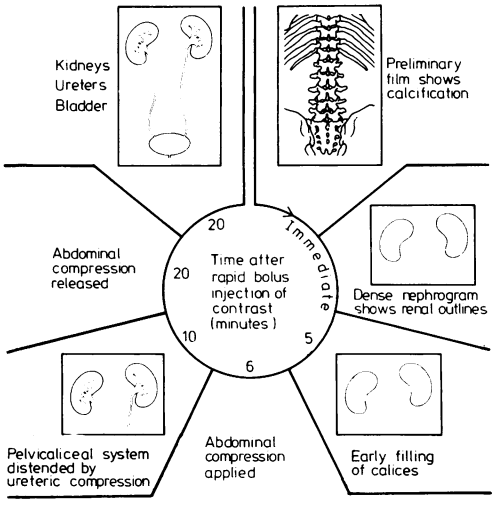

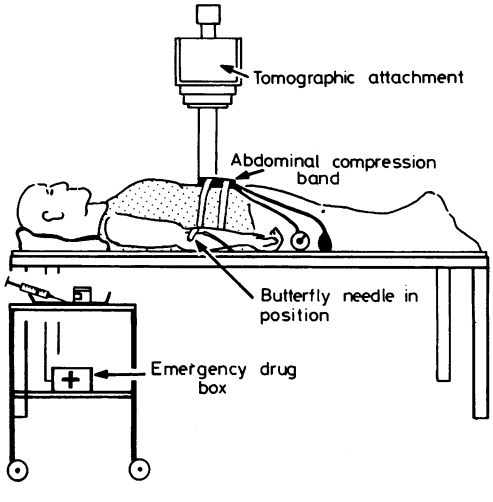

The basic procedure considered here may be modified according to the individual clinical problem. Laxatives are administered for two consecutive nights to remove faeces from overlying the kidneys. Dehydration increases the renal concentration of the contrast medium and improves opacification of the pelvicaliceal systems. Fluids are therefore withheld for 12 hours before urography.

After the patient enters the *x*-ray department he empties his bladder and a control abdominal film is obtained. This will show opaque calculi and also permits adjustment of the radiographic technique. The patient is always placed supine before the injection of contrast because of the risk of hypotension. In addition he must not be left unattended during the 20 minutes after injection so that any reaction may be detected and treated without delay. Contrast is injected as a rapid bolus to obtain the high serum concentration necessary for a dense nephrogram. A good nephrogram (the radiographic image of the renal parenchyma) shows the outline of the kidneys immediately at the end of the injection. This film reduces the necessity for tomography or oblique views, which might otherwise be required to show the precise outline or size of the kidneys.

A second film is taken five minutes later to show early filling of the calices. Abdominal compression is then applied (though not after recent abdominal surgery, acute abdominal pain, or suspected ureteric colic) to compress the ureters and distend the calices. A further radiograph of the renal areas is obtained at 10 minutes primarily to show the calices and renal pelvis. Compression is released at 20 minutes and a full-length film immediately obtained to show the ureters and bladder. Films of the bladder after micturition are taken only when assessing obstruction of the bladder neck. They are not indicated as a routine procedure, particularly in women.

Procedure in children

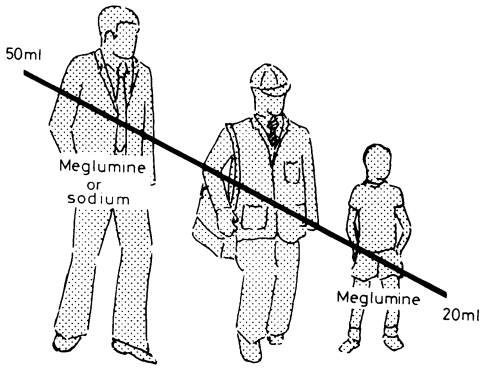

For children, infants, and neonates a different approach is required. The volume of contrast is reduced in relation to body weight, the number of exposures reduced to a minimum, and gonad protection used whenever possible. The clinical indications for urography in neonates are few, and when the procedure is indicated isotopes or ultrasonography will usually and more safely solve the clinical problem. These investigations should precede urography in neonates in most instances.

In children aged under 4 years a meglumine salt is chosen to avoid the hazards of hypernatraemia, and the contrast medium should be injected slowly over several minutes to avoid a sudden rise in plasma osmolarity. In older children eight hours of dehydration suffices and the volume of contrast is reduced.

Special circumstances

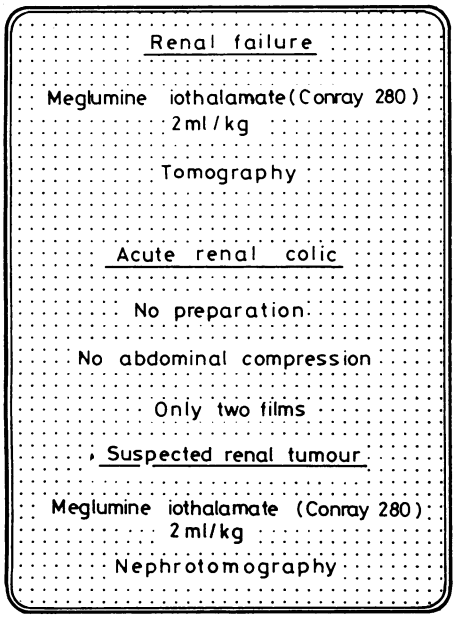

In certain circumstances the standard procedure for intravenous urography must be altered. Renal failure and multiple myeloma have already been mentioned, and the need for careful selection is emphasised. When urography is regarded as essential in renal failure then the dose of contrast medium is increased to 2 ml meglumine iothalamate (Conray 280)/kg and tomography should be routinely available to help delineate the poorly opacified calices and renal parenchyma.

In acute renal colic the investigation is performed without preparation. Abdominal compression is not applied, and two films—a control and a 10-minute film—are often sufficient to confirm or exclude the diagnosis.

When a renal tumour is suspected then a high dose of contrast (for example, 2 ml meglumine iothalamate/kg) with immediate nephrotomography will disclose or exclude a mass and usually distinguish between a simple cyst and a hypernephroma.

Complications

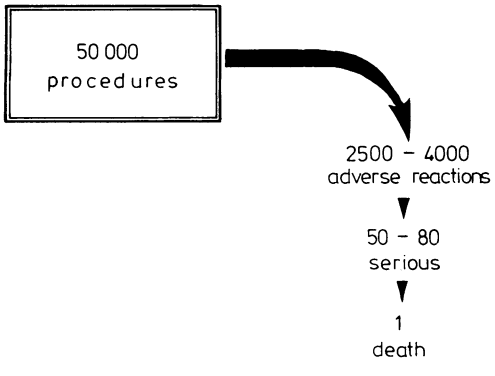

Death due to a reaction to contrast media is rare, the incidence being about one in 50 000. Adverse reactions of various types and severity occur in 5-8% of patients, but fewer than 2% of these are clinically important. Reactions occur usually within the first 10 minutes after injection but occasionally are delayed. They are mostly mild and include sneezing, pruritus, hives, and minor bronchospasm. When treatment is required an antihistamine, administered intravenously, usually induces a rapid symptomatic response. Severe reactions, including cardiac arrest, are extremely rare but do occur, and the *x*-ray department must always have facilities and a protocol available for immediate resuscitation.

Dr Benvon Cramer, MB, MRCP, is a registrar and Dr Gerald de Lacey, MB, FRCR, a consultant at the department of diagnostic radiology, Northwick Park Hospital and Clinical Research Centre, Harrow, Middlesex.