option to make 10% of their salary through private practice may not find it easy.

Working well

The NHS does seem to work better in Dumfries and Galloway than in some other parts of the country, where financial cuts, industrial disputes, old buildings, difficulties in recruiting staff, long waiting lists, and failing morale have all taken a toll. Some of the factors that contribute to the harmony cannot be copied: the beautiful country, the smallness, the absence of superspecialties, the legacy of a large and beautiful psychiatric hospital, and the relative insulation from industrial disputes. But some lessons can be learnt: one rather than three tiers of administrators does not abolish complaints about bureaucracy, but it does seem to permit easier administration; good facilities—both professional and social—help enormously; and good relationships between doctors—sponsored by frequent professional and social meetings—are most important.

Lesson of the Week

Pseudomonas ophthalmia neonatorum: a cause of blindness

GAYNOR F COLE, DAVID P DAVIES, DAVID J AUSTIN

Gonococcal ophthalmia used to be an important cause of "sticky eyes" in babies and frequently led to blindness. "Sticky eyes" is still a problem in the newborn nursery, the commonest causative organism being the staphylococcus, but serious sequelae are fortunately now rare. Although panophthalmitis of the newborn due to *Pseudomonas aeruginosa* is well recognised, its seriousness has not been widely emphasised. We describe an infant who developed pseudomonas ophthalmia and this led to loss of vision in one eye.

Accidental trauma to the eyes of babies with conjunctivitis due to pseudomonas may cause blindness.

Case report

A boy was born at 32 weeks of gestation, weighing 1475 g. He developed the respiratory distress syndrome and was treated for five days with continuous positive airways pressure (CPAP) by mask. Because of prolonged rupture of membranes the baby was started on penicillin and gentamicin. Subsequent serum gentamicin concentrations were in the therapeutic range. Jaundice of prematurity was treated with phototherapy, during which time the eyes were covered with gauze pads.

On day 10 a pure growth of *Pseudomonas aeruginosa* was cultured from the infant's stool, and a day later there was a purulent discharge from the left eye. Swabs from both eyes showed Gram-negative bacilli, and treatment with gentamicin eye drops was started. Treatment with intramuscular penicillin and gentamicin was continued. Despite this intensive treatment the eyelid and conjunctiva became very oedematous. Two days after the discharge was noted, a gelatinous body was found in the cot: the lens of the left eye. Examination by an ophthalmologist (DA) showed a large perforated corneal ulcer through which the lens had been extruded. The right eye, although continuing to discharge pus, was normal. Culture of the pus from both eyes grew *Pseudomonas*, which was sensitive to gentamicin. Systemic and topical gentamicin was continued for one week after swabs from both eyes became sterile. Somewhat remarkably, the baby's general condition throughout remained good. He was last seen in the baby clinic at the age of two months. The right eye was healthy but the left eye showed severe corneal opacification (figure).

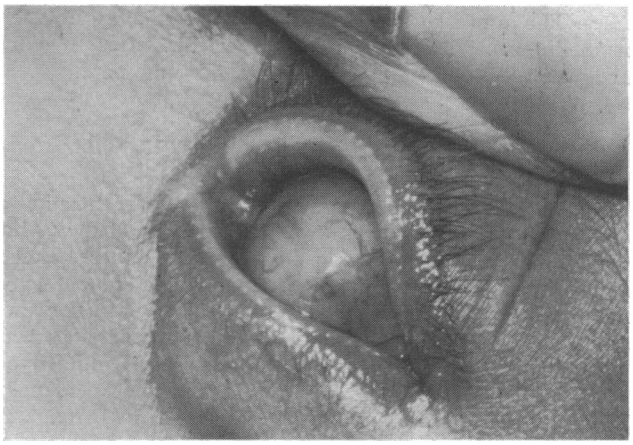

Left eye at the age of two months showing complete corneal opacification.

Comment

In a recent survey pseudomonas accounted for only 0·5% of neonatal eye sepsis.[1] There are few references to blindness caused by neonatal pseudomonas panophthalmitis,[2 3] but there is increasing knowledge about this condition in the adult eye, where it may be associated with intraocular operations or corneal abrasions.[4] This suggests that infection of the conjunctiva with *Pseudomonas* is not in itself enough to produce a panophthalmitis.

Department of Child Health, University of Leicester
GAYNOR F COLE, PHD, MRCP, paediatric registrar
DAVID P DAVIES, MD, MRCP, senior lecturer

Leicester Royal Infirmary
DAVID J AUSTIN, FRCS, DO, consultant ophthalmologist

If there is corneal trauma, however, pseudomonal endotoxins may penetrate the cornea causing a perforating ulcer and hypopyon. Rapid perforation of the globe may result. The eye is effectively separated from the rest of the body by the blood-aqueous humour barrier with similar properties to the blood-brain barrier so that antibiotics, given either topically or parenterally, will frequently not give adequate intraocular concentrations to arrest the progression of the infection. In the adult eye[5] regular 24-hour sub-Tenon injections of gentamicin (20-40 mg) combined with intramuscular gentamicin have produced adequate intraocular concentrations and contained the disease. In our baby *Pseudomonas* was isolated from both eyes but the panophthalmitis was unilateral, suggesting that there may have been a predisposing cause in the left eye—for example, a congenital abnormality. It is more likely that the left cornea was previously injured, possibly by the CPAP mask, the phototherapy eye pads, the careless administration of antibiotic drops, or even by self-inflicted injury.

We have learned several lessons from this sad case. Great care must be taken to avoid injuring the cornea when using face masks and eye pads. When *Pseudomonas* is isolated on a neonatal unit, prompt diagnosis of any sticky eye is indicated. Gram staining of the discharge should be done urgently as should taking swabs for culture. If *Pseudomonas* is suspected frequent examinations for corneal abrasion should be made and if confirmed, sub-Tenon injections of gentamicin should be considered, although this would be a formidable task in the newborn. The potential hazard of the sticky eye, familiar though it is in the neonatal nursery, should never be underrated.

Reprint requests should be sent to Dr G F Cole, Special Care Baby Unit, Leicester Royal Infirmary, Leicester LE1 5WW.

References

1 Armstrong JH, Zacarias F, Rein MF. Ophthalmia neonatorum: a chart review. *Pediatrics* 1976;**57**:884-91.
2 Drewett SE, Payne DJM, Tuke W, Verdon PE. Eradication of Pseudomonas aeruginosa infection from a special-care nursery. *Lancet* 1972;i:946-8.
3 Burns RP, Rhodes DH. Pseudomonas eye infection as a cause of death in premature infants. *Arch Ophthalmol* 1961;**65**:517-25.
4 Ayliffe GAJ, Barry DR, Lowbury EJL, Roper-Hall MJ, Walker WM. Postoperative infection with Pseudomonas aeruginosa in an eye hospital. *Lancet* 1966;i:1113-7.
5 Golden B. Sub-tenon injections of gentamicin for bacterial infections of the eye. *J Infect Dis* 1971;**124**,suppl:271-4.

(*Accepted 28 May 1980*)

What evidence is there that damp houses cause (a) respiratory disease, (b) rheumatic complaints, or (c) any other illness?

There is no evidence that damp houses cause respiratory disease or rheumatic complaints, but they certainly aggravate these conditions. Damp houses are usually cold and draughty and have the following adverse effects: (*a*) Respiratory disease—the chilling and local ischaemia of the upper respiratory tract encourage exacerbations of the existing respiratory disease and also increase the tendency to bronchospasm. (*b*) Rheumatic complaints—the chilling effect of the cold and damp tends to reduce the desire to move about so that body heat is lost. This leads to increased stiffness, discomfort, and pain. Damp houses are also often overcrowded, which facilitates the spread of spray or droplet infections. Other conditions, such as chilblains and chronic upper respiratory catarrh, are more common in damp houses owing to the fluctuations in temperature and humidity.

Is there any way of determining the side of the brain in which the language function lies, without making a destructive lesion?

I know of no certain way of determining the side of the brain in which the language function lies without making a destructive lesion. Most people have their dominant (and hence language function) hemisphere on the left. If the patient is and has been conclusively right handed the dominant hemisphere will almost certainly be on the left. If the patient has been left handed, then the dominant hemisphere may still be on the left, though there is an increased chance of it being on the right. Electroencephalographs performed on normal people show a tendency for lower voltage alpha-waves on the dominant side. This test could be useful, though not completely reliable. Generally speaking the combination of this and the clinical condition as regards handedness will give a satisfactory answer as to which hemisphere is dominant.

What is the usual age at which emission of semen first occurs?

There are very few data on this subject. Testicular biopsy indicates that incomplete spermatogenesis begins in the earliest maturing boys at about 10 years of age. Spermaturia has been shown to occur at a mean chronological age of 13·3 years in a Scottish population and was earliest detected in a boy of 12·2 years.[1] The ability to produce semen probably accompanies early enlargement of the testes and precedes the onset of the height spurt. The ability to produce an ejaculate antedates the production of sperm but does not occur as early as the onset of masturbation, which was reported by Kinsey *et al*[2] to start in boys at about the age of 8.

1 Richardson DW, Short RV. Time of onset of sperm production in boys. *J Biosoc Sci* 1978;suppl 5:15-25.
2 Kinsey AC, Pomeroy WB, Martin CE. *Sexual behaviour in the human male.* Philadelphia: Saunders, 1948.

Can copper IUCDs cause systemic allergic reactions?

Systemic action from copper-releasing intrauterine devices is unusual and can generally be discounted. Barkoff,[1] however, reported a case of copper allergy presenting with urticaria, joint pains, and angioneurotic oedema one month after insertion of a copper IUCD. Positive scratch tests confirmed the diagnosis of sensitivity to copper. Eosinophilia has also been noted in some women using copper IUCDs, but a direct relation to the copper is not always evident. Other systemic allergic signs may occur. In the present case the best test would be to remove the IUCD. If the symptoms resolved a further "test" would be to reinsert the IUCD. If the symptoms then recurred she should change to another type of contraceptive.

1 Barkoff JR. Urticaria secondary to a copper intrauterine device. *Int J Dermatol* 1976;**15**:594-5.

During the inter-war depression when butter was much more expensive than tasteless margarine an organic chemist told me that margarine makers did not add butyric acid for taste because it was illegal. Chemists could tell real butter only by the presence of butyric acid. For the sake of our cardiovascular patients would it now be legally possible and chemically safe to give margarine a taste—like butter?

The taste or, more accurately, the flavour of butter is due to a complex mixture of chemical components and the simple addition of butyric acid to margarine would not in itself produce a butter-like flavour. Over the past 30 years extensive research into the flavour of butter has resulted in the evolution of permitted flavourings that can be added to margarine to simulate closely a range of butter flavours. Some premium margarines do, in fact, have a flavour that many people find difficult to distinguish from that of butter and others prefer to butter. Much bias and preconception, however, exists as few people test their preferences or ability to distinguish between the different products under "blind," unbiased conditions.

What are the hazards, if any, associated with tungsten carbide used for cutting and drilling machinery? Are there any specific precautions that should be taken?

A few workers subjected to hard-metal (cemented tungsten carbide) dust develop asthmatic symptoms that are usually mild, although in some subjects an unresolving alveolitis may develop. Removal from exposure in the early stages of the disease, however, seems to result in complete remission. The cobalt binder is thought by some to cause the disease, although tungsten and not cobalt has been found on postmortem analysis of the lungs of hard-metal workers.