

to have "fallen back in a faint" each time she attempted to sit up, but she was not completely unconscious, since she was capable of understanding what was said to her. She was cold and shocked and pallid when the vertigo occurred. The next day she was able to sit up in bed without vertigo, and no nystagmus was present. She was "light-headed" for about two weeks after this attack, and sudden movement produced mild vertigo.

Case 6

This case is of special interest in that the patient was a next-door neighbour of Case 4. It is of interest, too, because the onset of his symptoms was just over 48 hours after that of his neighbour. A history of contact is available: on the morning of January 10, 1952, the patient sent for medical aid for Case 4. He then went into his neighbour's house to inform him that the doctor would soon arrive, and spent about five minutes in conversation.

The patient, a man aged 49, went to the cinema with his wife in the afternoon of January 12. To use his own words, he "felt as fit as a fiddle." After about half an hour he suddenly found that the screen was "beginning to wobble." He decided that this was due to the fact that he was sitting nearer to the screen than was his custom. The feeling passed off in a few minutes, only to recur. That too passed off, and he remained for another two hours, until the programme had finished. When he arose to leave the vertigo suddenly returned, so that it became necessary to hold on to his wife lest he should fall. Outside he felt much better and returned home by bus—a distance of about 10 miles. After entering the house the vertigo returned with great intensity, and at one stage it seemed as if the floor on his left occupied the position where the ceiling ought to have been on his right. The whole room seemed to rock and sway, but he himself did not appear to move. In a few minutes he was violently sick and the sickness lasted for about one hour, after which he managed to retire to bed and fell asleep exhausted. The next morning his "stomach was upset," but there was no further vomiting or vertigo. He returned to work on the 14th. On January 31 he stated that he had a slight feeling of falling when he was stepping forward. This lasted two or three days and then passed off. The symptoms were purely subjective, and he did not experience true vertigo.

He first came to see me on February 7 because since his illness on January 12 he had suffered from "palpitation, heartburn, and light-headedness," and seemed to have indigestion and flatulence after meals. Clinical examination showed his heart to be sound, and his blood pressure to be 150/94 mm. Hg. He had had a partial thyroidectomy in 1922 for parenchymatous goitre, otherwise his previous history was of no special interest.

On March 6 he was examined by an otorhinologist, who reported: "There was no obvious cause in the way of a precedent cold, earache, or general disturbance. Both drum-heads appeared normal. In both ears air conduction was better than bone conduction, and the Weber test was negative. Audiometry shows a very slight loss of hearing in the left ear as compared with the right, but the bone-conduction readings are virtually normal for this instrument. With cold caloric tests with water at 60° F. (15.6° C.) on the right, vertigo and nystagmus began after 45 seconds and cleared in 110 seconds. On the left it began at 30 seconds and ceased at 135 seconds. These figures show slightly increased irritability of the left labyrinth, but are really almost normal within the limits of the test."

Discussion

These six cases present as cases of acute labyrinthitis of uncertain aetiology. It is interesting that five of them occurred between November 10, 1951, and January 15, 1952. Another case in the same district was seen by a colleague of mine in January, 1952. In all cases the onset was extremely sudden, the patient feeling perfectly well one minute and having vertigo a moment later. There was

no previous malaise or pyrexia, I was unable to find any aural pathology, and there was no complaint of deafness. The average age of the patients was 54 years, and they all had been, and continue to be, in reasonable health. No treatment was required except rest in a dark room and small doses of phenobarbitone.

There is a great risk in trying to draw a conclusion from a small number of cases followed up for such a short time. I believe, however, that this may prove to be another manifestation of virus disease, the view being suggested by the history of contact between two next-door neighbours who developed similar symptoms within three days. I have not been able to establish any means of contact between the other cases. I suggest, however, that, like anterior poliomyelitis, the disease may be spread by carriers, that sub-clinical attacks occur, and that mild forms of the disease may pass unrecognized.

Summary

Six cases of acute labyrinthitis seen in general practice within one year are recorded; it is suggested that the disease is spread by a virus.

I wish to thank Mr. A. D. Bateman for his report on Case 6.

REFERENCES

- Brain, W. Russell (1947). *Diseases of the Nervous System*, p. 75. London.
 Buzzard, E. Farquhar (1945). In *Index of Differential Diagnosis of Main Symptoms*, edited by H. French, p. 921. Bristol.
 Law, F. W. (1945). *Ibid.*, p. 513. Bristol.
 Purves-Stewart, J. (1945). *The Diagnosis of Nervous Diseases*, p. 299. London.
 Tidy, H. L. (1945). *Synopsis of Medicine*, p. 1049. Bristol.

A CASE OF PHLEGMASIA CERULEA DOLENS

BY

D. P. B. TURNER, F.R.C.S.

Senior Surgical Registrar, Clatterbridge General Hospital,
Bebington, near Liverpool.

The so-called "blue phlebitis," or phlegmasia cerulea dolens, was first described by Trémolières and Véran (1929), and De Bakey and Ochsner (1949) state that since then a further 32 cases have been recorded, mostly in the French literature. Because of the importance of early recognition and treatment of those cases associated with peripheral circulatory collapse, and because it is possibly not widely known that many cases are in fact associated with peripheral circulatory collapse, the following case is put on record.

Case History

A woman aged 67 was admitted to hospital on the evening of December 13, 1951. She had felt quite well until early that morning, when her left leg became swollen; it progressively increased in size, and ached a little in the calves and later in the posterior aspect of the thigh. She remained in bed for most of the day, and at about 4 p.m., some eight hours after the onset, she suddenly collapsed with severe pain in the left groin and hypogastric region associated with vomiting. The pain was intermittent and colicky in type, and she vomited four times. The bowels had been regular until the day previously, but had not been opened for 24 hours. There was slight frequency of micturition, and the patient thought she had been losing weight recently. The past history revealed nothing significant.

On examination the patient was seen to be well-nourished. She was in severe pain and was obviously shocked. Her face was pale and there were beads of cold sweat on her forehead. The pulse was 116 and of poor volume; blood

pressure 95/65. Her left leg was very swollen and of a deep violaceous colour. The colour was most pronounced below the knee, and gradually faded as it progressed up the thigh to merge with normal-coloured skin over the lower abdomen. There was great tenderness over the line of the ilio-femoral vein, extending well up into the L.I.F. The temperature of the leg was quite normal and the femoral and dorsalis pedis pulses were easily felt; the posterior tibial and popliteal pulses were, however, not felt. Abdominal examination revealed active peristalsis, no distension, and deep tenderness and slight guarding in the L.I.F. Rectal and vaginal examination revealed no abnormality. Examination of the respiratory, central nervous, and cardiovascular systems revealed no abnormality except the evidence of peripheral circulatory failure already mentioned.

A diagnosis of deep femoral thrombosis was made, but at that time the reason for the peripheral circulatory failure was not appreciated, and the possibility of a silent—that is, painless—coronary thrombosis with secondary femoral vein thrombosis due to the fall in the blood pressure was considered.

Heparin, 8,000 units six-hourly, was given intravenously for 48 hours, controlled by 12-hourly estimations of the coagulation time, together with ethyl biscoumacetate ("tromexan"), four tablets in the first 24 hours, three tablets in the second 24 hours, and thereafter as indicated by the prothrombin index. Owing to the persistence of the signs of shock it was decided to give dextran intravenously. Although the possibility of a silent coronary thrombosis could not be excluded, it was thought that cautious intravenous therapy, keeping a careful watch for signs of basal congestion and venous distension, was unlikely to do her much harm and might do a lot of good. After 2 pints (1.1 litres) of dextran, given over a period of 12 hours, the patient's condition was much improved—her blood pressure had risen to 125/75, and the pulse had slowed to 80 and was of much better volume. The pain in the leg and abdomen subsided during the first 12 hours of anticoagulant therapy, and vomiting did not recur. The leg remained blue for approximately eight days, after which the colour gradually returned to normal. The swelling, however, took much longer to subside and was still partially present on the patient's discharge from hospital.

During her period of convalescence the red blood cells numbered 5,200,000, 4,900,000, and 4,850,000; the electrocardiogram showed no evidence of cardiac disease; and a barium enema showed the presence of multiple diverticula in the descending and sigmoid colon but no evidence of diverticulitis or of malignant disease of the colon. Sigmoidoscopy revealed nothing abnormal to just above the rectosigmoid junction.

The leg swelling had subsided sufficiently for the patient to be got up on January 4, 1952, but a crêpe bandage from the metatarsal heads to the groin was applied for support. Anticoagulant therapy was discontinued on January 8, and she was discharged home on January 13.

When she was seen again in the out-patient department on January 28 the leg was still moderately swollen, but she was quite well, and the leg became painful only after she had been up on it for several hours. A full-length elastic stocking had been supplied, and she was advised to rest in a recumbent position fairly frequently with the leg raised above the heart level.

The unusual blue colour of the swollen leg, so noticeable during the acute stage of the illness, led me to consult the literature on blue phlebitis, and it was only after this that the full significance of the patient's initial collapse and peripheral circulatory failure was fully appreciated.

Discussion

Blue phlebitis is undoubtedly much rarer than the well-known "white leg," or phlegmasia alba dolens. When the blue variety does occur, however, its onset may be sudden and dramatic, and if inadequately treated may lead to death.

The gravity of this form of venous thrombosis is shown by the fact that death occurred in 8 out of the 32 cases recorded, and in most of these death ensued shortly after the onset of the condition, the patient never recovering from the state of peripheral circulatory collapse.

It is interesting that in the above case the possibility of a cardiac lesion was seriously considered and almost led to the withholding of intravenous therapy, which is of such great importance in the treatment of the initial collapse and without which the patient may quite possibly have failed to recover.

Most of the reported cases conform to a fairly constant pattern, and the general march of events is usually as follows. The patient's first complaint is most often of pain, which comes on suddenly in the calf, thigh, or groin and eventually involves the whole limb. The pain is severe and sometimes agonizing, and is soon followed by signs of peripheral circulatory collapse. At the same time the leg becomes swollen and the colour changes develop. These are almost as dramatic as the other symptoms, the whole leg becoming suffused with a deep violaceous colour which is in marked contrast to the blanched appearance of the white variety of this thrombotic venous lesion. The time taken for the full development of this clinical picture varies, but is seldom longer than 30–45 minutes. Most cases have occurred in adults, and the sexes are affected about equally. The skin temperature on the affected side is likely to be lower than on the sound side, and the peripheral arterial pulses often become impalpable owing to the collapse. In some instances this has led to the unnecessary exploration of the main artery of the limb on the misdiagnosis of arterial embolism or occlusion (De Bakey and Ochsner, 1949). In some cases, however, including the one reported above, the peripheral arterial pulses remain palpable throughout. In those cases which survive the period of collapse the pain gradually subsides, the deep-blue colour gradually fades, and progress is not unlike that of phlegmasia alba dolens; there is, of course, the same likelihood of valvular destruction, leading to deep femoral incompetence and indurated leg.

Another type of acute venous thrombosis actually progresses to gangrene. This has been well described by Audier and Haimovici (1938) and Fontaine and Forster (1946). Haimovici and Suffness (1948) have published a report of a case which seems to connect the three different manifestations of deep thrombosis in the lower limbs. The case first showed the clinical picture typical of phlegmasia alba dolens; the leg then became cold and cyanotic, taking on the picture of phlegmasia cerulea dolens; and finally the toes and two areas on the plantar surface of the foot became gangrenous.

It seems probable, therefore, that deep thrombosis in the leg may lead to three different and well-marked clinical pictures—namely, phlegmasia alba dolens, phlegmasia cerulea dolens, and venous gangrene. Between these well-marked clinical types there will, of course, be intermediate grades showing a mixture of two or all three of the types. The extent and the rapidity of the thrombosis in conjunction with the state of the arterial system will determine the clinical picture in each individual case.

The type of case under discussion here does not as a rule proceed to gangrene but is particularly associated with sudden onset, deep violaceous discoloration, and the signs of peripheral circulatory failure.

Pathogenesis

Magendie and Tingaud (1945) remarked that the severity of the manifestations in this type of thrombosis suggests that coagulation occurs suddenly "with the brutality of a physico-chemical reaction." The initiating cause of this brutal reaction, however, remains obscure. That the arterial system is not also involved has been satisfactorily demonstrated by careful arteriograms, dissection of amputated extremities, necropsies, etc.

On the evidence available it seems that neither arterial nor venous spasm is responsible (Haimovici and Suffness, 1948; De Bakey and Ochsner, 1949). In most of the reported cases factors well known to predispose to venous thrombosis, such as polycythaemia vera, dehydration, cardiac failure, and prolonged recumbency, have been absent.

It is well known that phlegmasia alba dolens occurs commonly during the puerperium, and this also applies to the severe variety of thrombosis which leads to gangrene. Cases of phlegmasia cerulea dolens, however, do not seem to be specially associated with the puerperium, and none of the reported cases have occurred during that period.

Treatment

This can conveniently be considered from the aspect of the peripheral circulatory failure, of the thrombosis, and of the swollen limb. As regards the peripheral circulatory failure, it is important to recognize that this demands urgent treatment with intravenous fluids which remain within the cardiovascular system. Compatible blood, small pool plasma, or dextran may be used, the amount necessary depending on the degree of the collapse. Treatment of the thrombosis demands the usual combination of heparin and ethyl biscoumacetate, and anticoagulant therapy should be continued until the patient is ambulant. As neither venous nor arterial spasm seems to play an important part, sympathetic blocks, papaverine injections, etc., can reasonably be omitted.

Treatment of the swollen limb entails its elevation above the heart level until the swelling has subsided, followed by external support to the limb in the form of an elastic stocking or of crêpe bandages when the patient becomes ambulant. Persistent swelling of the limb despite these measures is no different from that following phlegmasia alba dolens, and the treatment of this is beyond the scope of this paper.

Summary

A case of phlegmasia cerulea dolens is described. Points of interest from the literature are discussed. Active treatment of the phase of collapse and peripheral circulatory failure is advocated. At the same time full doses of anticoagulants should be given. The further course is not dissimilar from that of the better-known phlegmasia alba dolens.

I wish to thank Mr. M. Silverstone for permission to publish this case and for his helpful criticism.

REFERENCES

- Audier, M., and Haimovici, H. (1938). *Arch. Mal. Cœur*, 31, 992.
De Bakey, M., and Ochsner, A. (1949). *Surgery*, 26, 16.
Fontaine, R., and Forster, E. (1946). *Lyon chir.*, 41, 173.
Haimovici, H., and Suffness, G. (1948). *Amer. J. med. Sci.*, 215, 278.
Magendie, J., and Tingaud, R. (1945). *Bordeaux chir.*, 3-4, 112.
Trémolières, F., and Vêran, P. (1929). *Bull. méd., Paris*, 43, 1101.

One of the difficulties confronting medical officers of health is alluded to by Dr. W. R. Perry, M.O.H. of Basford R.D.C., in his *Annual Report* for 1951. He refers to the elderly person who lives alone and, though not bedfast, is infirm and mainly dependent upon others. This type of person is often unwilling to leave home, but relatives and other interested people may bring considerable pressure to bear on the M.O.H. in an attempt to have their aged relative removed from home. Dr. Perry points out that compulsory removal from home can be undertaken only in certain restricted circumstances. Except under the Lunacy Acts, the person must be infirm or suffering from chronic illness, be living in insanitary conditions, be unable to devote to himself the necessary care and attention, and not be receiving such care from other persons. He also points out that, quite apart from the reluctance of most elderly people to leave home, it would be economically impossible for the nation to care for the majority of its aged persons in hospitals and institutions.

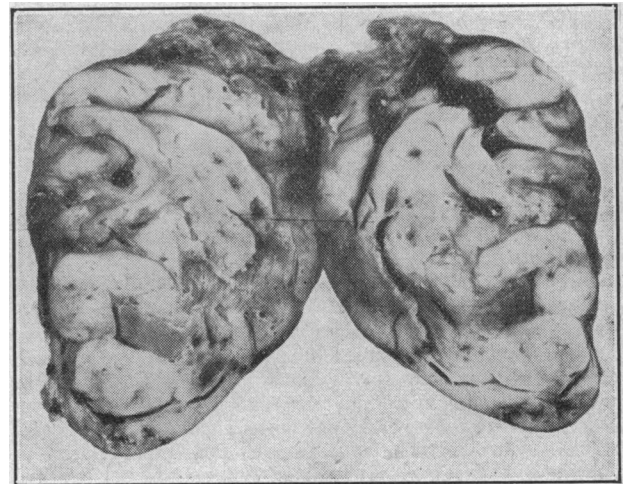
Medical Memoranda

A Case of Palpable Parathyroid Tumour

The following is a case in which adenoma of the parathyroid gland presented with simultaneous fractures of the necks of both femora.

CASE REPORT

A man aged 26 gave the following history. Four months before admission he complained of a painful swelling of the right knee following a minor degree of trauma. The effusion gradually subsided. Three months before admission he complained of increasing anorexia, nausea, and occasional vomiting; loss of weight, lassitude, constipation, and polyuria also occurred. During the two weeks before admission he complained of severe cramp-like pains in the muscles of the legs and trunk, but rarely affecting the arms. Suddenly while walking he collapsed with severe pain in both hips and was admitted to hospital.



Examination showed him to be a pale, wasted, ill-looking young man, obviously in great pain. Both hips were kept in the position of flexion. There was a well-defined swelling about 1 in. (2.5 cm.) in diameter in the neck just to the left of the midline and below the level of the cricoid cartilage. This swelling felt very much like a thyroid adenoma on palpation. His blood pressure was 115/80.

X-ray examination showed fractures of the necks of both femora. The general trabeculation of the upper ends of the femora was obviously coarse and abnormal, and there was marked thinning of the cortex. Further radiographs of other bones, especially the humerus and the small bones of the hand, showed similar evidence of decalcification. The characteristic cystic appearance of hyperparathyroidism was poorly shown. No renal calculi were seen in a straight radiograph of the abdomen.

Biochemical investigations yielded the following relevant results: serum calcium, 18.8 mg. per 100 ml.; serum phosphorus, 3.4 mg. per 100 ml.; blood urea, 74 mg. per 100 ml.; serum alkaline phosphatase, 43.5 K.A. units per 100 ml.; serum albumin, 3.8 g.%; serum globulin, 3.4 g.%; haemoglobin, 74%. The urine contained a trace of albumin, but no Bence Jones proteose was detected.

The fractures were treated by extension. In view of the clinical, radiological, and biochemical findings it was decided to make a surgical exploration of the neck. As the general condition of the patient was poor and the pain was severe and difficult to control, the operation was performed as soon as the above investigations were completed.

Operation.—On January 3, 1951, exploration of the neck was performed (W.D.P.) under general anaesthesia. Through a collar incision the palpable tumour was easily