laryngeal muscles showed neural atrophy and there were severe degenerative changes in the superior and recurrent laryngeal nerves and vagus. No indication as to the cause of this neuropathy was seen in the numerous sections examined. Such causes of nerve degeneration as vitamin deficiency, virus disease (Critchley, 1946), toxic effects from heavy metals, and amyloid (Missen and Taylor, 1956) were excluded. Thyroid disease was absent, and no tumour or disease process could be found in the mediastinum, thoracic inlet, neck, or nasopharynx. The brain-stem was normal, but the cerebrum showed several small scattered infarcts of varying age due to arteriosclerosis. As death had resulted from coronary thrombosis the possibility of ischaemic neuropathy was considered, but no evidence to support this could be found.

It is claimed that rheumatoid arthritis can produce both a polymyositis and neural atrophy due to pressure palsy on nerves by the diseased joint (Adams *et al.*, 1953). No evidence of polymyositis was found in the laryngeal muscles, while the vagus and its branches are sufficiently distant from joints likely to be affected by rheumatoid arthritis that a pressure palsy is not possible. No focal lesions in the nerves or muscles as described in rheumatoid arthritis by Freund *et al.* (1942), Steiner *et al.* (1946), and Cruickshank (1952) were found. The cause of the neuropathy in this case remains obscure (Ellis, 1946; Huppler *et al.*, 1956).

In Case 3 the cricoarytenoid joints were healthy, but the muscles again showed neural atrophy which had resulted from ischaemic neuropathy. Gross obliterative endarteritis of the vasa nervorum was found. A variety of vascular changes have been described in rheumatoid arthritis (Sokoloff *et al.*, 1951; Cruickshank, 1954; Ball, 1954; Bywaters, 1957). These ranged from intimal proliferation to a severe necrotic arteritis resembling polyarteritis nodosa. Vessels in the heart, muscles, and nerve sheaths were most frequently involved. The changes in the vasa nervorum could be of rheumatoid origin, while the severe calcification might have resulted from metastatic calcification in necrotic tissue from the bones of limbs kept fairly immobile by the joint disease or possibly as a superimposed arteriosclerotic effect. The leg ulceration and gangrene of the toes were regarded as further indication of generalized vascular disease of rheumatoid origin (Bywaters, 1957; Allison and Bettley, 1957). Systemic lupus erythematosus was considered as a possible diagnosis, but could not be substantiated.

Thus, although in cases of rheumatoid arthritis in which stridor develops involvement of the cricoarytenoid joint may be responsible, it is not the only factor, and nerve degeneration can be the cause. That this may be of ischaemic origin related to a "rheumatoid" arteritis of the vasa nervorum fits in with the wider concept of "rheumatoid disease" (Ellman and Ball, 1948; Cruickshank, 1957) as both a pathological and clinical entity, rather than "rheumatoid arthritis," in cases presenting unusual or more diffuse features.

### Summary

The difficulty of distinguishing between an arthritis of the cricoarytenoid joints leading to stridor and a bilateral abductor paralysis of the vocal cords is emphasized. Clinical examination may not provide sufficient evidence, and in the final analysis microscopical examination of the joints, muscles, and nerves is needed.

Five patients suffering from advanced rheumatoid arthritis are described, each of whom developed laryngeal stridor, and in four instances tracheotomy became necessary. Two of the patients died, and post-mortem examination revealed indisputable evidence of nerve degeneration and mobile cricoarytenoid joints, even though chronic inflammation of the joints was present in one case. In the second case the microscopical changes in the nerves appeared to be due to ischaemic neuritis resulting from a rheumatoid type of arteritis of the vasa nervorum.

Although rheumatoid changes in the cricoarytenoid joints do occur, it is suggested that in some cases the stridor is due to abductor paralysis resulting from nerve degeneration.

We wish to thank Dr. H. F. West, who referred Case 5, for his helpful advice; Mr. J. H. Cobb for his interest and for allowing us access to his records on Case 3; Dr. A. J. N. Warrack for carrying out the two post-mortem examinations; and Professor D. H. Collins for his valued opinion and useful criticism.

REFERENCES

Adams, R. D., Denny-Brown, D., and Person, C. M. (1953). *Diseases of Muscle*, p. 327. Hoeber, New York.
Allison, J. H., and Bettley, F. R. (1957). *Lancet*, **1**, 288.
Baker, O. A., and Bywaters, E. G. L. (1957). *Brit. med. J.*, **1**, 1400.
Ball, J. (1954). *Ann. rheum. Dis.*, **13**, 277.
Bywaters, E. G. L. (1957). Ibid., **16**, 84.
Copeman, W. S. C. (1957). *Brit. med. J.*, **1**, 1398.
Critchley, M. (1946). *Proc. roy. Soc. Med.*, **39**, 370.
Cruickshank, B. (1952). *J. Path. Bact.*, **64**, 21.
—— (1954). *Ann. rheum. Dis.*, **13**, 136.
—— (1957). *Proc. roy. Soc. Med.*, **50**, 462.
Ellis, M. (1946). Ibid., **39**, 364.
—— (1951). *British Encyclopaedia of Medical Practice*, 2nd ed., **7**, 629. Butterworth, London.
Ellman, P., and Ball, R. E. (1948). *Brit. med. J.*, **2**, 816.
Freund, H. A., Steiner, G., Leichtentritt, B., and Price, A. E. (1942). *Amer. J. Path.*, **18**, 865.
Hart, F. D., and Mackenzie, D. H. (1955). *Brit. med. J.*, **2**, 890.
Heptinstall, R. H., and Sowry, G. S. C. (1952). Ibid., **1**, 525.
Huppler, E. G., Schmidt, H. W., Devine, K. D., and Gage, R. P. (1956). *Amer. Rev. Tuberc.*, **73**, 52.
Missen, G. A. K., and Taylor, J. D. (1956). *J. Path. Bact.*, **71**, 179.
Montgomery, W. W., Perone, P. M., and Schall, L. A. (1955). *Ann. Otol. (St. Louis)*, **64**, 1025.
Pearson, J. E. G. (1957). *Brit. med. J.*, **1**, 1047.
Saunders, W. H. (1956). *A.M.A. Arch. Otolaryng.*, **63**, 260.
Sokoloff, L., Wilens, S. L., and Bunim, J. J. (1951). *Amer. J. Path.*, **27**, 157.
Steiner, G., Freund, H. A., Leichtentritt, B., and Maun, M. E. (1946). Ibid., **22**, 103.
De Vido, G., and Ancetti, A. (1952). *Minerva otorinolaring. (Torino)*, **2**, 479.

# CERVICAL MYELOPATHY PRESENTING AS PERIPHERAL NEUROPATHY

BY

**EDWIN CLARKE, M.D., M.R.C.P.**

*Late of the Department of Medicine (Neurology), Postgraduate Medical School of London, Hammersmith Hospital, W.12*

[WITH SPECIAL PLATE]

Considerable attention has recently been given to cervical spondylosis and its neurological complications (Brain *et al.*, 1952; Clarke and Robinson, 1956; Bradshaw, 1957). The term "spondylosis" refers to the chronic degenerative changes in the cervical spine occasioned by disk degeneration, which is usually the result of senile changes, but which may appear in the presence of congenital bony anomalies or as a delayed sequel to injury. The acute cervical prolapsed intervertebral disk does not come within the scope of the term, and it must be rigorously excluded from considerations of this subject, especially therapeutic. "Cervical myelopathy" has been used to describe those cases in which the neurological complication of spondylosis is manifested principally by a spinal-cord lesion, but some degree of coexisting root involvement can rarely be entirely excluded.

It is well known that the clinical results of nervous-tissue compression by cervical spondylosis are varied, both in their presenting features and in the eventual clinical picture. Thus it is possible to observe syndromes which may closely simulate known diseases of the nervous system. The commonest of these are disseminated sclerosis, cervical-cord neoplasm, motor neurone disease, and syringomyelia; but differentiation on clinical grounds alone is often possible. The possibility of coincidental cervical spondylosis with a neurological

Br Med J: first published as 10.1136/bmj.1.5082.1282 on 31 May 1958. Downloaded from http://www.bmj.com/ on 19 April 2024 by guest. Protected by copyright.

disease other than cervical myelopathy is, however, also an important consideration (*Lancet*, 1955; Bradshaw, 1957).

Cases of cervical myelopathy resembling peripheral neuropathy do not appear to be common, and the present paper describes two of them. Furthermore, they demonstrate a pathological feature which may be of aetiological importance in some cases.

### Case 1

A 62-year-old labourer was first seen as an out-patient on April 19, 1955. He worked in a soap factory, and for many years carrying sacks on his shoulders had been part of his job. For two weeks he had noticed a severe tingling of all his fingers and toes and the soles of his feet, which seemed to be aggravated by carrying heavy loads. For a similar length of time there had been paraesthesiae and tightness round his waist.

On examination, neck movements were found to be restricted and there were chronic degenerative changes of the finger-joints. The nervous system was normal except for some blunting to pinprick distally in the limbs, and slight impairment of vibration sense at the ankles, which may have been in keeping with his age. Radiographs of the cervical spine showed a severe degree of spondylosis, maximal at C4–5, but it was thought to be consistent with the patient's age and occupational habits.

The initial clinical impression was that of a peripheral neuropathy, but various inquiries and investigations did not reveal an aetiology. He was treated conservatively, but continued to complain of acroparaesthesiae and soon found that he was unable to hold small objects in his hands. While being observed in the out-patients' department he was found to have an increasing defect of vibration appreciation in the legs. Next extensor plantar responses, first on the left side and then bilaterally, became evident, and finally an inverted left supinator jerk appeared. His only additional symptom was severe pain in the neck produced by neck flexion.

He was now admitted to hospital, and his cerebrospinal-fluid contents were shown to be normal; however, when the neck was fully extended and the jugular veins were compressed there was a manometric block which could not be demonstrated with the neck in other positions. Myelography demonstrated a complete block at the C4–5 disk space (Special Plate, Fig. 1) with the neck in full extension; indentations of the radio-opaque material were both anterior and posterior. Smaller degrees of anterior indentation were present at other cervical levels, and throughout the spinal canal there was evidence of mild intervertebral protrusions.

As his symptoms were relatively mild, and as he had already begun to improve subjectively with physiotherapy alone, active treatment was not recommended. Since discharge from hospital 1½ years ago he has returned to work, but now has a light job and does not carry loads. He has been followed carefully as an out-patient, and despite the absence of specific treatment he continues to report definite improvement; there has, however, been little change in the abnormal neurological signs.

*Comment.*—There can be no doubt that the whole clinical picture in this case was due to the cervical-spine lesion, and it has been possible to observe it from an early stage of its existence. The truncal sensation is compatible with a cervical-cord lesion and has been described in this condition (Clarke and Robinson, 1956), but thoracic cord or root involvement by spondylosis, of which there was some myelographic evidence, could not be excluded.

### Case 2

A mechanical engineer aged 67, who had indulged in heavy labouring work, attended the out-patients' department on March 6, 1956, complaining of tingling and weakness of the fingers for six months. Furthermore, he had a peculiar sensation in the hands "as though they were covered with oil," and he found that he was unable to manipulate small objects such as buttons. For four months he had noticed a mild weakness of the legs. On examination, limitation of neck movements and slight weakness of the hands were found. The reflexes were all present and symmetrical and the plantar responses flexor. Distally, in the arms more than the legs, there was diminution of vibration and joint sense. Radiographs of the cervical spine showed a severe degree of spondylosis, but not more than might be expected for his age. It was thought that he had a type of peripheral neuropathy, but, as in Case 1, a search for an aetiological agent was fruitless and again he was treated conservatively and observed carefully.

While attending as an out-patient, however, signs of pyramidal-tract involvement became evident. His symptoms had not changed, and were limited to the hands and legs. Attention was now directed toward the cervical spinal cord and he was admitted to hospital. The cerebrospinal-fluid contents were normal, but a manometric block only with the neck in extension was found. Myelography proved that there was an almost complete block at the level of the C3–4 intervertebral disk space when the neck was fully extended. Again there was a posterior as well as an anterior component to the filling defect (Special Plate, Fig. 2) and the column of radio-opaque substance was deformed at other intervertebral levels.

The problem in this patient was very similar to that in Case 1, and he was also given physiotherapy to the legs as well as other non-specific measures. He has now been observed carefully for 1½ years, and, although showing little or no objective change, he reports continuing improvement and finds that his symptoms give him little trouble.

*Comment.*—Once more, despite the initial appearances, these and the subsequent developments can all be accounted for by the cervical-cord lesion due, as in Case 1, to both anterior and posterior compression at a single level. As in Case 1, the myelographic findings confirmed the manometric observations.

### Discussion

At the onset of their illness each patient had a combination of symptoms and signs which suggested a diagnosis of peripheral neuropathy. They had peripheral paraesthesiae or dysaesthesiae, and the clinical findings were in keeping with this conclusion. A search for an aetiological agent was in each case unsuccessful, and while under observation there was an increase of the sensory deficit and they showed evidence of pyramidal-tract involvement, attention being directed to the cervical region. They had both done heavy manual work, and each had limited neck movements with radiological evidence of severe cervical spondylosis; but, although a cervical-cord-compressing lesion had been considered initially, it was not thought to be likely. Subsequent events and the cerebrospinal-fluid and myelographic findings showed this opinion to be incorrect.

Craig and Shelden (1940) have pointed out the bizarre clinical results of a cervical-cord-compressing lesion, and it is possible to find cutaneous sensory alteration of a "glove and stocking" distribution in the limbs. Clarke and Robinson (1956) found this in three out of 120 cases of cervical myelopathy, and, as in the cases here described, it was associated with posterior column modality impairment. In both Cases 1 and 2 the sensory symptoms and signs were more marked in the upper limbs, and Daniels (1956) has described similar cases with cervical-cord lesions in which the same observations were made; his second case resembles the cases now reported both clinically and pathologically. The prominent sensory symptoms and signs are common to these cases and suggest involvement of the posterior portion of the spinal cord, and the posterior columns in particular. It is, however, difficult to correlate these clinical findings with the usually accepted pathogenesis of the cord lesion in cervical myelopathy, for anteriorly placed compression would be expected to produce more evidence of pyramidal-tract damage.

Br Med J: first published as 10.1136/bmj.1.5082.1282 on 31 May 1958. Downloaded from http://www.bmj.com/ on 19 April 2024 by guest. Protected by copyright.

There has been a good deal of discussion concerning the aetiological factors in chronic cervical myelopathy secondary to spondylosis, and it seems likely that several exist and are of varying importance in different cases. One of them, first suggested by Taylor (1953) and more recently by Schneider *et al.* (1954), Daniels (1956), and Bradshaw (1957), concerns the role of the ligamentum flavum which forms the posterior wall of the cervical spinal canal. In some elderly persons there is a permanent corrugation of this ligament related to the degree of disk degeneration, and when the neck is extended protrusion into the spinal canal is enhanced so that distortion of the posterior surface of the spinal cord occurs. Although visible at necropsy, it may have produced no symptoms during life. The anterior lesion produced by the extension of disk, osteophyte, and posterior longitudinal ligament into the spinal canal is likewise increased by neck extension and may also be symptomless. Thus either lesion may be silent when alone or at different levels, but if they are considerable and opposite each other the cord will be caught between two potent cord-compressing structures whenever the neck is extended, and a very severe degree of cord destruction may result (Clarke and Little, 1955). An exact correlation between the course of the disease and the known pathological findings is, however, notoriously difficult. The former is no doubt dependent upon the relative size of the anterior and posterior lesions as well as upon the other aetiological factors which have been postulated to account for the complex clinical picture characteristic of cervical myelopathy.

The myelograms in both Cases 1 and 2 demonstrated the two lesions very well, for in each there was a break in the column of radio-opaque material when the neck was in extension, but which was less apparent with the neck in a flexed or neutral position. Anteriorly a filling defect was readily seen, but posteriorly there was an equally significant one, shown best by Fig. 1 on the Special Plate.

The prognostic and therapeutic aspects of the cases described here are also of interest and importance. The benign course of the disease is demonstrated, but it is possible that, if serious cord compression is intermittent and occurs only with extension movements of the neck, a severe clinical picture would not be expected initially. Spondylosis, dependent as it is upon degeneration of the ageing intervertebral disk, is probably always progressive, and aggravation of the present state is therefore likely, although this advance may be very slow and at times imperceptible.

Despite the absence of active treatment, such as neck immobilization or surgery, the patients have each reported improvement, although objectively there has been little change. While the subjective improvement could be explained by the patients' becoming more attuned to their symptoms, there has nevertheless been no recent increase in signs. The first patient has stopped heavy work, and this is a well-recognized method of producing a temporary arrest or improvement. The importance of careful observation in this condition before advising surgical treatment is obvious. Should their condition deteriorate the patients will be advised to wear a collar, and if this is not effective a simple laminectomy with division of the dentate ligaments will be considered. In view of the nature of the lesion demonstrated, such an operation would be expected to give some relief.

### Summary

Two cases of chronic cervical myelopathy due to spondylosis are described. Each had a clinical picture which was initially ascribed to peripheral neuropathy, but it was eventually possible to demonstrate compression of the cervical spinal cord in both of them. The responsible lesion had two components, the more usual one involving the anterior surface of the cord, and a posterior one due presumably to corrugation of the ligamentum flavum and explaining, perhaps, the predominance of sensory features in these cases. Conservative treatment has led to symptomatic improvement, and the benign and lengthy course of this condition in some patients is emphasized.

REFERENCES

Bradshaw, P. (1957). *Quart. J. Med.*, **26**, 177.
Brain, W. R., Northfield, D., and Wilkinson, M. (1952). *Brain*, **75**, 187.
Clarke, E., and Little, J. H. (1955). *Neurology*, **5**, 861.
—— and Robinson, P. K. (1956). *Brain*, **79**, 483.
Craig, W. McK., and Shelden, C. H. (1940). *Arch. Neurol. Psychiat. (Chicago)*, **44**, 1.
Daniels, L. E. (1956). *Neurology*, **6**, 344.
Leading article (1955). *Lancet*, **1**, 187.
Schneider, R. C., Cherry, G., and Pantek, H. (1954). *J. Neurosurg.*, **11**, 546.
Taylor, A. R. (1953). *Lancet*, **1**, 717.

# AN UNUSUAL SITE FOR GRAVITATIONAL ULCERS

## SOME OBSERVATIONS ON A CASE OF DEEP-VEIN THROMBOSIS

BY

**J. A. WILLIAMS, F.R.C.S.**
*Registrar, Surgical Professorial Unit, Queen Elizabeth Hospital, Birmingham, 15*

[WITH SPECIAL PLATE]

Gravitational ulcers, a sequel of deep-vein thrombosis, are usually situated around or above the malleoli where perforating venous channels can be found (Cockett, 1955). Ulceration between the toes is uncommon, though it is described after sympathectomy for persistent gravitational ulceration (Linton, 1953).

Following thrombosis of the popliteal or superficial femoral veins, blood may return from the foot either through recanalized, and therefore valveless, deep veins or through the superficial veins. These superficial veins may already be varicose with incompetent valves, or may become incompetent as they dilate. There seems to be no evidence of a compensatory deep venous collateral circulation developing in any way comparable to the collateral circulation developed after an arterial blockage.

The common sequel of venous engorgement leading to ulceration is usually prevented by a strong elastic support, particularly the "blue line" elastic bandage. The case described here demonstrates how a "blue line" bandage promoted healing of the malleolar ulceration, but caused severe congestion of the toes with eventual ulceration. Evaluation of the clinical findings and a venogram led to the discovery of a satisfactory method of elastic support.

### Case Report

A machine attendant aged 35 complained of repeated painful ulceration between the toes of his left foot for the past twelve months. He had lost three months from work because of this. At the age of 15 he suffered a slipped epiphysis in his left hip, and when he was 22 he began to have pain in the same hip; this gradually got worse until January, 1953, when, at the age of 32, he underwent a subtrochanteric osteotomy. After the operation he was immobilized in a plaster spica for six months. One week after the plaster was removed he developed a deep-vein thrombosis in the left leg. This was treated by rest and support, but later when he was walking around on crutches the leg became swollen, and by December, 1953, five months after the thrombosis, he had areas of ulceration on the outer side of the ankle. This was treated with "blue line" elastic bandaging, and the malleolar ulcers healed and remained so. The bandages were comfortable, but he did notice that his toes were congested. Discoloration of the skin between the

Br Med J: first published as 10.1136/bmj.1.5082.1282 on 31 May 1958. Downloaded from http://www.bmj.com/ on 19 April 2024 by guest. Protected by copyright.

C. S. DARKE *ET AL.*: LARYNGEAL STRIDOR IN RHEUMATOID ARTHRITIS

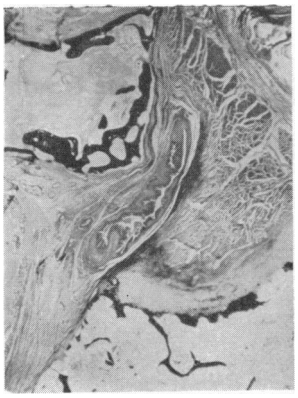

FIG. 1.—Longitudinal section of larynx (Case 1), showing thickened synovial membrane of cricoarytenoid joint. (×6.)

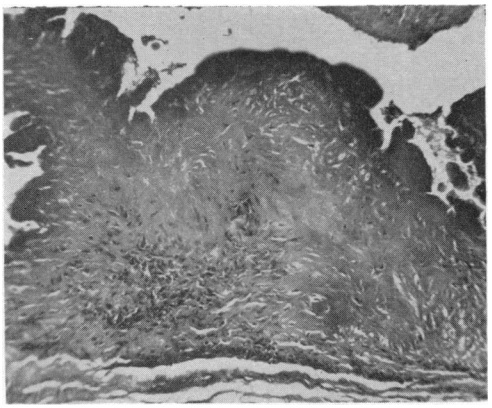

FIG. 2.—Higher power view of thickened synovial membrane of cricoarytenoid joint (Case 1), showing chronic inflammatory cells. (×98.)

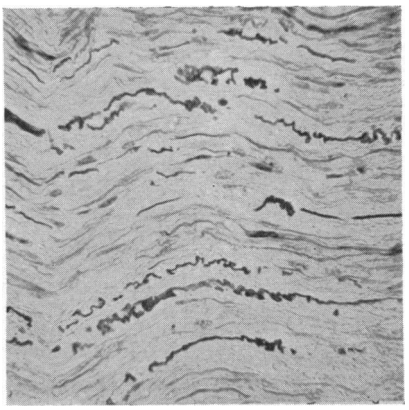

FIG. 3.—Lower part of left recurrent laryngeal nerve (Case 1), showing degenerate tortuous axis cylinders. (Silver stain. ×306.)

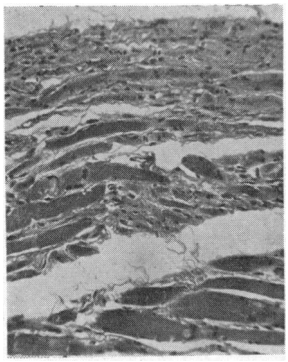

FIG. 4.—Longitudinal section of posterior cricoarytenoideus muscle (Case 3), showing neural atrophy. Bundles of atrophic fibres with increased numbers of nuclei are separated by larger intact fibres. (×86.)

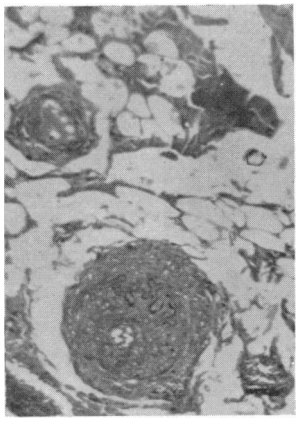

FIG. 5.—Vasa nervorum in left vagus (Case 3), showing severe intimal proliferation with reduction in size of lumen. (×60.)

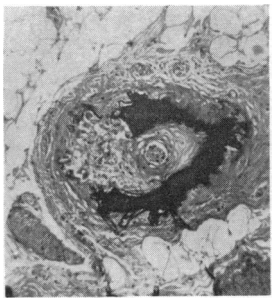

FIG. 6.—Calcification in intima and internal elastic lamina of artery supplying upper part of left recurrent laryngeal nerve (Case 3). Two minute channels are present in centre. (×56.)

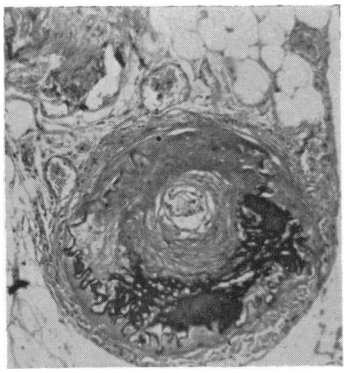

FIG. 7.—Similar calcification in vasa nervorum in lower part of left recurrent laryngeal nerve (Case 3). (×56.)

E. CLARKE: CERVICAL MYELOPATHY PRESENTING AS PERIPHERAL NEUROPATHY

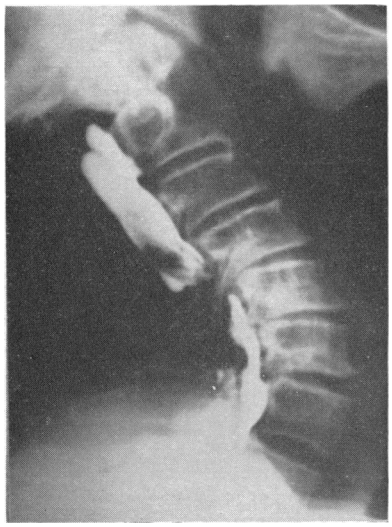

FIG. 1.—Case 1. Myelogram showing anterior and posterior filling defects in cervical region.

FIG. 2.—Case 2. Myelogram showing anterior and posterior filling defects in cervical region.

J. A. WILLIAMS: AN UNUSUAL SITE FOR GRAVITATIONAL ULCERS

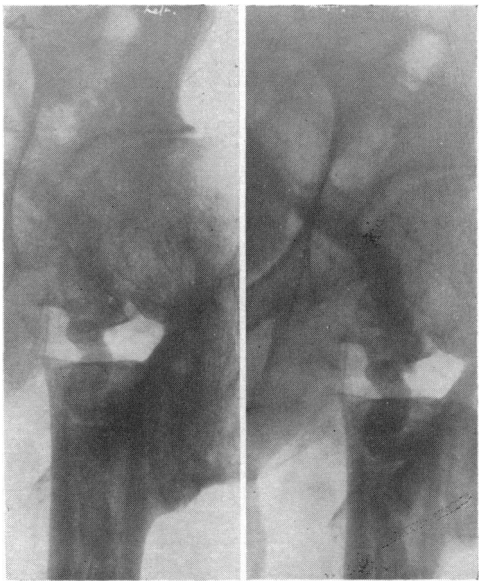

An apparently normal femoral vein has "concertinaed" following a femoral osteotomy. There is 2 in. (5 cm.) of shortening.

Br Med J: first published as 10.1136/bmj.1.5082.1282 on 31 May 1958. Downloaded from http://www.bmj.com/ on 19 April 2024 by guest. Protected by copyright.