

Clinical review

Treatment of bites by adders and exotic venomous snakes

David A Warrell

Nuffield
Department of
Clinical Medicine,
University of
Oxford, John
Radcliffe Hospital,
Oxford OX3 9DU
David A Warrell
professor of tropical
medicine and
infectious diseases
david.warrell@
ndm.oxford.ac.uk

BMJ 2005;331:1244-7

Every year, hundreds of people and unknown numbers of dogs and other domestic animals in England, Wales, and Scotland are bitten by our only indigenous venomous snake, the adder (*Vipera berus*) (fig 1). UK poisons centres are consulted about an average of 100 human and a dozen veterinary cases each year. In about 70% of patients, envenoming is negligible or purely local, causing pain, swelling, and inflammation of the bitten digit. Only 14 fatalities have been reported since 1876,¹ the last in a 5 year old child in 1975,^{w1} but adder bites should not be underestimated. On rare occasions, envenoming can be life threatening, especially in children, and many adults experience prolonged discomfort and disability after the bite.

Apart from the exotic venomous snakes held legally by zoos, research establishments, and licensed private individuals, large numbers of dangerous snakes are kept surreptitiously as macho pets in the United Kingdom, Ireland, and other countries.^{2 3 w2-w8} This "underground zoo"^{w9} reveals itself on average only five or six times each year in the UK when bitten owners are forced to seek medical help.⁴

Sources and selection criteria

I have based this review on personal experience in clinical research on snake bites and as an adviser to the National Poisons Centre since 1986 and to the Zoological Society of London and other UK zoos. Other sources were my personal archive of books, papers, and unpublished case reports; discussions and correspondence with other experts; and searches of Medline, PubMed, and Google.

Adder bites

The adder or viper (*Vipera berus*) is common throughout mainland Britain and some of the islands off the west coast of Scotland. Bites occur from February to October, peaking in June to August. Half the patients are bitten on the hand while picking up the adder.

Clinical features

Local envenoming—Immediate sharp pain is followed, usually within a few minutes but sometimes up to more than 30 minutes later, by a sensation of tingling and local swelling that spreads proximally. Local blisters containing blood are uncommon. Spreading pain, tenderness, inflammation (often described misleadingly as "cellulitis," although there is no infection), and tender enlargement of regional lymph nodes are sometimes



Fig 1 Adder or viper (*Vipera berus*)

noticeable within hours. Reddish lymphangitic lines and bruising appear, and the whole limb may become swollen and bruised within 24 hours (fig 2) with involvement of the trunk and, in children, the whole body (fig 3). Suspected intracompartmental syndromes and necrosis are very rare.^{w10}

Systemic envenoming—Dramatic anaphylactoid symptoms may appear within five minutes of the bite (see case history) or may be delayed for many hours. These include nausea; retching; vomiting; abdominal colic; diarrhoea; incontinence of urine and faeces; sweating; fever; vasoconstriction; tachycardia; light-headedness; loss of consciousness; shock; angio-oedema of the face, lips, gums, tongue, throat, and epiglottis; urticaria; and bronchospasm.^{5 w11} These symptoms may persist or fluctuate for as long as 48 hours in the absence of treatment. Hypotension is a most critical sign. It usually develops within two hours and may resolve spontaneously, persist, recur, or progress fatally. Clinical features of a bleeding diathesis are unusual,^{w12-w14} but bleeding from the gums and nose and into the lungs (fig 4),⁶ gastrointestinal and genitourinary tracts, and serosal cavities and retroperitoneally can occur. The risk of bleeding is greatly increased by misguided treatment with heparin. Fatal haemothorax, massive haematemesis and melaena, haematuria, and intrauterine fetal death are rare tragedies. Acute renal failure has often been described, especially in children. Increased capillary permeability is reflected by the local and sometimes generalised



Extra references are on bmj.com

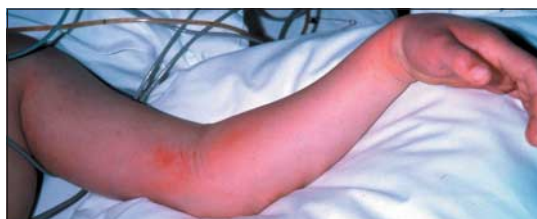

Fig 2 Extensive swelling of the bitten limb in a child, 24 hours after the bite, showing bruising

oedema, as well as the more focal angio-oedema that can lead to fatal occlusion of the upper airway, pulmonary oedema,^{w15} and cerebral oedema. Coma and seizures have been attributed to hypotension, cerebral oedema, hyponatraemia, hypoalbuminaemia, or hypoxaemia secondary to respiratory distress.⁷ Cardiac arrest, acute gastric dilatation, paralytic ileus, and acute pancreatitis^{w16} are other reported complications.

Investigations

Neutrophil leucocytosis is common. Initial haemoglobin concentration and later anaemia result from extravasation into the bitten limb and perhaps haemolysis. Concentrations of serum creatine kinase, transaminases, urea, and creatinine may be raised, and bicarbonate may be reduced. Thrombocytopenia^{w12} and mild coagulopathy—reflected by prolonged prothrombin time (international normalised ratio), activated partial thromboplastin time, hypofibrinogenaemia, and raised fibrin degradation products or D-dimer—is sometimes detected. Consumption coagulopathy and incoagulable blood (20 minute whole blood clotting test^{w17}) are uncommon.⁸

Electrocardiographic changes include tachyarrhythmias, bradyarrhythmias, atrial fibrillation, flattening or inversion of T waves, ST elevation or depression, second degree heart block, and frank myocardial infarction.^{1 5}

Treatment

First aid

Initial management is to reassure, give paracetamol to control pain, and immobilise the whole patient (especially the bitten limb with a splint or sling) during urgent transport to hospital. Early anaphylactoid symptoms can be treated with an oral or parenteral H₁ blocker or adrenaline (epinephrine) (Epi-Pen), depending on severity. Any interference with the wound should be avoided. Tourniquets, ligatures, and compression bandages should not be used.

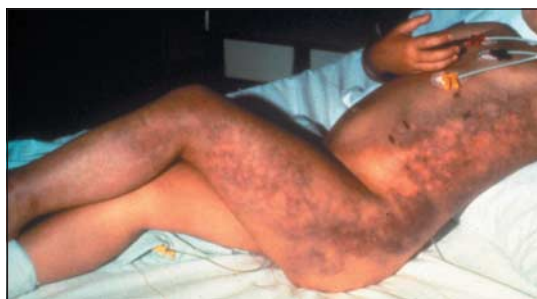

Fig 3 Generalised swelling and bruising of the whole body in an infant (courtesy of Hans Persson, Stockholm)

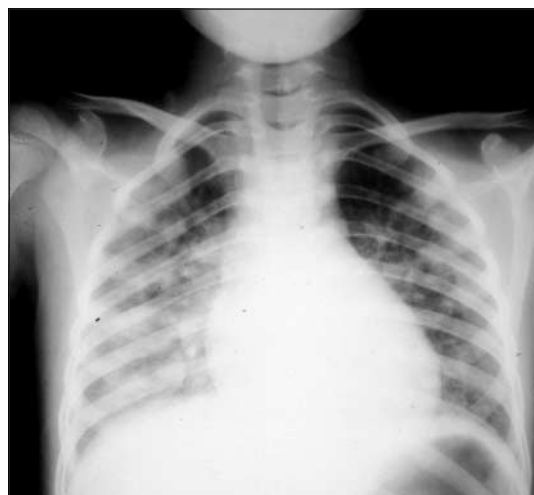


Fig 4 Chest radiograph showing interstitial pulmonary haemorrhage in a child bitten three days earlier (courtesy of R Pugh, Hull)

Hospital treatment

In hospital, rapid clinical assessment of the degree of envenoming and resuscitation may be needed, followed by careful monitoring of the blood pressure and evolution of envenoming over at least 24 hours. The most important decision is whether antivenom should be given.

Antivenom

This specific antidote prevents mortality and reduces hospital stay and morbidity,^{8–11 w18} but it is underused in the UK. Zagreb antivenom has been provided to NHS hospitals since 1969. Other effective antivenoms are Protherics ViperaTAB^{12 w19} and Sanofi-Pasteur Viperfav.^{w20 w21} Zagreb antivenom has also proved safe and effective in *V. berus* envenomed dogs.^{w22 w23} Indications for antivenom are

- Hypotension with or without signs of shock
- Other signs of systemic envenoming (see above), electrocardiographic abnormalities, peripheral neutrophil leucocytosis, elevated serum creatine kinase, or metabolic acidosis
- Local swelling that is either extensive (involving more than half the bitten limb within 48 hours of the bite) or rapidly spreading (beyond the wrist after bites on the hand or beyond the ankle after bites on the foot within about four hours of the bite).

Two ampoules of Zagreb antivenom are given (exactly the same dose for infants and children) by slow intravenous injection or infusion; 0.1% adrenaline (plus intravenous antihistamine and hydrocortisone) should be drawn up in case of early anaphylactoid antivenom reactions, which complicate about 10% of treatments with Zagreb antivenom.⁸ These reactions are not predicted by intradermal hypersensitivity tests.¹³ Their frequency may be reduced by giving prophylactic subcutaneous adrenaline (adult dose 0.25 mg of 0.1%)¹⁴ but is not affected by H₁ blockers.¹⁵ If no clinical improvement has occurred after one hour, the initial dose of two ampoules of antivenom can be repeated. Late serum sickness reactions can be treated with oral H₁ blockers or corticosteroids.

Other management

Intravenous fluids or blood transfusion may be needed to correct hypovolaemia and anaemia from massive

Case history: near fatal adder bite in 1998

While walking with her husband near the Blackwater Estuary in Essex, a 39 year old woman stepped off the path on to a grass verge and immediately felt a very painful sharp stinging sensation on her left foot (she was wearing open sandals). Her mouth felt dry, she became dizzy and nauseated, and she had to lie down. Her throat was closing up, she could not swallow or breathe, and within five minutes she had lost consciousness. Her husband rushed away to call an ambulance, but when he returned he found two strangers doing cardiopulmonary resuscitation on her. She looked very pale and was vomiting and doubly incontinent. She had two cardiorespiratory arrests before the ambulance arrived 30 minutes later. She was given two injections of adrenaline intramuscularly and assisted ventilation with oxygen by mask. When she arrived at hospital 50 minutes after the "sting," her Glasgow coma score was 11/15, her blood pressure was 86/60 mm Hg, and her pulse was 138 beats/minute. On her left foot were two fang punctures 6 mm apart, with swelling and bruising up to mid-calf. Adder bite was diagnosed. Her leucocyte count was $15.3 \times 10^9/l$ (neutrophilia), international normalised ratio 1.65, prothrombin time 19.1 seconds (control 14.0), and platelets $150 \times 10^9/l$. Electrocardiograms showed widespread ST segment depression suggesting global ischaemia. These abnormalities resolved completely in a few hours, and she made a slow recovery after treatment with antivenom. She had never been bitten before.

extravasation into the tissues. The bitten limb should be nursed in the most comfortable position, but excessive elevation should be avoided. Contractures (such as result in equinus deformity) from prolonged bed rest must be prevented by splinting, and rehabilitation physiotherapy should be started as early as possible.

Recovery

Children usually recover completely between less than a week and three weeks after the bite, but most adults take three weeks or longer, and a quarter take between one and nine months. During recovery, disabling aching and intermittent swelling of the bitten limb may occur.¹

Exotic snake bites

More than 75 species of exotic venomous snakes are kept legally and illegally in the UK. They include the

most popular "pet" species listed below (genera in parentheses), members of three families:

- Elapidae—cobras (*Naja*), including spitters, coral snakes (*Micrurus*, *Micruroides*), kraits (*Bungarus*), mambas (*Dendroaspis*)
- Viperidae—rattlesnakes (*Crotalus*, *Sistrurus*); copperhead moccasins and cantils (*Agkistrodon*); bush vipers (*Atheris*); puff adders, Gaboon vipers, rhinoceros horned vipers (*Bitis*); desert horned vipers (*Cerastes*); green pit vipers (*Trimeresurus*)
- Colubridae—boomslangs (*Dispholidus*), Montpellier snakes (*Malpolon*), red-necked keel backs, and yamaka-gashis (*Rhabdophis*).

People are bitten by exotic snakes while handling or feeding them, cleaning out their cages, milking them of their venoms, or attempting to steal them. Some pet keepers are bitten while handling their snakes in a drunken, drugged, tired, or emotional state, late at night.

Clinical features^{16–18 w24}

Only about 50% of bites by exotic venomous snakes inject sufficient venom to cause clinical envenoming.

Local envenoming—Swelling, bleeding, bruising, lymphangitis, blistering, necrosis, secondary infection, and painful regional lymph node enlargement are typical of bites by many species of Viperidae. Cobras can cause local swelling, blistering, and necrosis; other Elapidae such as kraits, coral snakes, and Australian death adders produce negligible local envenoming.

Systemic envenoming—Bleeding diatheses (spontaneous systemic bleeding from the gums, nose, or gastrointestinal and genitourinary tracts, incoagulable blood, platelet abnormalities) are common after bites by Viperidae, Colubridae, and Australasian Elapidae. Microangiopathic and intravascular haemolysis (some Elapidae, Colubridae, and Viperidae),⁴ generalised rhabdomyolysis (sea snakes, Australasian Elapidae, and some Viperidae), and hypotension and shock (Viperidae)¹⁹ contribute to the risk of acute renal failure. Descending paralysis, starting with ptosis and external ophthalmoplegia and progressing to respiratory failure, is typical of bites by Elapidae (including sea snakes) and a few species of Viperidae. Spitting cobras and the South African rinkhals spray their venom defensively from the tips of their fangs into the eyes, causing painful chemical conjunctivitis with the risk of corneal ulceration, anterior uveitis, and secondary infection. The eyes should be irrigated immediately with generous volumes of water.

Treatment

First aid for most exotic bites is the same as for adder bites (see above), but pressure-immobilisation (fig 5)^{20 21} is recommended for bites by snakes that can cause rapidly evolving and life threatening paralysis (most elapids except African spitting cobras and some Asian cobras).

Practical problems of management include

- Finding and identifying the snake responsible. Zoos and poisons centres can often suggest an expert herpetologist.^{w25} An emailed electronic image of the animal can be life saving
- Obtaining the appropriate antivenom urgently through the national poisons centre.² Antivenoms selected to cover the venomous species known and suspected to be held in the UK are stored in London and Liverpool

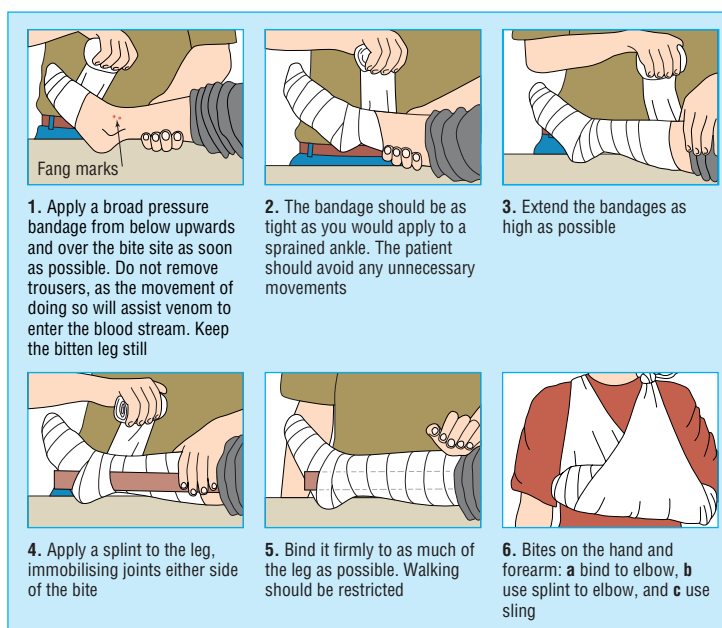


Fig 5 Pressure-immobilisation method

- Persuading the pet keeper to stay in hospital long enough to be treated.

Antivenom is indicated if there are haemostatic abnormalities (incoagulable blood or spontaneous systemic bleeding), shock, neurotoxicity, myotoxicity, nephrotoxicity, or severe local envenoming.^{22 w26 w27}

Supportive treatment

Circulating volume repletion and dopamine may be effective for hypotension and adrenaline (epinephrine) for the rare cases of venom anaphylaxis in snake handlers who have become hypersensitive to venom.

Early endotracheal intubation and assisted ventilation are needed if neurotoxicity progresses. Anticholinesterase drugs improve some cases of neurotoxic envenoming.²³

Heparin, corticosteroids, and antifibrinolytic agents should not be used. Secondary bacterial infection of the bite wound may occur with abscess formation, but prophylactic antibiotics are not justified.²⁴ Fasciotomy is very rarely indicated despite common clinical appearances suggesting intracompartmental syndrome and should not be allowed without full restoration of normal haemostasis and demonstration that intracompartmental pressure is >40 mm Hg.²⁵

I am grateful to R David, G Theakston, Ian M Stell, Alexander Campbell, and Glyn N Volans for useful information.

Competing interests: None declared.

- 1 Reid HA. Adder bites in Britain. *BMJ* 1976;2:153-6.
- 2 Gillissen A, Theakston RD, Barth J, May B, Krieg M, Warrell DA. Neurotoxicity, haemostatic disturbances and haemolytic anaemia after a bite by a Tunisian saw-scaled or carpet viper (*Echis "pyramidum"-complex*): failure of antivenom treatment. *Toxicon* 1994;32:937.
- 3 Schneemann M, Cathomas R, Laidlow ST, El Nahas AM, Theakston RD, Warrell DA. Life-threatening envenoming by the Saharan horned viper (*Cerastes cerastes*) causing micro-angiopathic haemolysis, coagulopathy and acute renal failure: clinical cases and review. *Q J Med* 2004;97:717-27.
- 4 Reid HA. Bites by foreign venomous snakes in Britain. *BMJ* 1978;1:1598-600.
- 5 Persson H, Irestedt B. A study of 136 cases of adder bite treated in Swedish hospitals during one year. *Acta Med Scand* 1981;210:433-9.
- 6 Gerrard M, Pugh R. An adder bite with unusual consequences. *Practitioner* 1982;226:527-8.
- 7 Cederholm I, Lennmarken C. *Vipera berus* bites in children—experience of early antivenom treatment. *Acta Paediatr Scand* 1987;76:682-4.

Additional educational resources

The clinical management of snake bites in the South East Asian region—w3.whosea.org/bct/snake

Clinical toxinology resources—www.toxinology.com

American Zoo and Aquarium Association. Bites by exotic Elapidae—accessible via globalcrisis.info/latestantivenom.htm under "Recommendations, procedures and discussion"

Antivenoms

Munich AntiVenomIndex (MAVIN)—toxinfo.org/antivenoms/

CSL Antivenom Handbook—www.toxinology.com/generic_static_files/cslavh_antivenom.html

Antivenom index—www.aza.org/AI/ (for poisons centers' prescribers)

globalcrisis.info/latestantivenom.htm

World Health Organization—www.who.int/bloodproducts/animal_sera/en/

Venomous snake taxonomy updates—sbsweb.bangor.ac.uk/%7Ebss166/update.htm

Summary points

Life threatening envenoming by adders is uncommon but can happen, especially in children—do not underestimate the humble adder

Envenoming can evolve over many hours, so patients must be carefully observed in hospital for at least 24 hours after being bitten

Antivenom is effective and acceptably safe in hospitals; it is underused in the United Kingdom

Antivenom should be considered in patients with systemic envenoming, especially children, and in those who have extensive or rapidly progressing local swelling

Thousands of exotic snakes of more than 75 different species are kept legally and illegally in the UK; identification of the species, obtaining appropriate antivenom, and completing treatment are some of the clinical challenges

- 8 Karlson-Stüber C, Persson H. Antivenom treatment in *Vipera berus* envenoming—report of 30 cases. *J Intern Med* 1994;235:57-61.
- 9 Persson H. Envenoming by European vipers: antivenom treatment—influence on morbidity. *Przegląd Lekarski* 2001;58:223-5.
- 10 Stahel E, Wellauer R, Freyvogel TA. Vergiftungen durch einheimische Vipern (*Vipera berus* und *Vipera aspis*): Einer retrospektive Studie an 113 Patienten. *Schweiz Med Wochenschr* 1985;115:890-6.
- 11 Theakston RDG, Reid HA. Effectiveness of Zagreb antivenom against envenoming by the adder, *Vipera berus*. *Lancet* 1976;ii:121-5.
- 12 Karlson-Stüber C, Persson H, Heath A, Smith D, al-Abdulla IH, Sjöström L. First clinical experiences with specific sheep Fab fragments in snake bite: report of a multicentre study of *Vipera berus* envenoming. *J Intern Med* 1997;241:53-8.
- 13 Malasit P, Warrell DA, Chanthavanich P, Viravan C, Mongkolsapaya J, Singthong B, et al. Prediction, prevention and mechanism of early (anaphylactic) antivenom reactions in victims of snake bites. *BMJ* 1986;292:17-20.
- 14 Premawardhana AP, de Silva CE, Fonseka MM, Gunatilake SB, de Silva HJ. Low dose subcutaneous adrenaline to prevent acute adverse reactions to antivenom serum in people bitten by snakes: randomised, placebo-controlled trial. *BMJ* 1999;318:1041-3.
- 15 Fan HW, Marcopito LF, Cardoso JL, Franca FO, Malaque CM, Ferrari RA, et al. Sequential randomised and double blind trial of promethazine prophylaxis against early anaphylactic reactions to antivenom for Bothrops snake bites. *BMJ* 1999;318:1451-2.
- 16 Meier J, White J, eds. *Handbook of clinical toxicology of animal venoms and poisons*. Boca Raton: CRC Press, 1995.
- 17 Warrell DA, ed. WHO/SEARO guidelines for the clinical management of snake bites in the South East Asian region. *Southeast Asian J Trop Med Public Health* 1999;30(suppl 1):1-85.
- 18 Warrell DA. Snake bites in Central and South America: epidemiology, clinical features and clinical management. In: Campbell JA, Lamar WW, eds. *The venomous reptiles of the western hemisphere*. Ithaca, Comstock: Cornell University Press, 2004:709-61.
- 19 McNally T, Conway GS, Jackson L, Theakston RD, Marsh NA, Warrell DA, et al. Accidental envenoming by a Gaboon viper (*Bitis gabonica*): the haemostatic disturbances observed and investigation of in vitro haemostatic properties of whole venom. *Trans R Soc Trop Med Hyg* 1993;87:66-70.
- 20 Howarth DM, Southee AE, Whyte IM. Lymphatic flow rates and first-aid in simulated peripheral snake or spider envenomation. *Med J Australia* 1994;161:695-700.
- 21 Sutherland SK, Coulter AR, Harris RD. Rationalisation of first-aid measures for elapid snake bite. *Lancet* 1979;ii:183-6.
- 22 Smalligan R, Cole J, Brito N, Laing GD, Mertz BL, Manock S, et al. Crotaline snake bite in the Ecuadorian Amazon: randomised double blind comparative trial of three South American polyspecific antivenoms. *BMJ* 2004;329:1129.
- 23 Watt G, Theakston RD, Hayes CG, Yambao ML, Sangalang R, Ranoa CP, et al. Positive response to edrophonium in patients with neurotoxic envenoming by cobras (*Naja naja philippinensis*): a placebo-controlled study. *N Engl J Med* 1986;315:1444-8.
- 24 Jorge MT, Malaque C, Ribeiro LA, Fan HW, Cardoso JL, Nishioka SA, et al. Failure of chloramphenicol prophylaxis to reduce the frequency of abscess formation as a complication of envenoming by Bothrops snakes in Brazil: a double-blind randomised controlled trial. *Trans R Soc Trop Med Hyg* 2004;98:529-34.
- 25 Matsen FA. *Compartmental syndromes*. New York: Grune & Stratton, 1980:162.

(Accepted 13 October 2005)